



PATIENT

Lacey Mohr

SPECIES

Feline

BREED

DSH

SEX

Spayed Female

AGE

9.5

WEIGHT

11.9

INTERPRETED BY

Eric Lindquist, DMV
DABVP, Cert. IVUSS

IMAGING PERFORMED BY

Melissa Pascucci

HOSPITAL NAME

American AH

REFERRING VET

Dr. Vogel

INVOICE

21978

DATE

4/14/23

PRESENTING CLINICAL SIGNS

History: 2 days hx of vomiting and no appetite. received Cerenia yesterday and vomited 3x overnight. Lethargic.

Abnormal PE/Chem/CBC/UA Results: unremarkable bw and fecal on 3/22/23

ULTRASONOGRAPHIC EXAMINATION OF THE ABDOMEN

Urinary System

The **urinary bladder**, trigone, and pelvic urethra presented normal thicknesses and normal tone. The ureters were not visible which is normal. No uroliths or sediment were visualized and anechoic urine was present. No evidence of inflammatory or neoplastic changes were noted. Ureteral papillae were normal. The pelvic urethra was imaged 1.0 cm beyond the cystourethral junction.

The **kidneys** revealed normal size and structure, corticomedullary definition and ratio for this age. The cortices presented largely uniform texture with normal echogenic relationship to liver and spleen. Medullary structure differed distinctly from the cortex and no evidence of pelvic dilation was present. The capsules were acceptably uniform without significant irregularities. The left kidney measured 3.5 cm. The right kidney measured 3.5 cm.

Adrenal Glands

The regions of the **adrenal glands** revealed no evident pathology.

Spleen

The **spleen** presented a smooth homogeneous parenchyma hyperechoic to liver and renal cortical parenchyma. The capsule was smooth without noticeable expansion or deviation from within the spleen or adjacent pathology. The splenic vasculature demonstrated normal volume without signs of congestion or thrombosis. No sonographic evidence of acute or chronic inflammatory, neoplastic, or infarctual changes were noted.

Liver

The **liver** itself was unremarkable. The gallbladder was bifid, yet structurally unremarkable- this is a normal variant.

Gastrointestinal

The **stomach** revealed a minor amount of excessive gas and fluid filled lumen yet no overt evidence of foreign body. The small intestine and colon were unremarkable.

Pancreas

The base and limbs of the **pancreas** were observed to be largely isoechoic to surrounding omental fat. Pancreatic duct and capsular contour were acceptably normal and parenchyma respected normal curvilinear patterns. No overt evidence of active inflammatory or neoplastic disease was noted.

ULTRASONOGRAPHIC FINDINGS

- Gastritis pattern – no overt evidence of foreign body
- Bifid gallbladder- normal variant



PATIENT

Lacey Mohr

INTERPRETATION OF THE FINDINGS & FURTHER RECOMMENDATIONS

Supportive care should prove effective.

SPECIES

Feline

BREED

DSH

SEX

Spayed Female

AGE

9.5

WEIGHT

11.9

INTERPRETED BY

Eric Lindquist, DMV
DABVP, Cert. IVUSS

IMAGING PERFORMED BY

Melissa Pascucci

HOSPITAL NAME

American AH

REFERRING VET

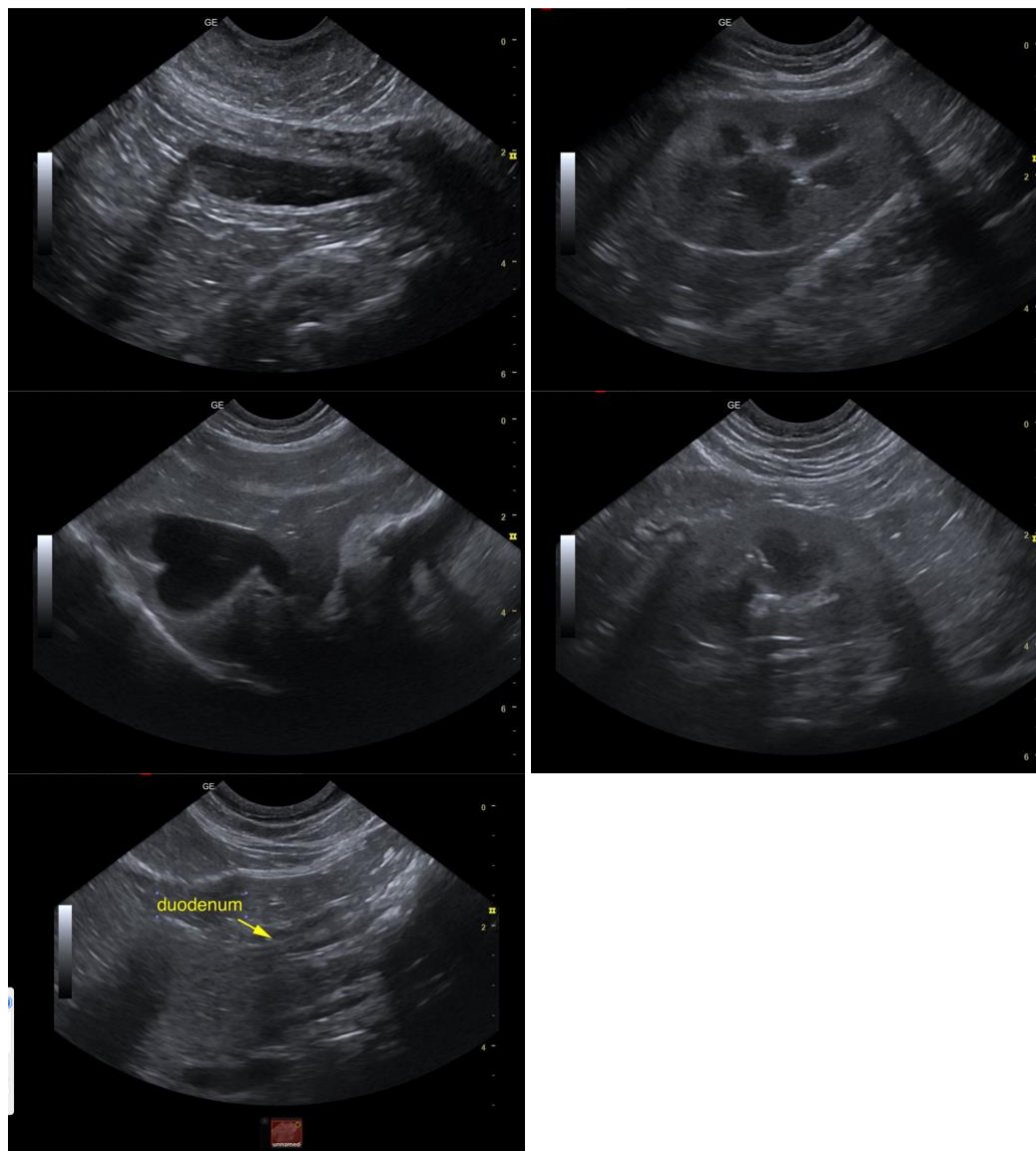
Dr. Vogel

INVOICE

21978

DATE

4/14/23



The information and recommendations provided are based on the images presented by the referring veterinarian. No evaluation can be communicated regarding pathology that was not visible in the image/video clips provided.

Thank you for this referral. If the clinical or image interpretation does not parallel your findings or if I can be of any further assistance please contact me.

Eric Lindquist, DMV, DABVP, Cert. IVUSS, CEO of SonoPath.com



PATIENT

info@SonoPath.com

Lacey Mohr

SPECIES

Feline

BREED

DSH

SEX

Spayed Female

AGE

9.5

WEIGHT

11.9

INTERPRETED BY

Eric Lindquist, DMV
DABVP, Cert. IVUSS

**IMAGING
PERFORMED BY**

Melissa Pascucci

HOSPITAL NAME

American AH

REFERRING VET

Dr. Vogel

INVOICE

21978

DATE

4/14/23