



PATIENT

Kona Kimble

SPECIES

Canine

BREED

Poodle X

SEX

Spayed Female

AGE

4 Years

WEIGHT

49.5 Pounds

INTERPRETED BY

Eric Lindquist, DMV

DABVP, Cert. IVUSS

IMAGING PERFORMED BY

Val Shumskaya

HOSPITAL NAME

Rockaway AH

REFERRING VET

Dr. Maniar

INVOICE

46691

DATE

4/14/23

PRESENTING CLINICAL SIGNS

Acute onset vomiting, anorexia, concern for FB vs Gastritis vs other.

ULTRASONOGRAPHIC EXAMINATION OF THE ABDOMEN

Urinary System

The **urinary bladder**, trigone, and pelvic urethra presented normal thicknesses and normal tone. The ureters were not visible which is normal. No uroliths or sediment were visualized and anechoic urine was present. No evidence of inflammatory or neoplastic changes were noted. Ureteral papillae were normal. The pelvic urethra was imaged 2.0 cm beyond the cystourethral junction.

The **kidneys** revealed normal size and structure, corticomedullary definition and ratio for this age. The cortices presented largely uniform texture with normal echogenic relationship to liver and spleen. Medullary structure differed distinctly from the cortex and no evidence of pelvic dilation was present. The capsules were acceptably uniform without significant irregularities. The right kidney measured 4.43 cm.

Adrenal Glands

Both **adrenal glands** were visualized and recognized as having normal shape, size, position and echogenicity for this breed. The phrenic vasculature, glandular echogenicity and detail were unremarkable. Capsule, cortex, and medullary definition were normal for this age patient. The left adrenal gland measured 1.2 cm x 0.39 cm at the caudal pole and 0.25 cm at the cranial pole. The right adrenal gland measured 2.42 cm x 0.92 cm at the cranial pole and 0.34 cm at the caudal pole.

Spleen

The **spleen** presented a smooth homogeneous parenchyma hyperechoic to liver and renal cortical parenchyma. The capsule was smooth without noticeable expansion or deviation from within the spleen or adjacent pathology. The splenic vasculature demonstrated normal volume without signs of congestion or thrombosis. No sonographic evidence of acute or chronic inflammatory, neoplastic, or infarctual changes were noted.

Liver

The **liver** images submitted revealed subjectively normal liver size, contour, and structure. Parenchymal echogenicity was naturally coarse and hypoechoic to the spleen. Vascular and biliary tracts were of normal volume with no evidence of congestion. The gallbladder presented acceptably thin walls with primarily anechoic content. The cystic and common bile ducts were normal. No pathological hepatic lymphadenopathy was evident. No overt structural evidence of inflammatory, infiltrative or regenerative pathology was evident.

Gastrointestinal

The **stomach** was filled with progressively shadowing ingesta, consistent with post-prandial presentation, or possibility of soft foreign matter. Transit of chyme in the small intestine appeared to be normal. The descending colon was empty.

Pancreas

The base and limbs of the **pancreas** were observed to be largely isoechoic to surrounding omental fat. Pancreatic duct and capsular contour were acceptably normal and parenchyma respected normal curvilinear patterns. No overt evidence of active inflammatory or neoplastic disease was noted.



PATIENT

Kona Kimble

SPECIES

Canine

BREED

Poodle X

SEX

Spayed Female

AGE

4 Years

WEIGHT

49.5 Pounds

INTERPRETED BY

Eric Lindquist, DMV
DABVP, Cert. IVUSS

IMAGING PERFORMED BY

Val Shumskaya

HOSPITAL NAME

Rockaway AH

REFERRING VET

Dr. Maniar

INVOICE

46691

DATE

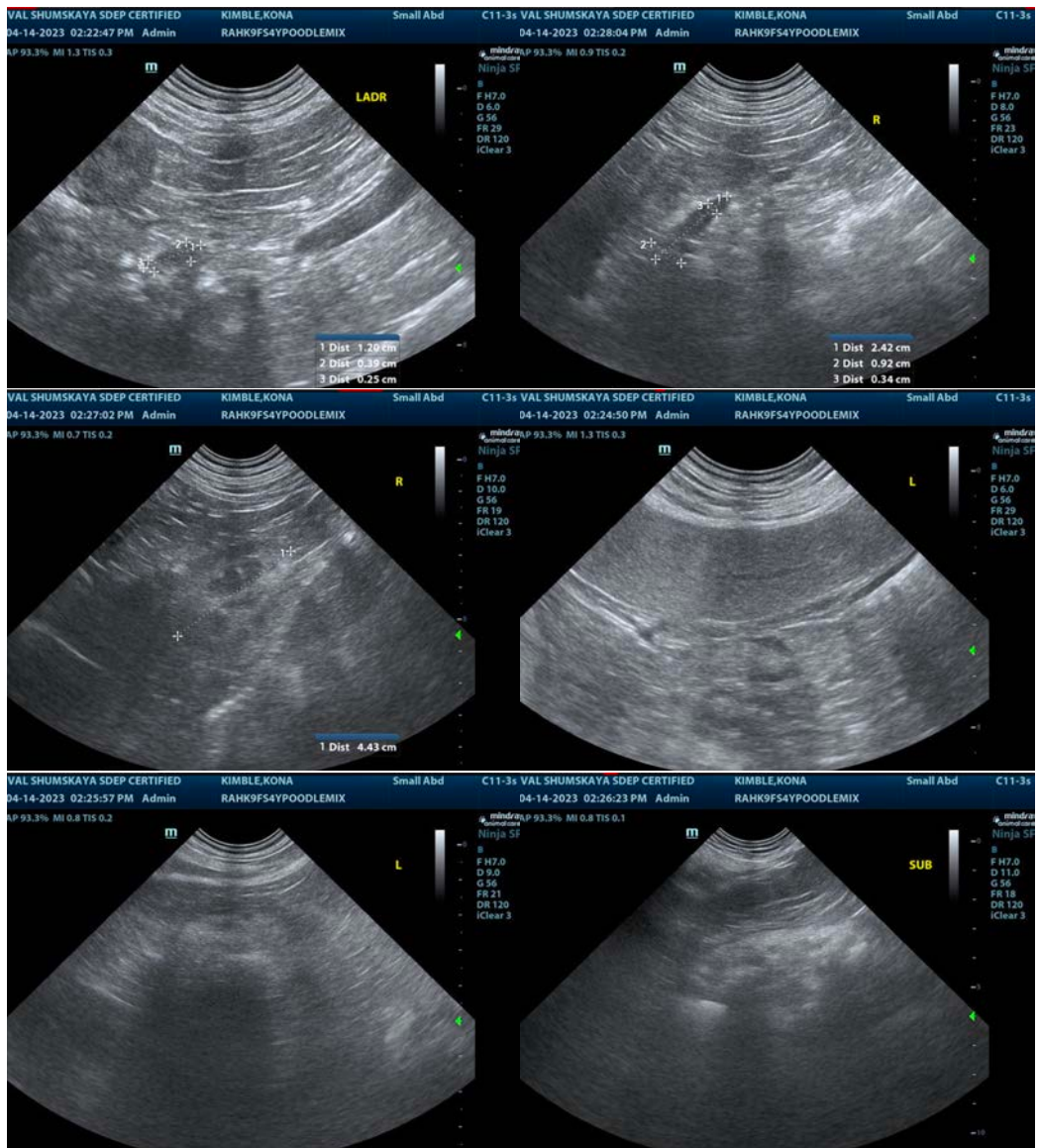
4/14/23

ULTRASONOGRAPHIC FINDINGS

- Post-prandial presentation

INTERPRETATION OF THE FINDINGS & FURTHER RECOMMENDATIONS

No evidence of significant disease. Supportive care should prove effective. If patient is persistently clinical over the next 24-48 hours, then recheck sonogram indicated. Dietary indiscretion, food intolerance, structurally insignificant inflammatory bowel or occult parasitism and occult Addison's are all potentials. Screening for Addison's indicated.





PATIENT

Kona Kimble

SPECIES

Canine

BREED

Poodle X

SEX

Spayed Female

AGE

4 Years

WEIGHT

49.5 Pounds

INTERPRETED BY

Eric Lindquist, DMV
DABVP, Cert. IVUSS

**IMAGING
PERFORMED BY**

Val Shumskaya

HOSPITAL NAME

Rockaway AH

REFERRING VET

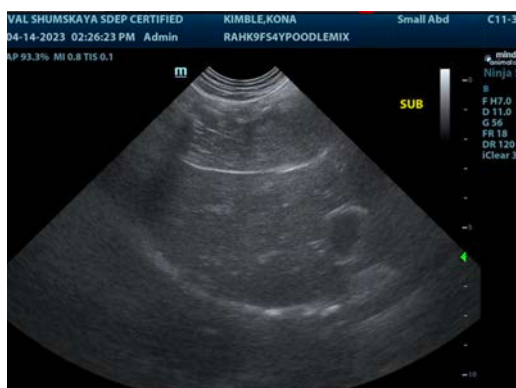Dr. Maniar

INVOICE

46691

DATE

4/14/23



The information and recommendations provided are based on the images presented by the referring veterinarian/sonographer. No evaluation can be communicated regarding pathology that was not visible in the image/video clips provided.

Thank you for this referral. If the clinical or image interpretation does not parallel your findings or if I can be of any further assistance please contact me.

Eric Lindquist, DMV, DABVP, Cert. IVUSS, CEO of SonoPath.com

info@SonoPath.com