



PATIENT PRESENTING CLINICAL SIGNS

Ranger Lee Grade 3/6 murmur. Assess for origin.

SPECIES ULTRASONOGRAPHIC EXAMINATION OF THE HEART

Canine

BREED

Australian Shepherd X

SEX

Neutered Male

AGE

10 Years

WEIGHT

19 kg

CANINE CARDIAC PARAMETERS	MR VMAX (m/s)	TR VMAX (m/s)	LA/AO (Boon method)	LA/AO (Heart Base; Swe)	FS (%)	EF (%)	EPSS (cm)
NORMAL PARAMETER	4.5-5.5	<2.7	1.3	<1.6	28-40	40-100	<0.6
PATIENT		3.16	1.5	2.2	41	71	0.1
CANINE CARDIAC PARAMETERS	HR (BPM)	AV VMAX (m/s)	PV MAX (m/s)	BODY WEIGHT (kg)	LA 2D short axis Base view (cm)	LVIDd Avg; 2D and m-mode short axis (cm)	LVIDs Avg; 2D and m-mode short axis (cm)
NORMAL PARAMETER	50-100	0.7-1.7	0.7-1.6	BELOW	BELOW	BELOW	BELOW
PATIENT		1.36			4.6	5.07	

Cardiac Presentation

The echocardiogram for this patient presented excessive **left atrial size** expressed both in the LA/AO and LA max measurements Chamber volumes and echogenicity were normal. The cranial and caudal **mitral** valve leaflets presented vegetative thickening consistent with endocardiosis. Doppler indicated measurable insufficiency. Prolapse of the anterior mitral valve leaflet noted. The **left ventricle** presented thicknesses with linear contour and was not dilated nor restricted. The **myocardium** presented normal echogenicity without subjective evidence of significant fibrotic or ischemic disease. **Contractility** of the ventricular walls was adequate and in normal range for this patient evidenced by the fractional shortening measurement and subjective evaluation of the different regions of the myocardium. The **left ventricular outflow** tract demonstrated normal laminar flow and subjective structural integrity. The **right atrium** and auricle revealed normal size, structure and content. No evidence of masses was noted or chamber overload. **Tricuspid** valvular assessment demonstrated adequate linear morphology. The **right ventricle** was of normal size (1/3 diameter of LV), chordae structure, myocardial echogenicity and thickness. **Pulmonic** tract assessment revealed normal valve structure, laminar flow, and diameter (approx. 1:1 pa/ao ratio). No visible **pericardial** or free pleura fluid was noted. No echographically detectable evidence of infiltrative disease was visible. The cranial **mediastinum and pericardial regions** were free of masses in the visible window.

ULTRASONOGRAPHIC FINDINGS

- Mitral insufficiency
- Stage B2 valvular disease
- Mild left atrial enlargement

INTERPRETATION OF THE FINDINGS & FURTHER RECOMMENDATIONS

Recommend initiating Pimobendan at 0.3 mg/kg BID.

INTERPRETED BY

Eric Lindquist, DMV
DABVP, Cert. IVUSS

IMAGING PERFORMED BY

Dave Stasiuk RDMS

HOSPITAL NAME

Resolution Vet
Ultrasound LTD

REFERRING VET

Dr. K.D Marahar

INVOICE

36913

DATE

4/14/22



PATIENT

Ranger Lee

SPECIES

Canine

BREED

Australian Shepherd X

SEX

Neutered Male

AGE

10 Years

WEIGHT

19 kg

INTERPRETED BY

Eric Lindquist, DMV

DABVP, Cert. IVUSS

IMAGING PERFORMED BY

Dave Stasiuk RDMS

HOSPITAL NAME

Resolution Vet
Ultrasound LTD

REFERRING VET

Dr. K.D Marahar

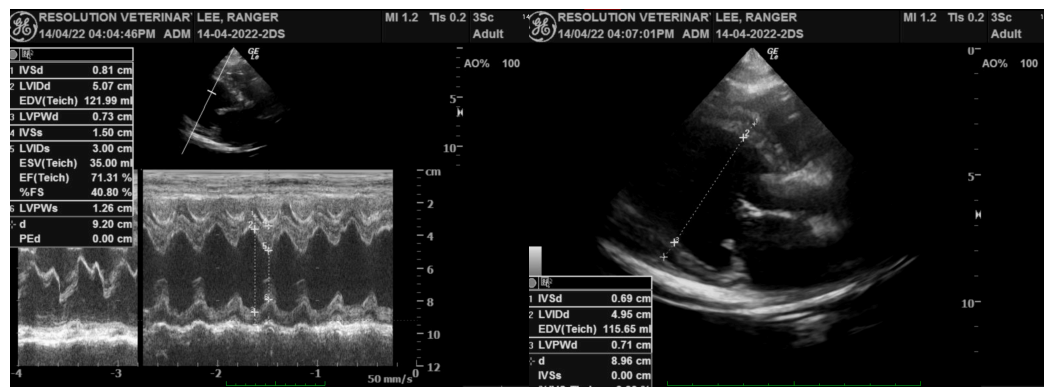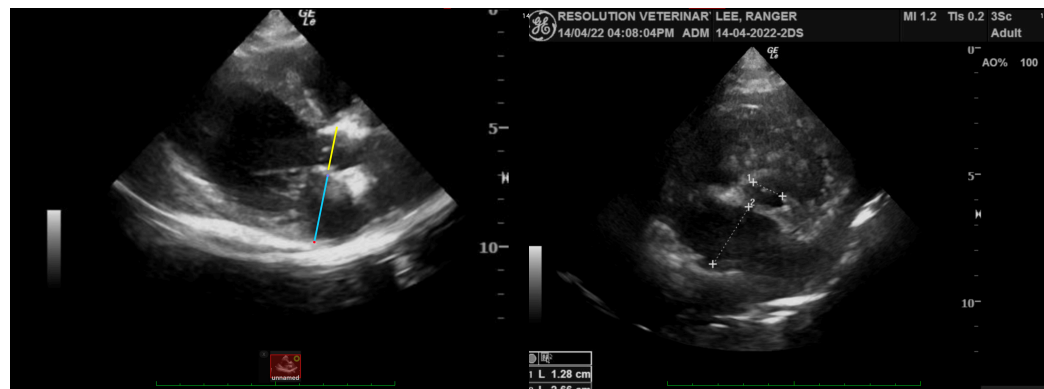
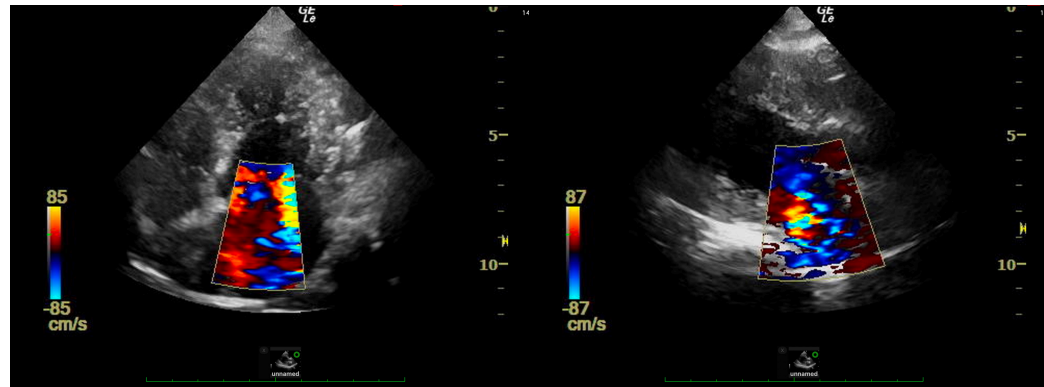
INVOICE

36913

DATE

4/14/22

The heart has some volume overload and is working to compensate for the valvular insufficiency. Target respiratory rate is < 20 resp/minute after therapy. After initiating therapy, I recommend recheck on the clinical exam, BUN, Creatinine, USG, Chest radiographs & Blood pressure in 5-7 days. Recheck echo in 1 month. Earlier if clinical decompensation is occurring. I do not recommend anesthesia at this time until stabilization has occurred on the recommended medications. Repeat preanesthetic echo is ideal if anesthesia is eventually necessary. There is moderate anesthetic risk for this patient. I recommend cardiac treatment prior to sedation unless only light opioids are utilized which would have minimal effect on heart function.





PATIENT

Ranger Lee

SPECIES

Canine

BREED

Australian Shepherd X

SEX

Neutered Male

AGE

10 Years

WEIGHT

19 kg

INTERPRETED BY

Eric Lindquist, DMV

DABVP, Cert. IVUSS

IMAGING PERFORMED BY

Dave Stasiuk RDMS

HOSPITAL NAME

Resolution Vet
Ultrasound LTD

REFERRING VET

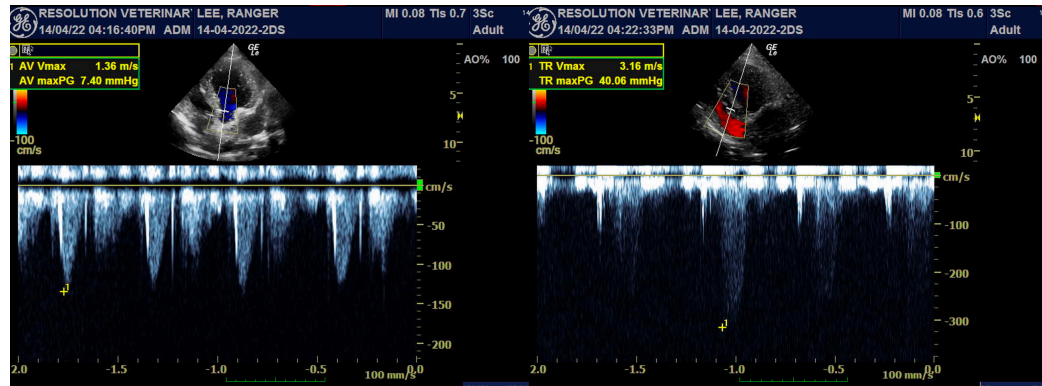
Dr. K.D Marahar

INVOICE

36913

DATE

4/14/22



The information and recommendations provided are based on the images presented by the referring veterinarian/sonographer. No evaluation can be communicated regarding pathology that was not visible in the image/video clips provided.

Thank you for this referral. If the clinical or image interpretation does not parallel your findings or if I can be of any further assistance please contact me.

Eric Lindquist, DMV, DABVP, Cert. IVUSS, CEO of SonoPath.com

info@SonoPath.com