

**DATE**

4/14/22

PRESENTING CLINICAL SIGNS

10/13/21- PE for PU/PD but straining to urinate with increased time to completion. See U/A results below with patient started on Clavamox. See meds below. 10/28/21- recheck urine, see results below, with rec for imaging and BRAF testing. 4/9/22- PE for possible UTI, see U/A results below. Rec imaging.

PATIENT

Lexi Philipp

Current Medications: 10/13/21- Clavamox-125mg- 1 BID x 7 days.

4/9/22- Clavamox-125mg- 1 BID x 14 days.

Lab Results: 10/13/21- U/A= UrSpGr-1.026, pH=6.5, prot=3+, leuk=2+, Cytology= 3+cocci, 1+WBC's and scattered epi cells. 10/28/21- U/A=UrSpGr-1.025, pH=6, Cytology=2+ epi cells. 4/9/22-U/A=UrSpGr-1.024, pH=7, prot=3+, Blood=3+, Leuk=1+, Cytology=4+cocci, 2+ epi cells with odd appearance.

SPECIES

Canine

Date of Previous IntraPet Ultrasound: No previous.

Sedation: Not required to complete full diagnostic ultrasound.

Stat Report: Not requested.

BREED

Yorkie

Imaging Performed By: Rachel Brillhart, RDMS.

ULTRASONOGRAPHIC EXAMINATION OF THE ABDOMEN**SEX**

Spayed Female

Urinary System

The **urinary bladder** revealed mineralized 2.0 x 3.0 cm hypoechoic mass that occupied the cystourethral junction. The bladder mass invaded the left ureter to a width of 1.05 cm as well as the pelvic urethra. The bladder mass is highly vascular.

AGE

1/11/11

The **kidneys** revealed largely normal size and structure, corticomedullary definition and ratio (cortex 1/3 of medulla) were essentially maintained with some age-related loss of curvilinear patterns regarding the capsule and C/M junction. The cortices presented largely uniform texture with some increased echogenicity expected for this age patient. Medullary structure differed distinctly from that of the cortex. The right kidney revealed slight pyelectasia and measured 0.18 cm. The right kidney measured 5.28 cm. The left kidney revealed pyelectasia that measured 0.8 cm. The left kidney measured 4.7 cm.

WEIGHT

20 lbs

INTERPRETED BYEric Lindquist, DMV
DABVP, Cert. IVUSS**Adrenal Glands**

Both **adrenal glands** were visualized and recognized as having normal shape, size, position and echogenicity for this breed. The phrenic vasculature, glandular echogenicity and detail were unremarkable. Capsule, cortex, and medullary definition were normal for this age patient. Right adrenal nodule was noted. The right adrenal gland measured 2.68 x 0.65 cm at the caudal pole and 0.81 cm at the cranial pole.

HOSPITAL NAME

Alexander AH

Spleen

The **spleen** presented a smooth homogeneous parenchyma hyperechoic to liver and renal cortical parenchyma. The capsule was smooth without noticeable expansion or deviation from within the spleen or adjacent pathology. The splenic vasculature demonstrated normal volume without signs of congestion or thrombosis. No sonographic evidence of acute or chronic inflammatory, neoplastic, or infarctual changes was noted.

REFERRING VET

Dr. Alexander

INVOICE

99317

Liver

The **liver** images submitted revealed subjectively normal liver size, contour, and structure. Parenchymal echogenicity was naturally coarse and hypoechoic to the spleen. Vascular and biliary tracts were of normal volume with no evidence of congestion. The gallbladder presented acceptably thin walls with primarily anechoic content. The cystic and common bile ducts were normal. No pathological hepatic lymphadenopathy was evident. No overt structural evidence of inflammatory, infiltrative or regenerative pathology was evident.

Gastrointestinal

Examination of the **gastrointestinal tract** revealed a stomach and intestine free of stasis, of normal wall thickness, acceptable curvilinear mural detail, and peristaltic activity. Small and large intestine demonstrated normal luminal chyme and stool consistency respectively. No obstructive or overt infiltrative disease was noted. No associated abnormal lymphatic activity was noted.

Pancreas

Diffuse hyperechoic changes were present in the area of the **pancreas**. The pancreatic remodeling was evident with multifocal to diffuse hyperechoic changes. These changes are consistent with fibrosis, amyloid, saponification of fat and may contain areas of low-grade chronic active inflammation especially if pain on imaging (+ Murphy sign) was present +/- focal subxiphoid palpation reveals pain response. No overt masses were noted.

ULTRASONOGRAPHIC FINDINGS

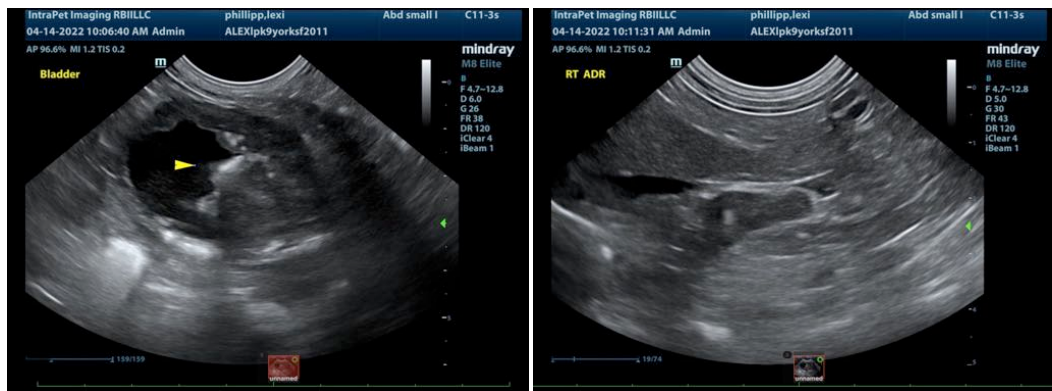
Mineralizing bladder mass invading the urethra and left ureter.

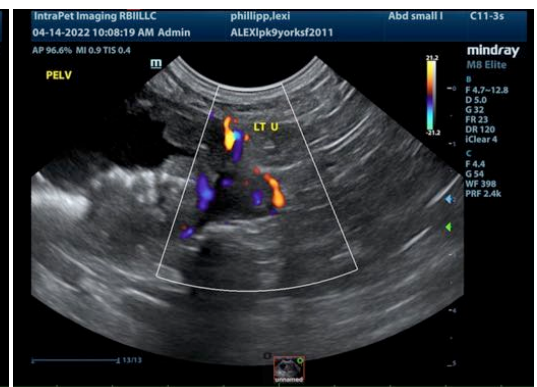
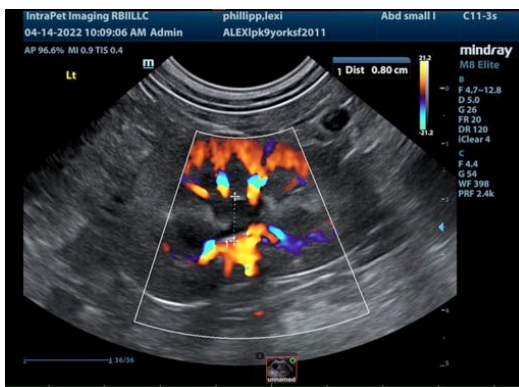
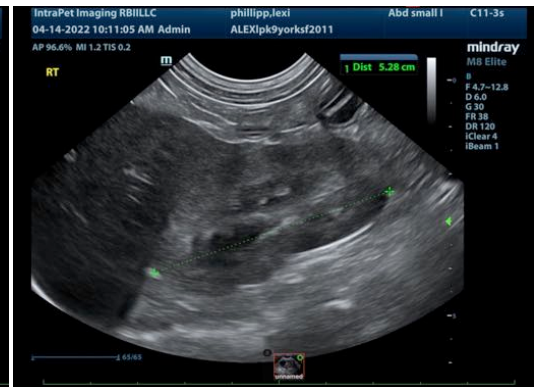
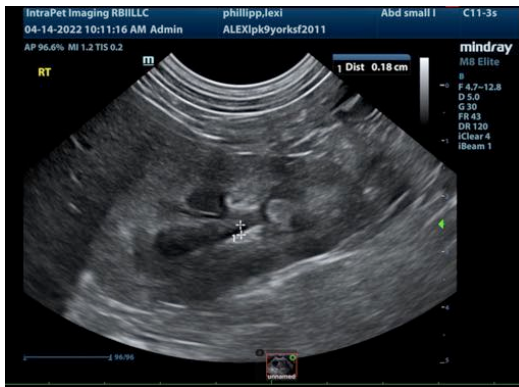
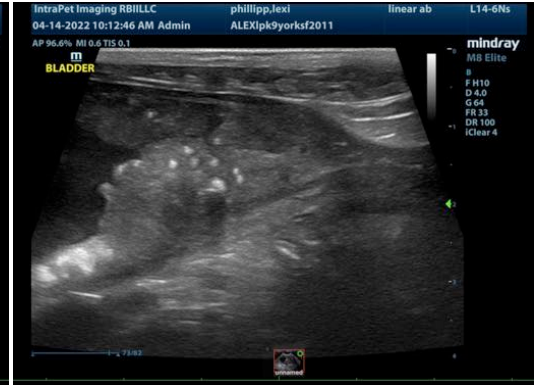
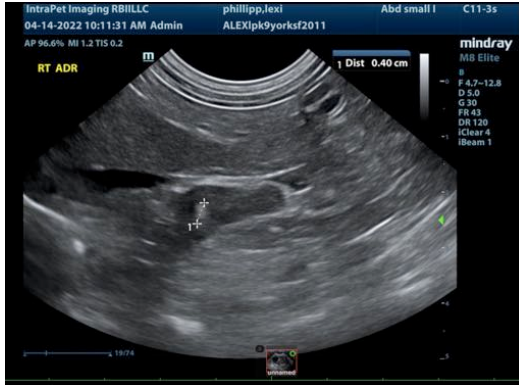Pancreatic fibrosis.

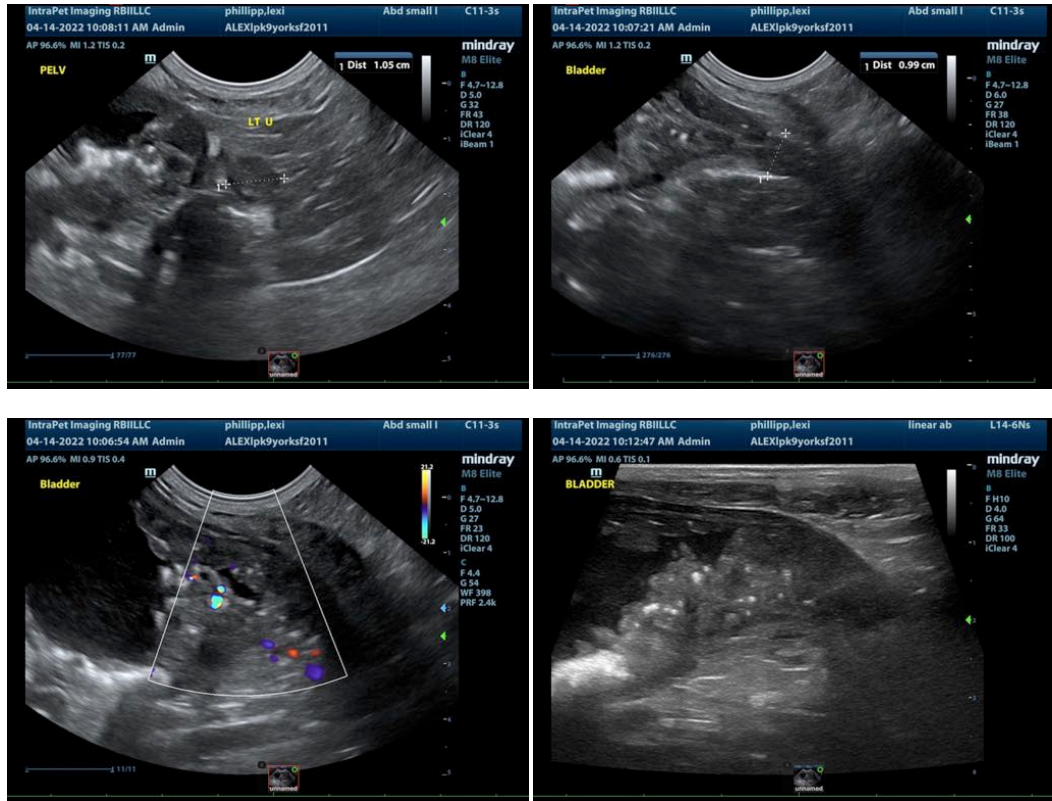
Adrenal nodule, not likely pathological.

INTERPRETATION OF THE FINDINGS & FURTHER RECOMMENDATIONS

Referral for urethral stent placement and chemotherapy is indicated.







The information and recommendations provided are based on the images presented by the referring veterinarian. No evaluation can be communicated regarding pathology that was not visible in the image/video clips provided.

Thank you for this referral. If the clinical or image interpretation does not parallel your findings or if I can be of any further assistance please contact me.

Eric Lindquist, DMV, DABVP, Cert. IVUSS, CEO of SonoPath.com
 Eric.Lindquist@SonoPath.com