



PATIENT

Poppy Ramirez

SPECIES

Feline

BREED

DSH

SEX

Spayed Female

AGE

1 Yr 9 Months

WEIGHT

6.82 pounds

INTERPRETED BY

Eric Lindquist, DMV,
DABVP(CFM), Cert.
IVUSS

IMAGING PERFORMED BY

Dr. Brianna Gaines

HOSPITAL NAME

Healthy Pets
Veterinary Care- Boca
North

REFERRING VET

Dr. Brianna Gaines

INVOICE

15049

DATE

04/13/26

PRESENTING CLINICAL SIGNS

P presented for anorexia and a distended abdomen. O notices she started wheezing today.

ULTRASONOGRAPHIC EXAMINATION OF THE ABDOMEN

Urinary System

The **urinary bladder** presented with multiple small calculi grouping which measured approximately 1.0 cm. The bladder wall was mildly thickened consistent with cystitis.

The **kidneys** revealed normal size and structure, corticomedullary definition and ratio for this age. The cortices presented largely uniform texture with normal echogenic relationship to liver and spleen. Medullary structure differed distinctly from the cortex and no evidence of pelvic dilation was present. The capsules were acceptably uniform without significant irregularities. The left kidney measured X cm in length. The right kidney measured X cm in length.

The **kidneys** were swollen with thickened cortices. The left kidney measured 4.2 cm in length. The right kidney measured 4.2 cm in length.

Adrenal Glands

Both **adrenal glands** were not visualized.

Spleen

The **spleen** presented a smooth homogeneous parenchyma hyperechoic to liver and renal cortical parenchyma. The capsule was smooth without noticeable expansion or deviation from within the spleen or adjacent pathology. The splenic vasculature demonstrated normal volume without signs of congestion or thrombosis. No sonographic evidence of acute or chronic inflammatory, neoplastic, or infarctual changes were noted.

Liver

The **liver** images submitted revealed subjectively normal liver size, contour, and structure. Parenchymal echogenicity was naturally coarse and hypoechoic to the spleen. Vascular and biliary tracts were of normal volume with no evidence of congestion. The gallbladder presented acceptably thin walls with primarily anechoic content. The cystic and common bile ducts were normal. No pathological hepatic lymphadenopathy was evident. No overt structural evidence of inflammatory, infiltrative or regenerative pathology was evident.

Gastrointestinal

The **gastrointestinal tract** was static and enveloped by heterogeneous irregular nodular omentum primarily in the pancreatic region floating in the ascites.

Pancreas

The **pancreas** presented heterogenous and irregular.

Free Abdomen

A large amount of free fluid was present within the abdomen.



PATIENT

Poppy Ramirez

SPECIES

Feline

BREED

DSH

SEX

Spayed Female

AGE

1 Yer 9 Months

WEIGHT

6.82 pounds

INTERPRETED BY

Eric Lindquist, DMV,
DABVP(CFM), Cert.
IVUSS

IMAGING PERFORMED BY

Dr. Brianna Gaines

HOSPITAL NAME

Healthy Pets
Veterinary Care- Boca
North

REFERRING VET

Dr. Brianna Gaines

INVOICE

15049

DATE

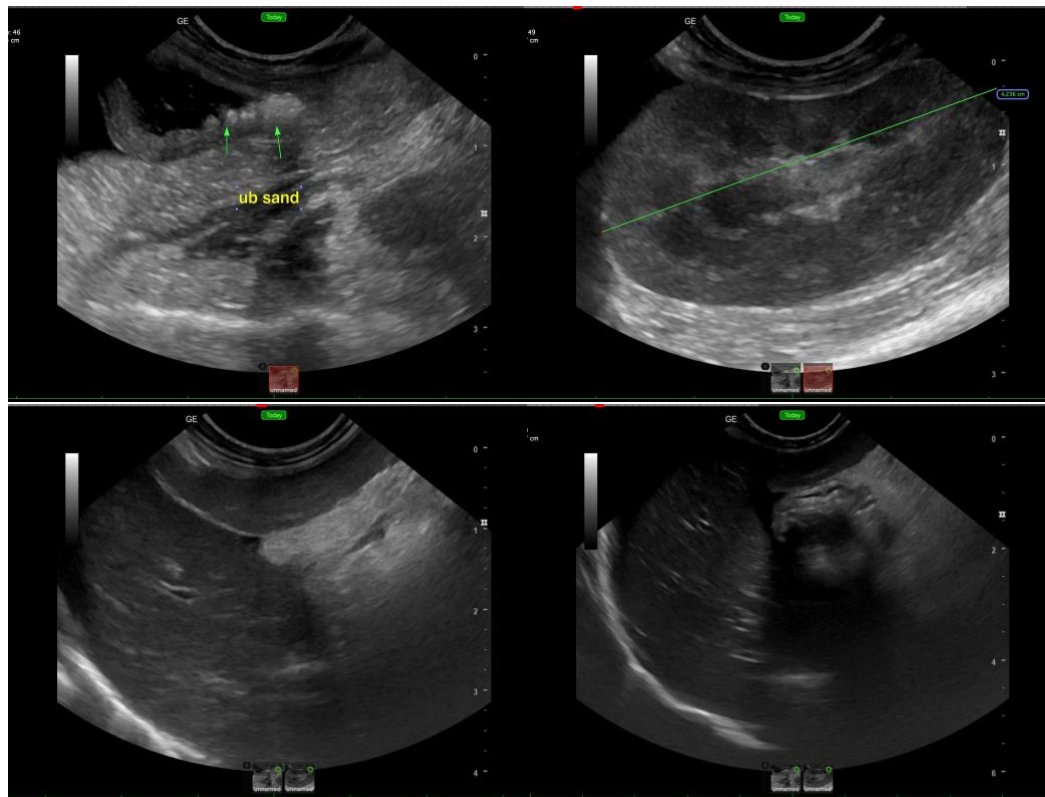
04/13/26

ULTRASONOGRAPHIC FINDINGS

- Ascites with nodular omental changes.
- Concurrent bladder, sand and cystitis pattern.
- Swollen left kidney.

INTERPRETATION OF THE FINDINGS & FURTHER RECOMMENDATIONS

Concern for FIP, carcinomatosis, lymphomatosis or similar. Abdominocentesis and cytospin with immediate slide preparation recommended with FIP titers upon the fluid would be ideal.





PATIENT

Poppy Ramirez

SPECIES

Feline

BREED

DSH

SEX

Spayed Female

AGE

1 Yer 9 Months

WEIGHT

6.82 pounds

INTERPRETED BY

Eric Lindquist, DMV,
DABVP(CFM), Cert.
IVUSS

IMAGING PERFORMED BY

Dr. Brianna Gaines

HOSPITAL NAME

Healthy Pets
Veterinary Care- Boca
North

REFERRING VET

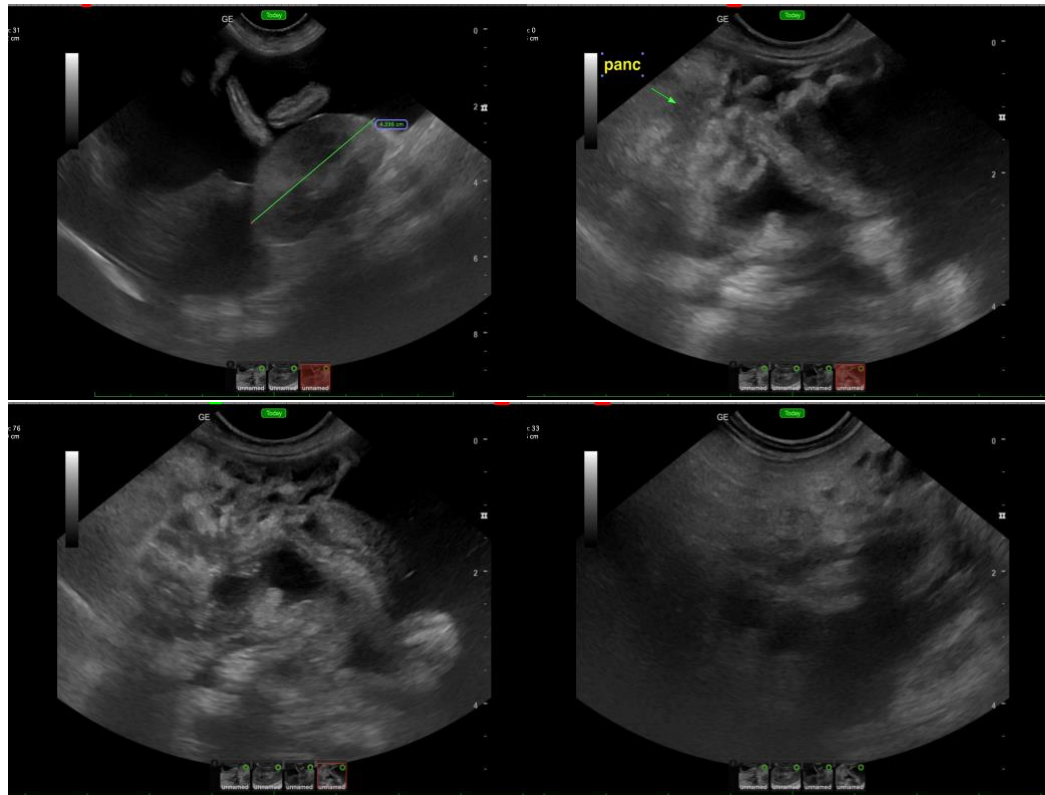
Dr. Brianna Gaines

INVOICE

15049

DATE

04/13/26



The information and recommendations provided are based on the images presented by the referring veterinarian/sonographer. No evaluation can be communicated regarding pathology that was not visible in the image/video clips provided.

Thank you for this referral. If the clinical or image interpretation does not parallel your findings or if I can be of any further assistance, please contact me.

Eric Lindquist, DMV, DABVP(CFM), Cert. IVUSS,

CEO, Owner, Founder -- SonoPath.com

info@SonoPath.com