



PATIENT

Millie Curran

SPECIES

Feline

BREED

Domestic Shorthair

SEX

Spayed female

AGE

15 years

WEIGHT

8.9 lbs

INTERPRETED BY

Eric Lindquist, DMV
DABVP, Cert. IVUSS

IMAGING PERFORMED BY

Jill Rumachik

HOSPITAL NAME

Clarity Imaging LLC

REFERRING VET

Dr. Hoffman

INVOICE

74414

DATE

4/13/26

PRESENTING CLINICAL SIGNS

History: P has been experiencing significant weight loss over the past year despite having a ravenous appetite. Millie, previously weighing over 20 pounds, had decreased to approximately 8.99 pounds. Occasional vomiting and a gurgly gastrointestinal system were noted, but her stools remained normal. Concerns were raised about potential mold exposure affecting Millie's health, as the Owner had experienced health issues due to mold. Blood work had been repeated, but no definitive cause for the weight loss was identified. Millie was on a renal diet due to elevated renal values
Abnormal PE/Chem/CBC/UA Results: 4/2/26: SDMA = 19; BUN = 38; TCO2 = 11; Anion Gap = 30; Total T4 wnl at 2.0

ULTRASONOGRAPHIC EXAMINATION OF THE ABDOMEN

Urinary System

The **urinary bladder**, trigone, and pelvic urethra presented normal thicknesses and normal tone. The ureters were not visible which is normal. No uroliths or sediment were visualized and anechoic urine was present. No evidence of inflammatory or neoplastic changes was noted. Ureteral papillae were normal.

The **kidneys** revealed largely normal size and structure, corticomedullary definition and ratio (cortex 1/3 of medulla) were essentially maintained with some age-related loss of curvilinear patterns regarding the capsule and C/M junction. The cortices presented largely uniform texture with some increased echogenicity expected for this age patient. Medullary structure differed distinctly from that of the cortex and no evidence of pelvic dilation was present. Slight pinpoint mineralization was noted. The left kidney measured 3.0 cm. The right kidney measured 3.5 cm.

Adrenal Glands

Both **adrenal glands** were visualized and recognized as having normal shape, size, position and echogenicity for this breed. The phrenic vasculature, glandular echogenicity and detail were unremarkable. Capsule, cortex, and medullary definition were normal for this age patient.

Spleen

The **spleen** presented a smooth homogeneous parenchyma hyperechoic to liver and renal cortical parenchyma. The capsule was smooth without noticeable expansion or deviation from within the spleen or adjacent pathology. The splenic vasculature demonstrated normal volume without signs of congestion or thrombosis. No sonographic evidence of acute or chronic inflammatory, neoplastic, or infarctual changes was noted.

Liver



PATIENT

Millie Curran

SPECIES

Feline

BREED

Domestic Shorthair

SEX

Spayed female

AGE

15 years

WEIGHT

8.9 lbs

INTERPRETED BY

Eric Lindquist, DMV
DABVP, Cert. IVUSS

IMAGING PERFORMED BY

Jill Rumachik

HOSPITAL NAME

Clarity Imaging LLC

REFERRING VET

Dr. Hoffman

INVOICE

74414

DATE

4/13/26

The **liver** images from right and left intercostal as well as subcostal views revealed subjectively normal liver size, contour, and structure. Some age-related parenchymal remodeling was noted but likely not clinically significant at this time. Vascular and biliary tracts were of normal volume and no evidence of congestion was noted. The gallbladder presented some dependent debris with essentially normal contour. The cystic and common bile ducts were normal. No overt evidence of active inflammatory, infiltrative or regenerative pathology was noted but should be paired with current or past LE elevations regarding any clinical significance to this presentation. The hepatic lymph nodes were unremarkable.

Gastrointestinal

The **gastrointestinal tract** revealed mural thinning with hyperperistalsis and dilated lumen. Some shadowing material was noted in the stomach, this is likely hairball accumulation. The small intestines and colon were unremarkable with normal curvilinear mural patterns and content.

Pancreas

The **pancreas** revealed a moderate amount of remodeling noted with heterogenous parenchymal changes. There was no evidence of neoplasia.

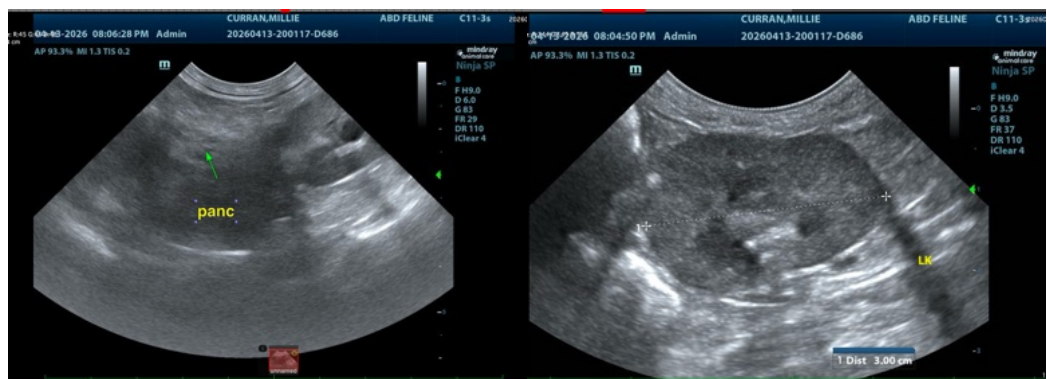
ULTRASONOGRAPHIC FINDINGS

Chronic GI and pancreatic changes, suspect malassimilation/maldigestion.

Possible hairball accumulation in the stomach.

INTERPRETATION OF THE FINDINGS & FURTHER RECOMMENDATIONS

Maldigestion panel, three view chest radiographs and full CNS examination is recommended to examine for occult disease that could be responsible for the weight loss. Evaluation for competitive eating environments should also be considered.





PATIENT

Millie Curran

SPECIES

Feline

BREED

Domestic Shorthair

SEX

Spayed female

AGE

15 years

WEIGHT

8.9 lbs

INTERPRETED BY

Eric Lindquist, DMV
DABVP, Cert. IVUSS

IMAGING PERFORMED BY

Jill Rumachik

HOSPITAL NAME

Clarity Imaging LLC

REFERRING VET

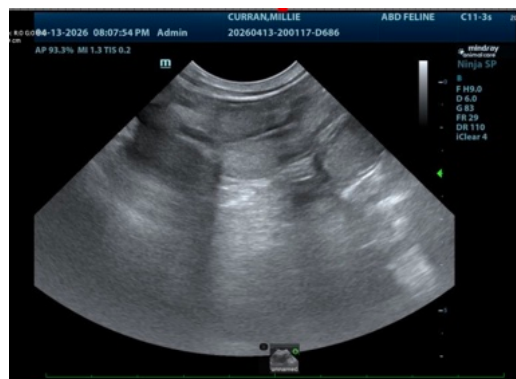
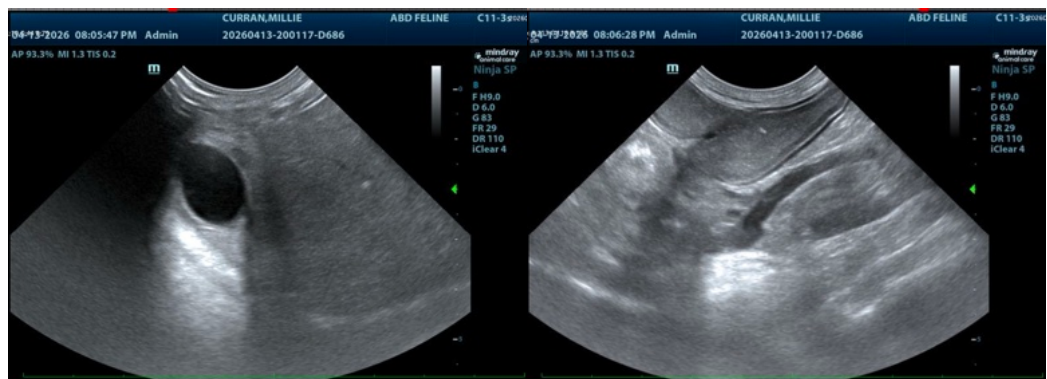
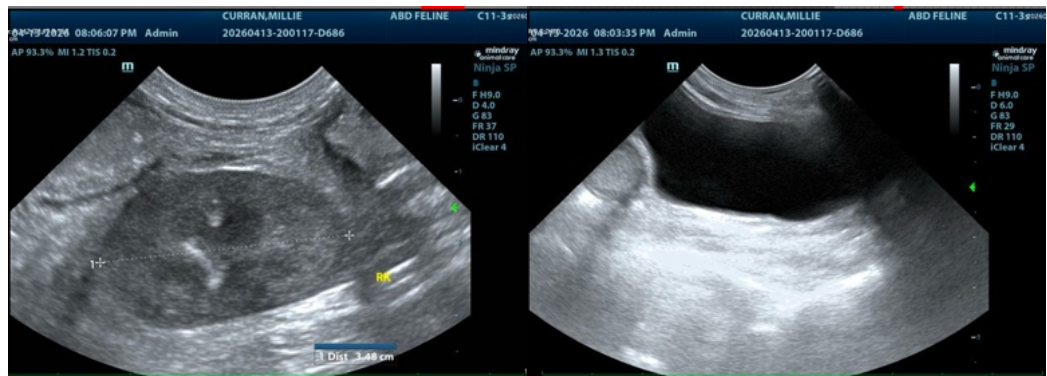
Dr. Hoffman

INVOICE

74414

DATE

4/13/26



The information and recommendations provided are based on the images presented by the referring veterinarian/sonographer. No evaluation can be communicated regarding pathology that was not visible in the image/video clips provided.

Thank you for this referral. If the clinical or image interpretation does not parallel your findings or if I can be of any further assistance please contact me.

Eric Lindquist, DMV, DABVP (CFM), Cert. IVUSS, CEO of SonoPath.com

info@SonoPath.com