



PATIENT

Brylee Riden

SPECIES

Canine

BREED

Shih Tzu

SEX

Spayed female

AGE

9 years

WEIGHT

19 lbs

INTERPRETED BY

Eric Lindquist, DMV
DABVP, Cert. IVUSS

IMAGING PERFORMED BY

Dr. Hollway

HOSPITAL NAME

Valley Green VH

REFERRING VET

Dr. Oberer-Gerber

INVOICE

74417

DATE

4/13/26

PRESENTING CLINICAL SIGNS

History: No C/S/V/D. Eating Normally. PU/PD -- still having accidents in the house - mostly on runner going to front door. Owner removed runner but now Patient is having accident near a rug in same area; excessive drinking. Diet = fresh pet and blue buffalo fresh food. O feels P's energy level has returned to normal since being groomed. Hx scabies 2025.

Abnormal PE/Chem/CBC/UA Results: BAR. No obvious masses palpable in ABD and Patient does allow deep palpation. Mild discomfort still present. Regular rhythm; no murmur detected. Lungs auscultate clear bilaterally; trachea clear. Bladder palpates normally. HOODED VULVA. BCS 8/9; ambulatory x4. Mass L cranio-lateral flank, stable. ~1-2mm dermal non-ulcerative mass left ventral neck just distal to the left salivary gland; mild dark crusting along back -- no evidence of pyoderma at this time. Darkly pigmented thickened skin around vulva likely secondary to chronic inflammation. Grade 2 Dental Disease. Recent labwork submitted also. 4/8/26 PT/PTT = NSF

ULTRASONOGRAPHIC EXAMINATION OF THE ABDOMEN

Urinary System

The **urinary bladder**, trigone, and pelvic urethra presented normal thicknesses and normal tone. The ureters were not visible which is normal. No uroliths or sediment were visualized and anechoic urine was present. No evidence of inflammatory or neoplastic changes was noted. Ureteral papillae were normal.

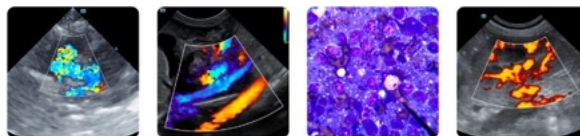
The **kidneys** revealed largely normal size and structure, corticomedullary definition and ratio (cortex 1/3 of medulla) were essentially maintained with some age-related loss of curvilinear patterns regarding the capsule and C/M junction. The cortices presented largely uniform texture with some increased echogenicity expected for this age patient. Medullary structure differed distinctly from that of the cortex and no evidence of pelvic dilation was present. Slight mineralization was noted in the kidneys. The left kidney measured 4.45 cm. The right kidney measured 4.86 cm.

Adrenal Glands

The left **adrenal gland** appeared to be enlarged and irregular measuring 2.4 x 1.5 cm. The right adrenal gland was fairly normal in size and contour with slight irregularity measuring 0.7 cm at the cranial pole and 0.58 cm at the caudal pole. A hyperechoic nodule was noted at the mid body of the right adrenal gland and measured 1.0 cm.

Spleen

The **spleen** was largely smooth with subtle heterogeneous parenchymal changes while maintaining normal echogenic relationship to the liver and kidney. These changes are consistent with normal age-related alteration. The capsule was smooth without noticeable impingement from within the spleen or from pathology in the adjacent abdomen. The splenic vasculature demonstrated normal volume without signs of congestion or significant contraction. No evidence of active acute or chronic inflammatory, neoplastic, or infarctual changes was noted.



PATIENT

Liver

Brylee Riden

The left cranial **liver** was slightly hypoechoic, yet not overtly disruptive. This is most consistent with adenoma. The gallbladder presented some dependent debris with essentially normal contour. The cystic and common bile ducts were normal. The hepatic lymph nodes were unremarkable.

SPECIES

Canine

BREED

Shih Tzu

SEX

Spayed female

AGE

9 years

WEIGHT

19 lbs

Gastrointestinal

Examination of the **gastrointestinal tract** revealed a stomach and intestine free of stasis, of normal wall thickness, acceptable curvilinear mural detail, and peristaltic activity. Small and large intestine demonstrated normal luminal chyme and stool consistency respectively. No obstructive or overt infiltrative disease was noted. No associated abnormal lymphatic activity was noted.

Pancreas

The base and limbs of the **pancreas** were observed to be largely isoechoic to surrounding omental fat. Pancreatic duct and capsular contour were acceptably normal and parenchyma respected normal curvilinear patterns. No overt evidence of active inflammatory or neoplastic disease was noted.

INTERPRETED BY

Eric Lindquist, DMV
DABVP, Cert. IVUSS

ULTRASONOGRAPHIC FINDINGS

Enlarged left adrenal.

Nodular right adrenal.

IMAGING PERFORMED BY

Dr. Hollway

HOSPITAL NAME

Valley Green VH

REFERRING VET

Dr. Oberer-Gerber

INVOICE

74417

DATE

4/13/26

INTERPRETATION OF THE FINDINGS & FURTHER RECOMMENDATIONS

If the urine specific gravity is less than 1.020 then work-up for Cushing's is indicated. An argument can be made for either PDH or adrenal dependent Cushing's. Further imaging under sedation of the left adrenal would be ideal in this patient to assess its relationship with the vena cava and phrenic vein. However, there was no gross invasion noted.

Serial blood pressure measurements are recommended in this patient. If hypertension is an issue metanephrine level is recommended. If the patient appears Cushingoid and urine specific gravity is less than 1.020 then work-up for adrenal dependent Cushing's is indicated. Recheck is recommended in 2-3 weeks to assess for any progression of the adrenal gland.

Efficient & Accurate Cushing's Work up-Lindquist

Notes regarding Cushing's Clinical Presentations:

Nearly all Cushing's dogs have SAP elevations and true PU/PD (USG < 1.025) and most are polyphagic.

Cushing's dogs are > 6 years and usually > 9 years old, usually have poor skin coats, body scores > 3/5, and are usually sedentary animals.



PATIENT

Brylee Riden

SPECIES

Canine

BREED

Shih Tzu

SEX

Spayed female

AGE

9 years

WEIGHT

19 lbs

INTERPRETED BY

Eric Lindquist, DMV
DABVP, Cert. IVUSS

IMAGING PERFORMED BY

Dr. Hollway

HOSPITAL NAME

Valley Green VH

REFERRING VET

Dr. Oberer-Gerber

INVOICE

74417

DATE

4/13/26

Its important to remember that Cushing's dogs usually look and play the part and other diseases cause false + stress related cortisol spikes. On rare occasion a Cushing's dog will not follow the rules but this is truly an exception.

Potential Cushing's patient workups can be costly and frustrating if not definitive and, in my experience, the non-definitive patient usually has something else going on that may be contributing to some of the clinical signs a Cushing's dog will have, especially SAP elevations or PU/PD. Based on this prelude of information I came up with the following algorithm in the spirit of diagnostic efficiency. The following suggested protocol is based on current available literature on Cushing's disease and extensive clinical-sonographic experience evaluation + Cushing's and False + LDDST & ACTH stim. cases in order to maximize the efficiency of a Cushing's workup in practice.

Screen first, workup second

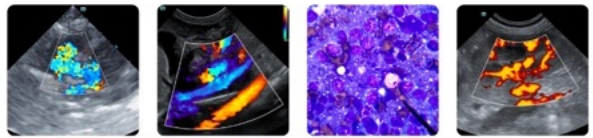
1) **UA:** Repeatable (2-3 urine samples) Urine specific gravity & urine cortisol/creatinine ratio (UCCR): If **repeatable USG < 10.20 and + UCCR** move to next step 2.

Note: UA is inexpensive and easy to obtain and if UA criteria is not met for Cushing's then resources can be spent into other more pertinent diagnostics or left on hold until the UA criteria is met in emerging Cushing's cases.

2) **Sonogram:** Does the patient **have concurrent disease** clinically or sonographically as non-Cushing's illness will influence the potential false + LDDST or even ACTH stim. The sonogram gives a global perspective of the internal health of the patient to be considered in the Cushing's workup as an assessment of concurrent disease. Is there a concurrent neoplastic process, UTI pancreatitis, mucocele....? Are the adrenals enlarged (Cushing's-PDH, stress, age related or breed variant), or atrophied (Iatrogenic Cushing's or adrenal burnout), have asymmetric enlargement (Adrenal tumor, hyperplasia, adenoma, age related variant), or is there vascular invasion (Invasive pheo with false + UA criteria or adenocarcinoma or phrenic thrombosis)? The sonogram answers these questions proactively.

Address & treat concurrent disease first before performing Cushing's testing or testing will be artificially altered increasing false negatives and positives.

3) **LDDST** (0.01 D-Sodium phosphate mg/kg IV **with precise dosing******) (Better screening test but plagued with false + but considered more specific than ACTH stim) Use if there is potential early Cushing's or if adrenal asymmetry present on sonogram suspecting tumor. Use LDDST in cats at a higher dose (0.1 mg/kg IV). **Interpretation LDDST:** Look at 8-hour post first: If > 1.4 = Cushing's. Then look at 4-hour: if > 1.4 or > 50% baseline = Cushing's. 4-hour do then 8-hour spike most consistent with PDH. Flat line high constant curve without dip more consistent with tumor but can be PDH. See attached graph.



PATIENT

Brylee Riden

SPECIES

Canine

BREED

Shih Tzu

SEX

Spayed female

AGE

9 years

WEIGHT

19 lbs

INTERPRETED BY

Eric Lindquist, DMV
DABVP, Cert. IVUSS

IMAGING PERFORMED BY

Dr. Hollway

HOSPITAL NAME

Valley Green VH

REFERRING VET

Dr. Oberer-Gerber

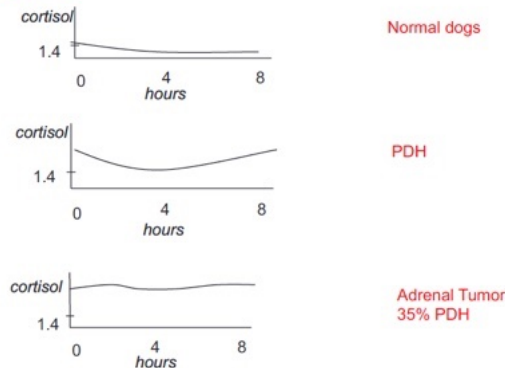
INVOICE

74417

DATE

4/13/26

LDDS



Courtesy: Rebecca Berg DACVIM, DECVIM

4) **ACTH stim.** (Better confirming test but can have false +) Use if the patient “looks” Cushingoid or if bilateral adrenal enlargement is present, or high normal width on sonogram, or if iatrogenic Cushing’s suspected (Cortisone Tx in past). ACTH stim is better for diagnosis of Addisons, iatrogenic Cushing’s, and Cushing’s therapy monitoring but problematic with initial Cushing’s diagnosis. First dx LDDST is suggested.

5) If **diabetic** then run both LDDST & ACTH stim but stabilize as much as possible first.

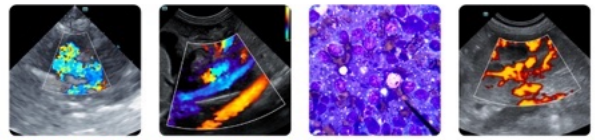
5) Run a **serial blood pressure** in a BP friendly non “white coat effect” atmosphere. Run at least 3 at different times over a few hours or when eating as the patient tends to be calm when eating or give Torbutrol when entering the facility. Cushing’s hypertension is usually 150-180 systolic range while pheochromocytoma range is more often > 180 systolic.

6) **Perform CT** of the pituitary to identify macro adenoma expansion if any lethargy or dullness or other central clinical CNS signs are minimally present. CT for adrenal may be more thorough for adrenalectomy surgical planning if ultrasound views of the CVC were problematic.

7) **Adrenalectomy** for adrenal mass is prescribed then it is essential to stabilize the patient first regarding secondary disease such as organ dysfunction, hypertension, diabetes mellitus, hypernatremia, thromboembolic risk urinary and other infection in order to minimize potential for operative and postoperative complications as they are common in adrenalectomy. Trilostane stabilization therapy for Cushing’s would be the first approach then address surgery and hypertension should be managed ideally < 160 systolic with ace inhibitors, phenoxybenzamine, or amlodipine.

Suggested reading:

Behrend EN, Kooistra HS, Nelson R, et al. Diagnosis of Spontaneous Canine Hyperadrenocorticism: 2012 ACVIM Consensus Statement (Small Animal). J Vet Intern Med 2013;27:1292–1304 .



PATIENT

Brylee Riden

SPECIES

Canine

BREED

Shih Tzu

SEX

Spayed female

AGE

9 years

WEIGHT

19 lbs

INTERPRETED BY

Eric Lindquist, DMV
DABVP, Cert. IVUSS

IMAGING PERFORMED BY

Dr. Hollway

HOSPITAL NAME

Valley Green VH

REFERRING VET

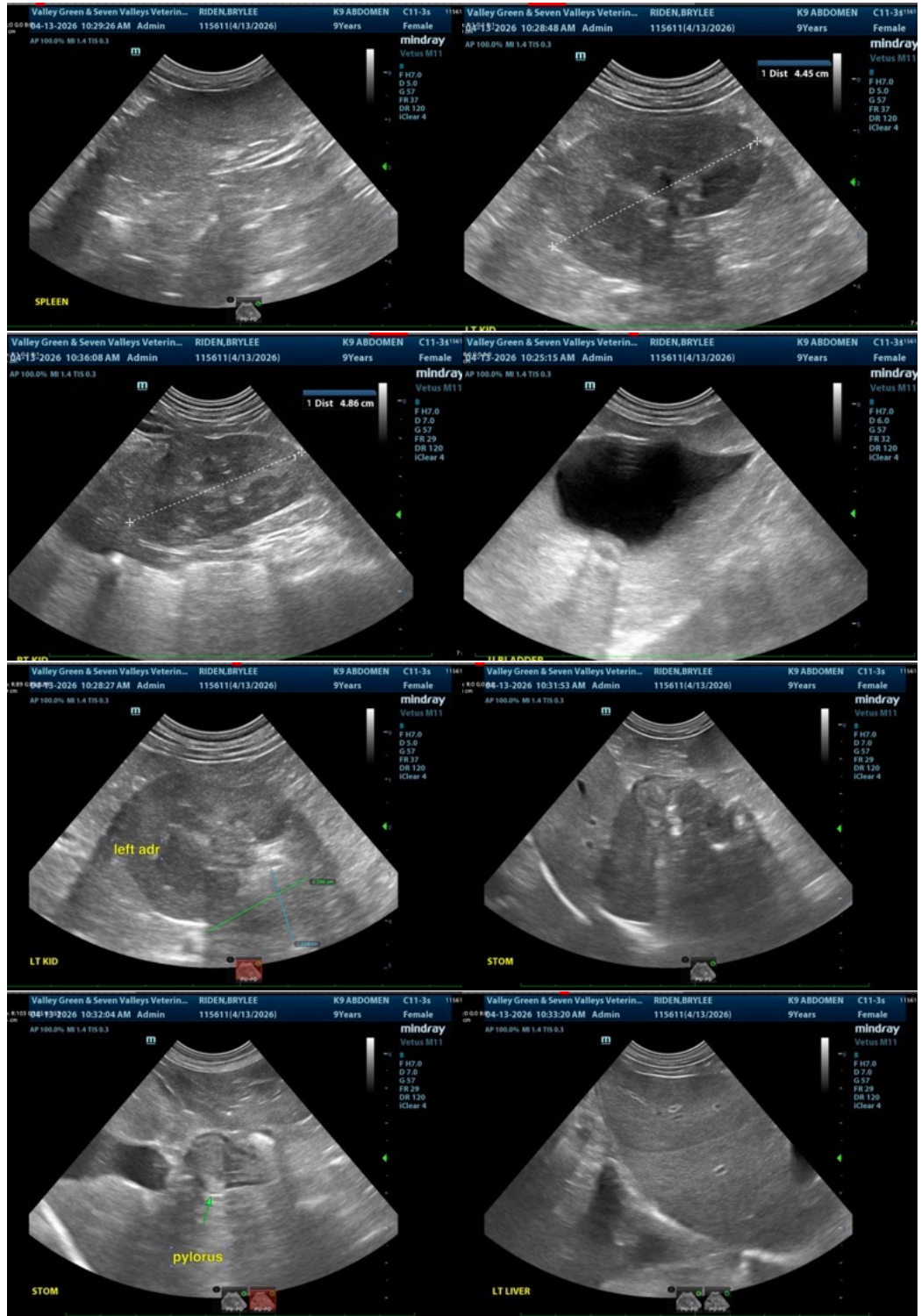
Dr. Oberer-Gerber

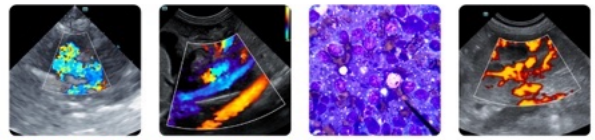
INVOICE

74417

DATE

4/13/26





PATIENT

Brylee Riden

SPECIES

Canine

BREED

Shih Tzu

SEX

Spayed female

AGE

9 years

WEIGHT

19 lbs

INTERPRETED BY

Eric Lindquist, DMV
DABVP, Cert. IVUSS

IMAGING PERFORMED BY

Dr. Hollway

HOSPITAL NAME

Valley Green VH

REFERRING VET

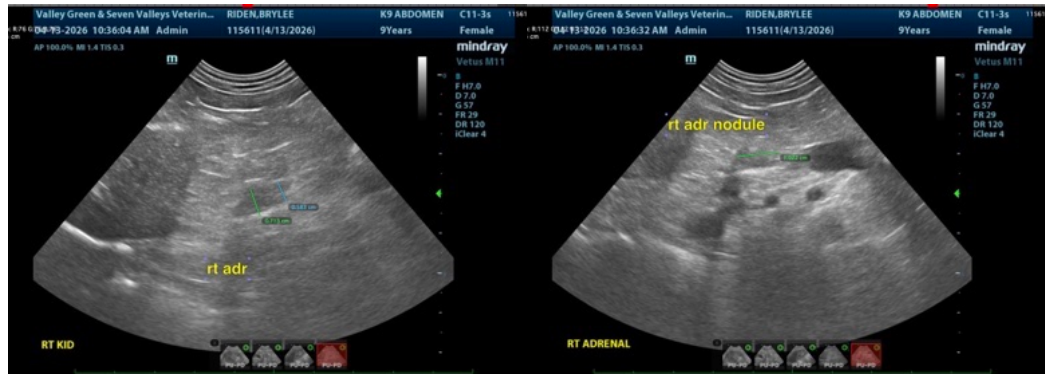Dr. Oberer-Gerber

INVOICE

74417

DATE

4/13/26



The information and recommendations provided are based on the images presented by the referring veterinarian/sonographer. No evaluation can be communicated regarding pathology that was not visible in the image/video clips provided.

Thank you for this referral. If the clinical or image interpretation does not parallel your findings or if I can be of any further assistance please contact me.

Eric Lindquist, DMV, DABVP (CFM), Cert. IVUSS, CEO of SonoPath.com

info@SonoPath.com