



PATIENT

Annie Sullivan

SPECIES

Canine

BREED

King Charles Cavalier

SEX

Spayed female

AGE

4 years

WEIGHT

32 lbs

INTERPRETED BY

Eric Lindquist, DMV
DABVP, Cert. IVUSS

IMAGING PERFORMED BY

JK

HOSPITAL NAME

Hamburg VC

REFERRING VET

Dr. Branning

INVOICE

74413

DATE

4/13/26

PRESENTING CLINICAL SIGNS

History: Chronic UTIs. Improves with antibiotics but returns after finishing
Abnormal PE/Chem/CBC/UA Results: Crystals present in urine. Concern for stones

ULTRASONOGRAPHIC EXAMINATION OF THE ABDOMEN

Urinary System

The **urinary bladder** revealed minor excessive thickening at mild repletion measuring 0.8 cm with anechoic urine. There was no evidence of urethral pathology. Minor polypoid changes were noted in the apex of the bladder.

The **kidneys** revealed normal size and structure, corticomedullary definition and ratio for this age. The cortices presented largely uniform texture with normal echogenic relationship to liver and spleen. Medullary structure differed distinctly from the cortex. The capsules were acceptably uniform without significant irregularities. The right kidney measured 5.6 cm. The left kidney measured 5.2 cm with slight pyelectasia. Embedded bacteria in the kidney may be an issue.

Adrenal Glands

Both **adrenal glands** were visualized and recognized as having normal shape, size, position and echogenicity for this breed. The phrenic vasculature, glandular echogenicity and detail were unremarkable. Capsule, cortex, and medullary definition were normal for this age patient. The left adrenal gland measured 2.16 x 0.43 cm. The right adrenal gland measured 0.79 cm at the cranial pole and 0.63 cm at the caudal pole.

Spleen

The **spleen** presented a smooth homogeneous parenchyma hyperechoic to liver and renal cortical parenchyma. The capsule was smooth without noticeable expansion or deviation from within the spleen or adjacent pathology. The splenic vasculature demonstrated normal volume without signs of congestion or thrombosis. No sonographic evidence of acute or chronic inflammatory, neoplastic, or infarctual changes was noted.

Liver

The **liver** images submitted revealed subjectively normal liver size, contour, and structure. Parenchymal echogenicity was naturally coarse and hypoechoic to the spleen. Vascular and biliary tracts were of normal volume with no evidence of congestion. The gallbladder presented acceptably thin walls with primarily anechoic content. The cystic and common bile ducts were normal. No pathological hepatic lymphadenopathy was evident. No overt structural evidence of inflammatory, infiltrative or regenerative pathology was evident.



PATIENT

Annie Sullivan

SPECIES

Canine

BREED

King Charles Cavalier

SEX

Spayed female

AGE

4 years

WEIGHT

32 lbs

INTERPRETED BY

Eric Lindquist, DMV
DABVP, Cert. IVUSS

IMAGING PERFORMED BY

JK

HOSPITAL NAME

Hamburg VC

REFERRING VET

Dr. Branning

INVOICE

74413

DATE

4/13/26

Gastrointestinal

Examination of the **gastrointestinal tract** revealed a stomach and intestine free of stasis, of normal wall thickness, acceptable curvilinear mural detail, and peristaltic activity. Small and large intestine demonstrated normal luminal chyme and stool consistency respectively. No obstructive or overt infiltrative disease was noted. No associated abnormal lymphatic activity was noted.

Pancreas

The base and limbs of the **pancreas** were observed to be largely isoechoic to surrounding omental fat. Pancreatic duct and capsular contour were acceptably normal and parenchyma respected normal curvilinear patterns. No overt evidence of active inflammatory or neoplastic disease was noted.

ULTRASONOGRAPHIC FINDINGS

Mild chronic cystitis bladder pattern without urethral pathology. Potential renal involvement.

INTERPRETATION OF THE FINDINGS & FURTHER RECOMMENDATIONS

3-4 week antibiotic therapy may be necessary for clearing any infection that may be present in this patient. Examination of the vaginal vestibule for predisposing issues is also indicated.

Canine Chronic UTI Protocol

To be utilized for UTI with chronic urinary tract changes found sonographically that may serve as nidus of infection and history of chronic or recurrent UTI is an issue.

I recommend Clavamox as a first level approach to chronic UTI at 12.5-25 mg/kg bid owing to optimal urinary concentrations. If bacterial resistance is an issue then **Enrofloxacin** (5-10 mg/kg SID PO) (In patients > 1 year of age) in late pm after urination to maximize urinary concentrations overnight. This assumes that culture supports this use. Repeat **culture** at 3-4 weeks and continue treatment at least 7-10 days post negative urinary sediment and negative culture. *Note: Negative culture does not necessarily mean lack of UTI.* Other favorite antibiotics for chronic UTI include third generation Cefa (Ceftiafur or similar s.i.d. injectable) or Clavamox. If suspicion of occult urinary incontinence is present then **phenylpropanolamine (PPA)** (1-2 mg/kg BID) can be employed long term to enhance urethral tone.



PATIENT

Annie Sullivan

SPECIES

Canine

BREED

King Charles Cavalier

SEX

Spayed female

AGE

4 years

WEIGHT

32 lbs

INTERPRETED BY

Eric Lindquist, DMV
DABVP, Cert. IVUSS

IMAGING PERFORMED BY

JK

HOSPITAL NAME

Hamburg VC

REFERRING VET

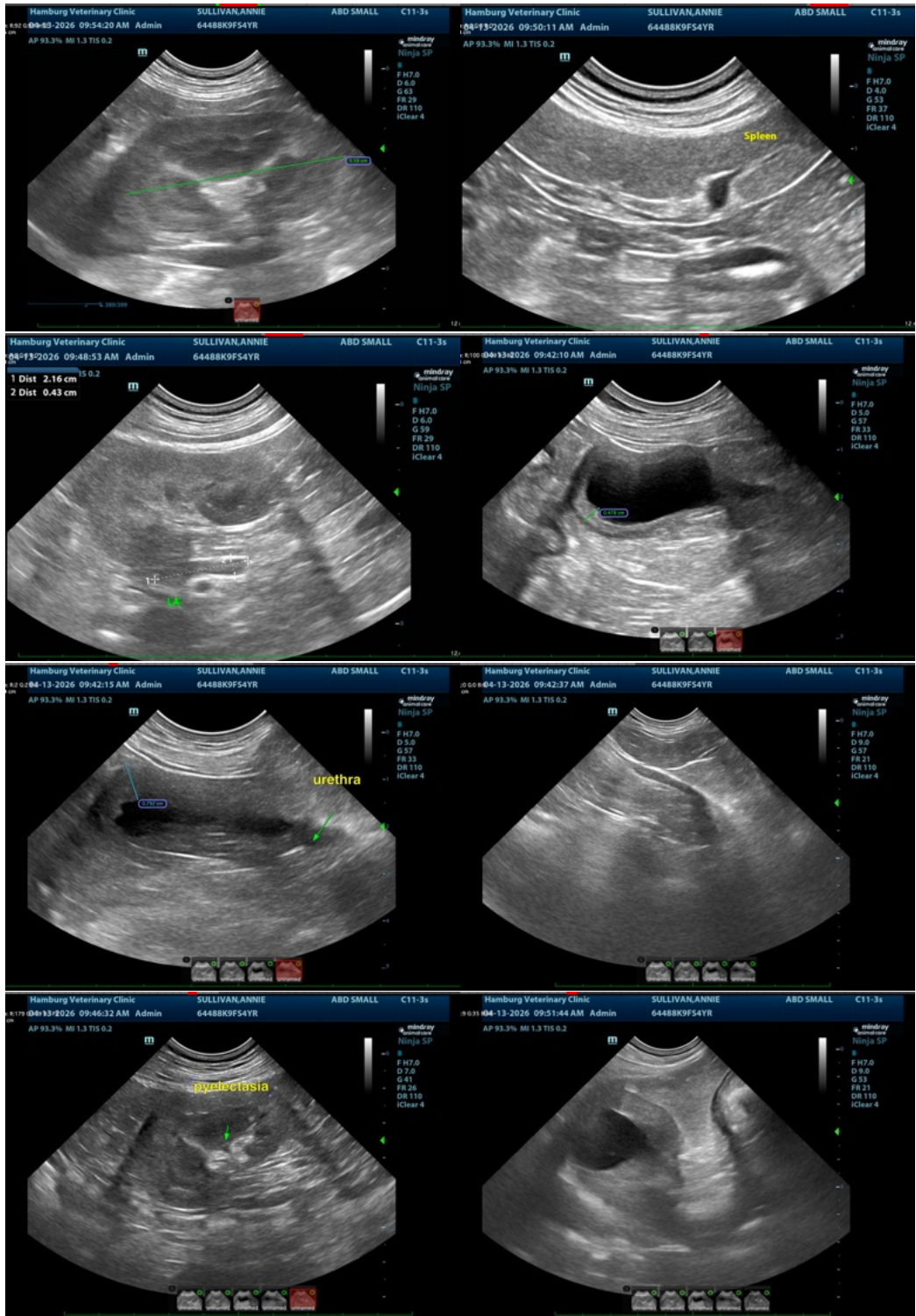
Dr. Branning

INVOICE

74413

DATE

4/13/26





PATIENT

Annie Sullivan

SPECIES

Canine

BREED

King Charles Cavalier

SEX

Spayed female

AGE

4 years

WEIGHT

32 lbs

INTERPRETED BY

Eric Lindquist, DMV
DABVP, Cert. IVUSS

IMAGING PERFORMED BY

JK

HOSPITAL NAME

Hamburg VC

REFERRING VET

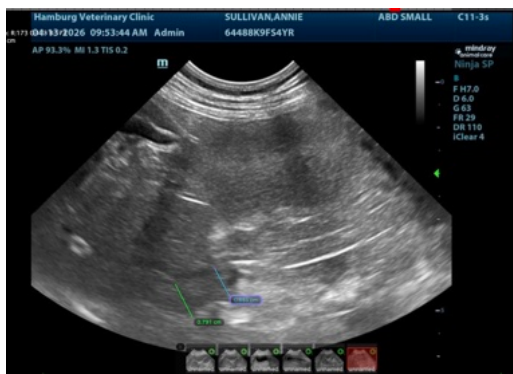Dr. Branning

INVOICE

74413

DATE

4/13/26



The information and recommendations provided are based on the images presented by the referring veterinarian/sonographer. No evaluation can be communicated regarding pathology that was not visible in the image/video clips provided.

Thank you for this referral. If the clinical or image interpretation does not parallel your findings or if I can be of any further assistance please contact me.

Eric Lindquist, DMV, DABVP (CFM), Cert. IVUSS, CEO of SonoPath.com

info@SonoPath.com