



PATIENT

Percy Sylvia

SPECIES

Feline

BREED

DSH

SEX

Neutered Male

AGE

13 Years

WEIGHT

13.1

INTERPRETED BY

Eric Lindquist, DMV
DABVP, Cert. IVUSS

IMAGING PERFORMED BY

Heather

HOSPITAL NAME

ACC Flanders

REFERRING VET

Dr. Casulli

INVOICE

21974

DATE

4/13/23

PRESENTING CLINICAL SIGNS

History: Multiple illness visits over the past two months and painful abdomen, diarrhea and gas R/O - IBD, Pancreatitis, etc. starting proviable, cerenia and intestinal diet today

Abnormal PE/Chem/CBC/UA Results: bw all WNL

ULTRASONOGRAPHIC EXAMINATION OF THE ABDOMEN

Urinary System

The **urinary bladder**, trigone, and pelvic urethra presented normal thicknesses and normal tone. The ureters were not visible which is normal. No uroliths or sediment were visualized and anechoic urine was present. No evidence of inflammatory or neoplastic changes were noted. Ureteral papillae were normal.

The **kidneys** revealed normal size and structure, corticomedullary definition and ratio for this age. The cortices presented largely uniform texture with normal echogenic relationship to liver and spleen. Medullary structure differed distinctly from the cortex and no evidence of pelvic dilation was present. The capsules were acceptably uniform without significant irregularities. The kidneys measured 3.5 cm each.

Adrenal Glands

The regions of the **adrenal glands** revealed no evidence of pathology.

Spleen

The **spleen** presented a smooth homogeneous parenchyma hyperechoic to liver and renal cortical parenchyma. The capsule was smooth without noticeable expansion or deviation from within the spleen or adjacent pathology. The splenic vasculature demonstrated normal volume without signs of congestion or thrombosis. No sonographic evidence of acute or chronic inflammatory, neoplastic, or infarctual changes were noted.

Liver

The **liver** images submitted revealed subjectively normal liver size, contour, and structure. Parenchymal echogenicity was naturally coarse and hypoechoic to the spleen. Vascular and biliary tracts were of normal volume with no evidence of congestion. The gallbladder presented acceptably thin walls with primarily anechoic content. The cystic and common bile ducts were normal. No pathological hepatic lymphadenopathy was evident. No overt structural evidence of inflammatory, infiltrative or regenerative pathology was evident.

Gastrointestinal

Some retention of ingesta or possible hair accumulation was noted in the stomach. The small intestine and colon were unremarkable.

Pancreas

The base and limbs of the **pancreas** were observed to be largely isoechoic to surrounding omental fat. Pancreatic duct and capsular contour were acceptably normal and parenchyma respected normal curvilinear patterns. No overt evidence of active inflammatory or neoplastic disease was noted.

ULTRASONOGRAPHIC FINDINGS



PATIENT

- Structurally unremarkable abdomen with possible minor hair accumulation in the stomach

Percy Sylvia

INTERPRETATION OF THE FINDINGS & FURTHER RECOMMENDATIONS

No evidence of significant disease. The cause of tense abdomen is unclear. Underlying occult parasitism, dietary intolerance, dietary indiscretion are all potentials in this case.

SPECIES

Feline

BREED

DSH

SEX

Neutered Male

AGE

13 Years

WEIGHT

13.1

INTERPRETED BY

Eric Lindquist, DMV
DABVP, Cert. IVUSS

IMAGING PERFORMED BY

Heather

HOSPITAL NAME

ACC Flanders

REFERRING VET

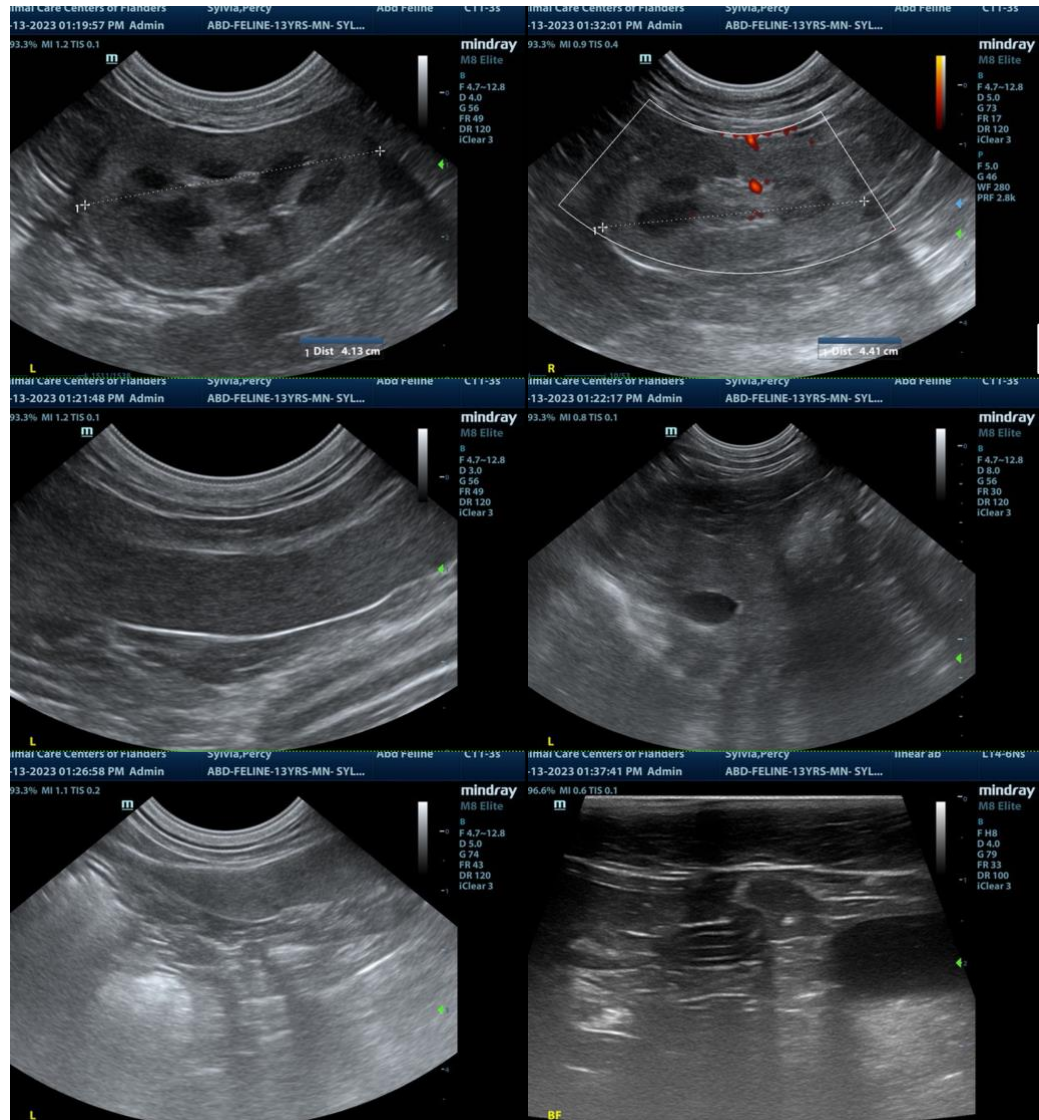
Dr. Casulli

INVOICE

21974

DATE

4/13/23



The information and recommendations provided are based on the images presented by the referring veterinarian. No evaluation can be communicated regarding pathology that was not visible in the image/video clips provided.

Thank you for this referral. If the clinical or image interpretation does not parallel your findings or if I can be of any further assistance please contact me.

Eric Lindquist, DMV, DABVP, Cert. IVUSS, CEO of SonoPath.com



PATIENT

info@SonoPath.com

Percy Sylvia

SPECIES

Feline

BREED

DSH

SEX

Neutered Male

AGE

13 Years

WEIGHT

13.1

INTERPRETED BY

Eric Lindquist, DMV
DABVP, Cert. IVUSS

**IMAGING
PERFORMED BY**

Heather

HOSPITAL NAME

ACC Flanders

REFERRING VET

Dr. Casulli

INVOICE

21974

DATE

4/13/23