



**PATIENT PRESENTING CLINICAL SIGNS**

Delilah Clemens

History: Delilah is an eleven year old, FS, Scottish Terrier with a history of frequent recurring pollakiuria, stranguria, and urinary accidents. She started antibiotic treatment on 4/3/23 Amoxicillin 250 mg PO BID for pyuria, hematuria, proteinuria. Recheck today with scheduled imaging and cystocentesis was scheduled. 26 cines are submitted for evaluation of SDEP positions 1-3 only. I did not obtain a cystocentesis due to the abnormal tissue seen in the trigone. Free catch urine was obtained and showed hematuria with no pyuria or bacteriuria. Delilah was straining to urinate.

**SPECIES**

Canine

**BREED**

Scottish Terrier

**SEX**

Spayed Female

**AGE**

11 years

**WEIGHT**

24 lbs

**INTERPRETED BY**

Eric Lindquist, DMV  
DABVP, Cert. IVUS

**IMAGING PERFORMED BY**

Dr. Todd

**HOSPITAL NAME**

Lambs Gap AH

**REFERRING VET**

Dr. Todd

**INVOICE**

43850

**DATE**

4/13/23

**ULTRASONOGRAPHIC EXAMINATION OF THE ABDOMEN**

**Urinary System**

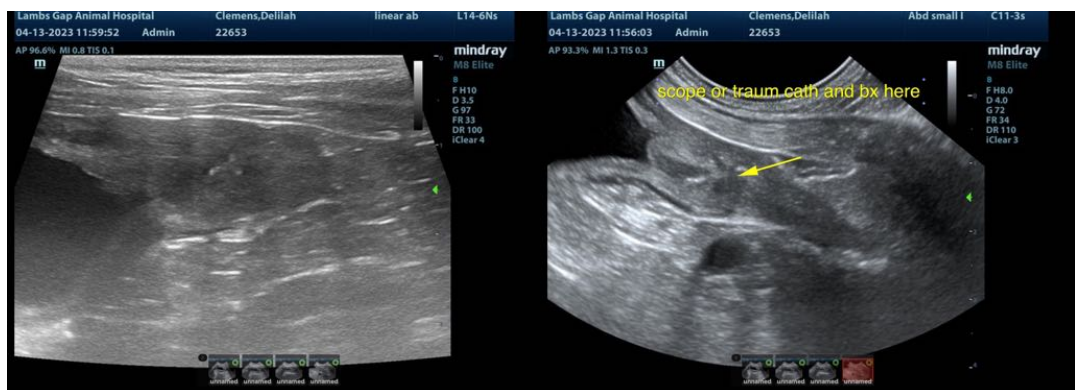
The **urinary bladder** revealed a polypoid change at the cystourethral junction. The ventral aspect of the cystourethral junction and mineralized urethral thickening was noted. This is strongly suggestive for carcinoma. The length measured 1.6 x 1.1 cm in width.

**ULTRASONOGRAPHIC FINDINGS**

Cystourethral junction and mineralized urethral thickening. Suggestive for carcinoma.

**INTERPRETATION OF THE FINDINGS & FURTHER RECOMMENDATIONS**

Traumatic catheterization or scope and laser ablation is indicated where applicable and chemotherapeutic intervention with eventual stent placement is recommended. Culture as well as cytology and histopathology is warranted from a traumatic catheterization sample.





**PATIENT**

Delilah Clemens

**SPECIES**

Canine

**BREED**

Scottish Terrier

**SEX**

Spayed Female

**AGE**

11 years

**WEIGHT**

24 lbs

**INTERPRETED BY**

Eric Lindquist, DMV  
DABVP, Cert. IVUSS

**IMAGING PERFORMED BY**

Dr. Todd

**HOSPITAL NAME**

Lambs Gap AH

**REFERRING VET**

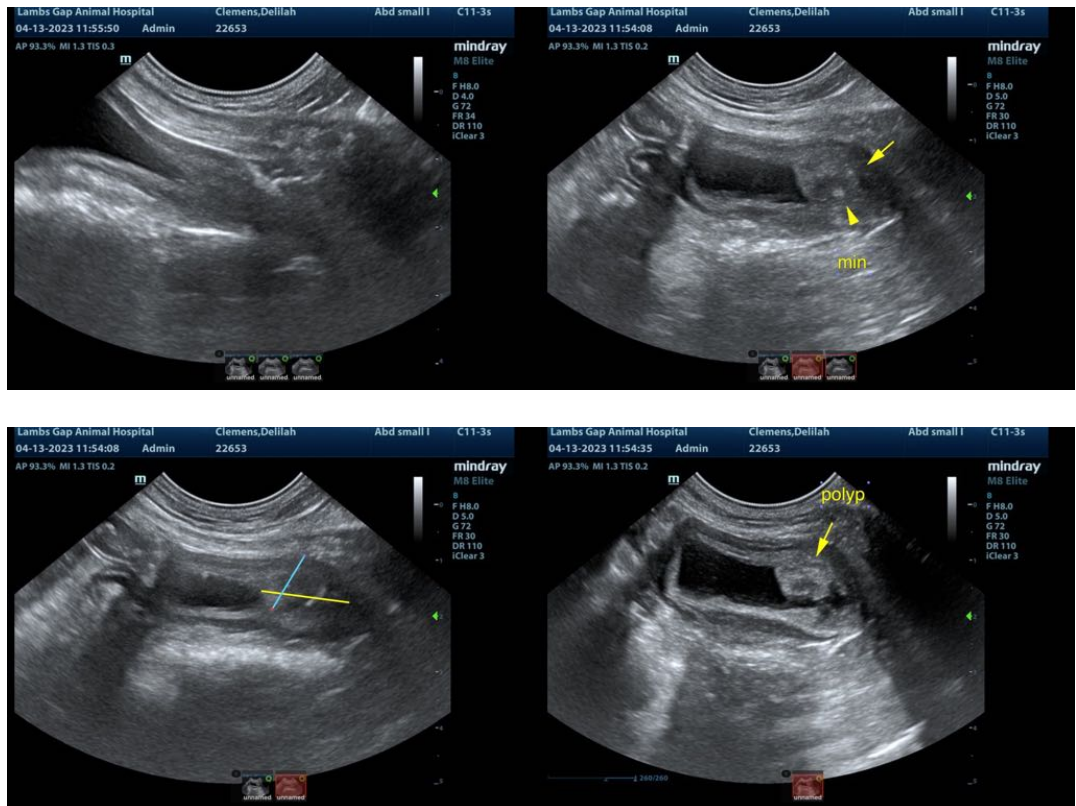
Dr. Todd

**INVOICE**

43850

**DATE**

4/13/23



The information and recommendations provided are based on the images presented by the referring veterinarian/sonographer. No evaluation can be communicated regarding pathology that was not visible in the image/video clips provided.

Thank you for this referral. If the clinical or image interpretation does not parallel your findings or if I can be of any further assistance please contact me.

**Eric Lindquist**, DMV, DABVP, Cert. IVUSS, CEO of SonoPath.com  
info@SonoPath.com