



PATIENT PRESENTING CLINICAL SIGNS

Sadie Krynauw History: weight loss , bilirubin elevated

SPECIES ULTRASONOGRAPHIC EXAMINATION OF THE ABDOMEN

Canine **Urinary System**

BREED

Dachshund

The **urinary bladder**, trigone, and pelvic urethra presented normal thicknesses and normal tone. The ureters were not visible which is normal. No uroliths or sediment were visualized and anechoic urine was present. No evidence of inflammatory or neoplastic changes was noted. Ureteral papillae were normal.

SEX

Spayed Female

The **kidneys** revealed normal size and structure, corticomedullary definition and ratio for this age. The cortices presented largely uniform texture with normal echogenic relationship to liver and spleen. Medullary structure differed distinctly from the cortex and no evidence of pelvic dilation was present. The capsules were acceptably uniform without significant irregularities. Both kidneys measured 3.5 cm.

AGE

5 ½ years

Adrenal Glands

WEIGHT

8.7 lbs

The **adrenal glands** were not visualized.

Spleen

INTERPRETED BY

Eric Lindquist, DMV
DABVP, Cert. IVUSS

The **spleen** presented a smooth homogeneous parenchyma hyperechoic to liver and renal cortical parenchyma. The capsule was smooth without noticeable expansion or deviation from within the spleen or adjacent pathology. The splenic vasculature demonstrated normal volume without signs of congestion or thrombosis. No sonographic evidence of acute or chronic inflammatory, neoplastic, or infarctual changes was noted.

IMAGING PERFORMED BY

Dr. Puthoff

Liver

HOSPITAL NAME

Kings VH

The **liver** images submitted revealed subjectively normal liver size, contour, and structure. Parenchymal echogenicity was naturally coarse and hypoechoic to the spleen. Vascular and biliary tracts were of normal volume with no evidence of congestion. The gallbladder presented acceptably thin walls with primarily anechoic content. The cystic and common bile ducts were normal. No pathological hepatic lymphadenopathy was evident. No overt structural evidence of inflammatory, infiltrative or regenerative pathology was evident.

REFERRING VET

Dr. Puthoff

INVOICE

99272

Gastrointestinal

DATE

4/13/22

Examination of the **gastrointestinal tract** revealed a stomach and intestine free of stasis, of normal wall thickness, acceptable curvilinear mural detail, and peristaltic activity. Small and large intestine demonstrated normal luminal chyme and stool consistency respectively. No obstructive or overt infiltrative disease was noted. No associated abnormal lymphatic activity was noted.



PATIENT

Pancreas

Sadie Krynauw

The base and limbs of the **pancreas** were observed to be largely isoechoic to surrounding omental fat. Pancreatic duct and capsular contour were acceptably normal and parenchyma respected normal curvilinear patterns. No overt evidence of active inflammatory or neoplastic disease was noted.

SPECIES

Canine

ULTRASONOGRAPHIC FINDINGS

BREED

Normal abdomen.

Dachshund

INTERPRETATION OF THE FINDINGS & FURTHER RECOMMENDATIONS

SEX

Structurally normal liver with single bilirubin elevation without liver enzymes reportedly elevated creates concern for lab error. There was no evidence of structural disease.

Spayed Female

AGE

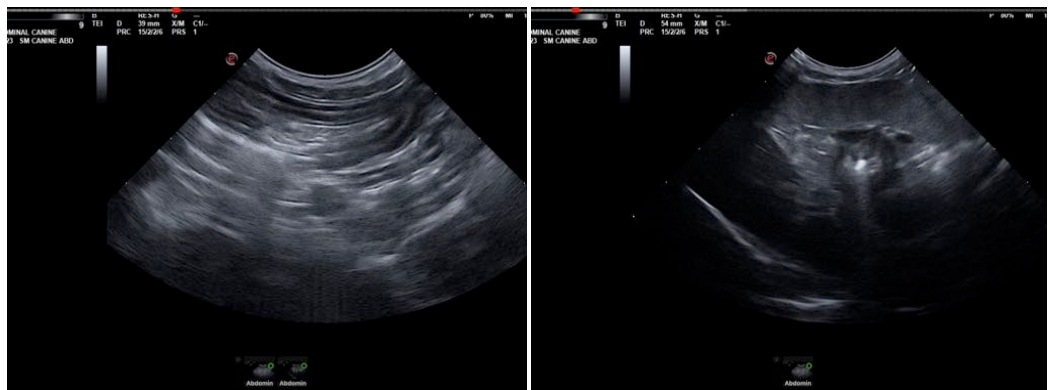
5 ½ years

WEIGHT

8.7 lbs

INTERPRETED BY

Eric Lindquist, DMV
DABVP, Cert. IVUSS

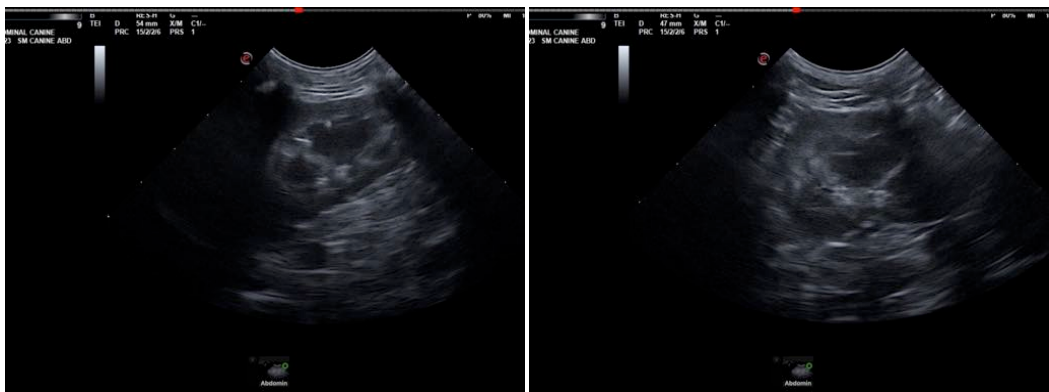


IMAGING PERFORMED BY

Dr. Puthoff

HOSPITAL NAME

Kings VH



REFERRING VET

Dr. Puthoff

INVOICE

99272

DATE

4/13/22



PATIENT

Sadie Krynauw

SPECIES

Canine

BREED

Dachshund

SEX

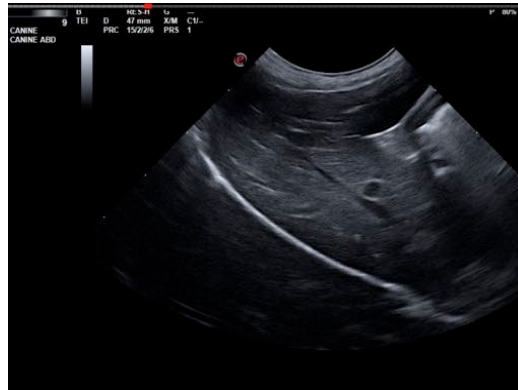
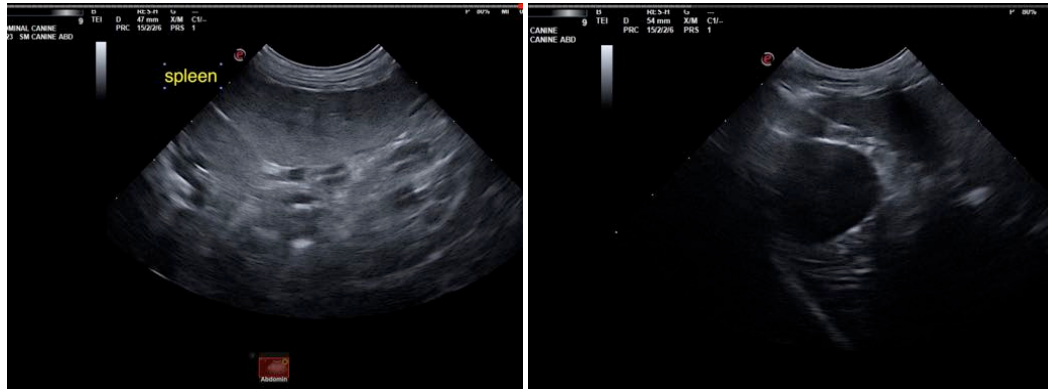
Spayed Female

AGE

5 ½ years

WEIGHT

8.7 lbs



INTERPRETED BY

Eric Lindquist, DMV
DABVP, Cert. IVUSS

IMAGING PERFORMED BY

Dr. Puthoff

HOSPITAL NAME

Kings VH

REFERRING VET

Dr. Puthoff

INVOICE

99272

DATE

4/13/22

The information and recommendations provided are based on the images presented by the referring veterinarian/sonographer. No evaluation can be communicated regarding pathology that was not visible in the image/video clips provided.

Thank you for this referral. If the clinical or image interpretation does not parallel your findings or if I can be of any further assistance please contact me.

Eric Lindquist, DMV, DABVP, Cert. IVUSS, CEO of SonoPath.com
info@SonoPath.com