

**DATE**

4/13/22

PRESENTING CLINICAL SIGNS

Vomiting 4/5/21. Inappetence 4/5/21. Inflamed small intestines.

PATIENT

Lilo Smith

Current Medications: Mirataz, Clavamox 62.5mg BID for 7 days, Cerenia 4mg SID for 4-16 days.

Lab Results: Tbil 1.4, GGT 20, Mild Leukopenia, stress leukogram.

Date of Previous IntraPet Ultrasound: No previous.

Sedation: Not required to complete full diagnostic ultrasound.

Stat Report: Not requested.

SPECIES

Feline

ULTRASONOGRAPHIC EXAMINATION OF THE ABDOMEN**BREED**

DSH

Urinary System

The **urinary bladder**, trigone, and pelvic urethra presented normal thicknesses and normal tone. The ureters were not visible which is normal. No uroliths or sediment were visualized and anechoic urine was present. No evidence of inflammatory or neoplastic changes were noted. Ureteral papillae were normal.

SEX

Spayed Female

The **kidneys** revealed normal size and structure, corticomedullary definition and ratio for this age. The cortices presented largely uniform texture with normal echogenic relationship to liver and spleen. Medullary structure differed distinctly from the cortex and no evidence of pelvic dilation was present. The capsules were acceptably uniform without significant irregularities. The right kidney measured 4.27 cm. The left kidney measured 3.92 cm.

AGE

1/1/13

WEIGHT

10.24 Pounds

Adrenal Glands

Both **adrenal glands** were visualized and recognized as having normal shape, size, position and echogenicity for this breed. The phrenic vasculature, glandular echogenicity and detail were unremarkable. Capsule, cortex, and medullary definition were normal for this age patient. The left adrenal gland measured 0.30 cm.

INTERPRETED BYEric Lindquist, DMV
DABVP, Cert. IVUSS**Spleen**The **spleen** was mildly enlarged at 1.2 cm, unremarkable otherwise.**IMAGING PERFORMED BY**Stephanie Pearce
RDCS, RVT**Liver**

The **liver** parenchyma was uniformly hyperechoic to falciform fat without disruption of architecture. No masses were noted. The gall bladder and common bile duct were unremarkable. This presentation is most consistent with hepatic lipidosis with the minor potential for underlying lymphoma or inflammatory hepatopathy. The potential for these latter pathologies would be based on hepatic enzyme elevations and clinical profile. A 25-gauge US-guided FNA is warranted if any elevation in SAP or bilirubin is present or if anorexia is present to assess cytological disease (lipidosis or round cell neoplasia). Biopsy is warranted if an elevation in ALT is present to assess hepatic portal infrastructure yet should be done with caution owing to parenchymal fragility in these presentations.

HOSPITAL NAME

Northwind AH

Gastrointestinal

The **gastrointestinal** presentation revealed mild uniform prominence of the gastric mucosa as well as areas of "ropey" small intestinal wall with slight disruption of the normal 1:3 muscularis/mucosal ratio. The intestinal submucosa was slightly irregular, thickened and hyperechoic suggestive of low grade, chronic disease. No concerning lymphadenopathy was visible. No evidence of obstruction was present. Chronic inflammatory bowel disease is likely with a low possibility of an early neoplastic event such as lymphoma. Full thickness tissue biopsies via open laparotomy, ideally guided by intraoperative ultrasound in order to obtain the most representative mural sample, would be necessary to rule out this possibility.

REFERRING VET

Dr. Miller

INVOICE

36872

Pancreas

The base and limbs of the **pancreas** were observed to be largely isoechoic to surrounding omental fat. Pancreatic duct and capsular contour were acceptably normal and parenchyma respected normal curvilinear patterns. No overt evidence of active inflammatory or neoplastic disease was noted.

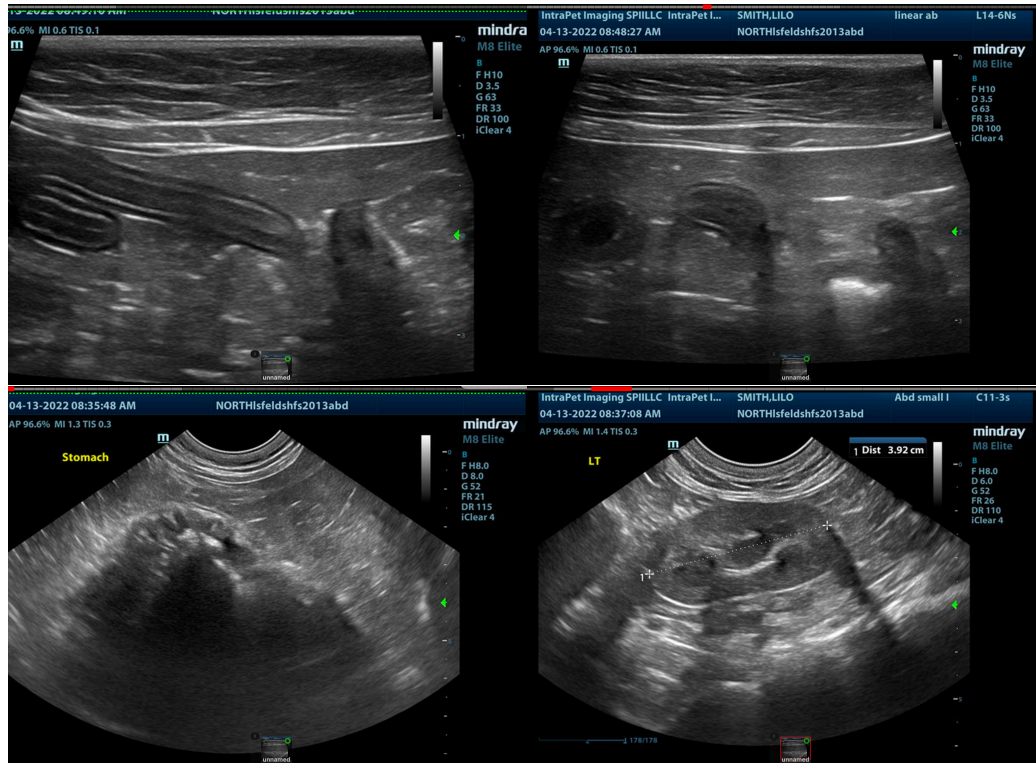
ULTRASONOGRAPHIC FINDINGS

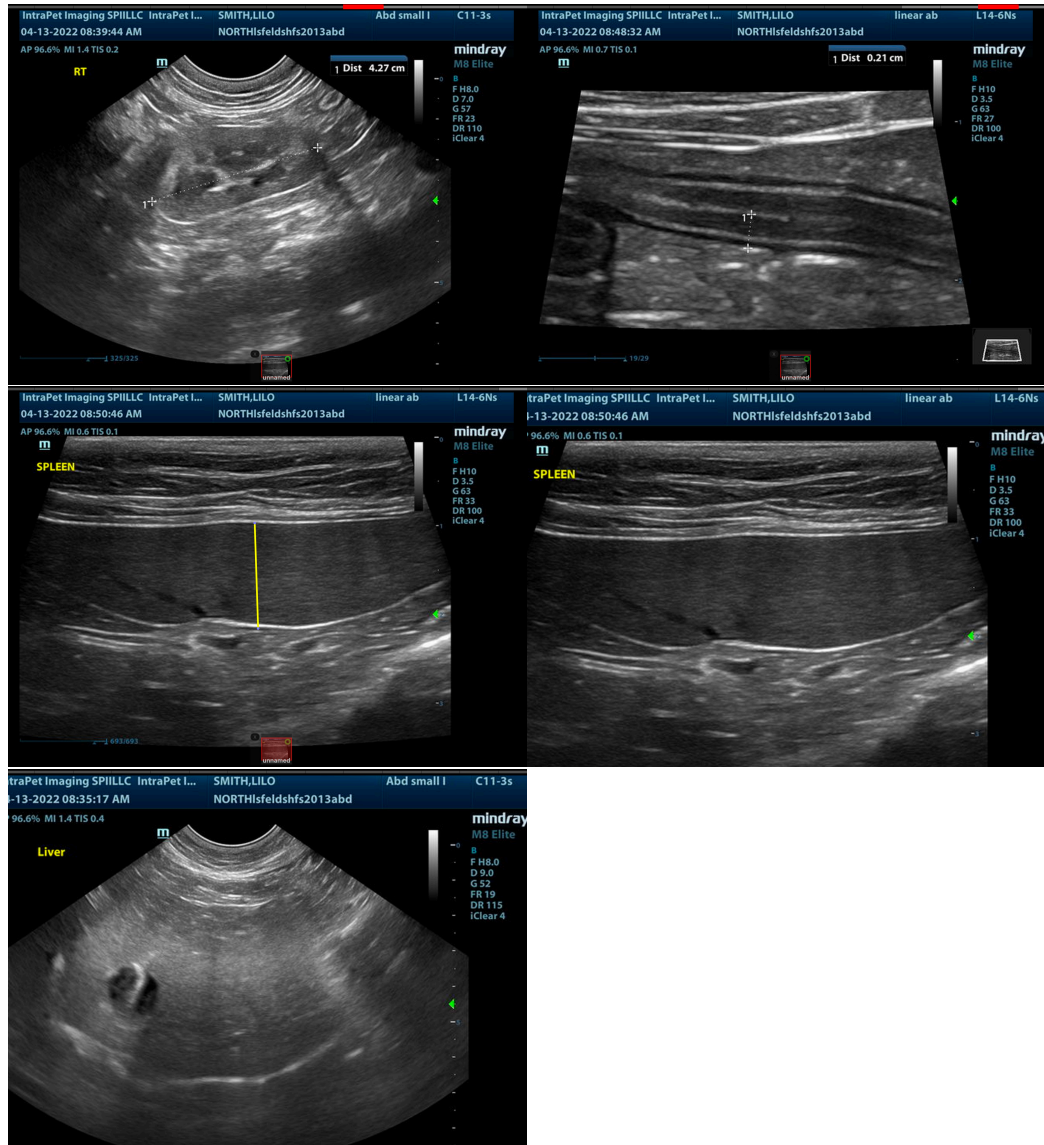
- Mild hepatic lipidosis liver pattern
- Mild splenomegaly
- Minor IBD GI pattern

INTERPRETATION OF THE FINDINGS & FURTHER RECOMMENDATIONS

Given that liver enzymes are not reported to be elevated, this is not likely a clinical issue at this time. If the patient was sedated, this may be secondary to sedation. However, if weight loss is an issue, FNA would be warranted to rule out emerging round cell neoplasia versus reactive spleen. Underlying food intolerance or occult parasitism should be considered. Hydrolyzed diet may be in this patient's best interest long-term. Given the history of inappetence, underlying pancreatitis may have occurred in this patient given that this often accompanies this type of GI presentation. However, structurally the pancreas appears normal at this time.

Radiographs: Minor excessive colonic gas.





The information and recommendations provided are based on the images presented by the referring veterinarian/sonographer. No evaluation can be communicated regarding pathology that was not visible in the image/video clips provided.

Thank you for this referral. If the clinical or image interpretation does not parallel your findings or if I can be of any further assistance please contact me.

Eric Lindquist, DMV, DABVP, Cert. IVUSS, CEO of SonoPath.com
info@SonoPath.com