

IMAGING PERFORMED BY

IntraPet.com



**SonoPath**

Clinical Sonography & Telecytology

EDUCATIONAL TELECONSULTATION SERVICES™

1-800-838-4268 info@sonopath.com SonoPath.com

**DATE**

4/13/22

**PATIENT**

Frankie Bassareb

**SPECIES**

Feline

**BREED**

DSH

**SEX**

Spayed Female

**AGE**

11/16/08

**WEIGHT**

8.9 Pounds

**INTERPRETED BY**

Eric Lindquist, DMV  
DABVP, Cert. IVUSS

**IMAGING PERFORMED BY**

Rachel Brilhart RDMS

**HOSPITAL NAME**

Frederick Road VH

**REFERRING VET**

Dr. Franchini

**INVOICE**

36868

**PRESENTING CLINICAL SIGNS**

Pet presented in Feb of this year for vomiting after eating for 3 weeks. BW showed elevated spec FPL. Pet has been taking cerenia EOD - was helping for a while but then owner noted appetite has been decreasing and pet losing weight and why owner brought pet in today 4/8/2022. One pound weight loss since Feb.

Current Medications: Cerenia 8 mg every 2-3 days PRN, Mirtazipine TD started today q 24 hrs.

Lab Results: BW in Feb showed low end of normal HCT. Today was 28%.

Radiographs: concern for mass effect or enlarged spleen.

Date of Previous IntraPet Ultrasound: No previous.

Sedation: Not required to complete full diagnostic ultrasound.

Stat Report: Not requested.

**ULTRASONOGRAPHIC EXAMINATION OF THE ABDOMEN**

**Urinary System**

The **urinary bladder**, trigone, and pelvic urethra presented normal thicknesses and normal tone. The ureters were not visible which is normal. No uroliths or sediment were visualized and anechoic urine was present. No evidence of inflammatory or neoplastic changes were noted. Ureteral papillae were normal.

The **kidneys** revealed largely normal, corticomedullary definition and ratio (cortex 1/3 of medulla) were essentially maintained with some age-related loss of curvilinear patterns regarding the capsule and C/M junction. The cortices presented largely uniform texture with some increased echogenicity expected for his age patient. Medullary structure differed distinctly from that of the cortex. Mineralization noted in both kidneys. The left kidney was normal in size, measuring 3.8 cm. The right kidney was subnormal in size with slight pyelectasia, measuring 2.5 cm.

**Adrenal Glands**

The regions of the **adrenal glands** were unremarkable.

**Spleen**

The **spleen** was enlarged with scalloping contour, measuring 2.33 cm.

**Liver**

The **liver** images submitted revealed subjectively normal liver size, contour, and structure. Parenchymal echogenicity was naturally coarse and hypoechoic to the spleen. Vascular and biliary tracts were of normal volume with no evidence of congestion. The gallbladder presented acceptably thin walls with primarily anechoic content. The cystic and common bile ducts were normal. No pathological hepatic lymphadenopathy was evident. No overt structural evidence of inflammatory, infiltrative or regenerative pathology was evident.

**Gastrointestinal**

The **stomach** presented concentric wall thickening with loss of structural detail, measuring up to 1.0 cm wall thickness with pericapsular inflammatory pattern. An epigastric lymph node was slightly enlarged, measuring 1.5 cm x 0.60 cm. Other lymph nodes were mildly enlarged. The small intestine and colon were unremarkable.

**Pancreas**

The base and limbs of the **pancreas** were observed to be largely isoechoic to surrounding omental fat. Undulating contour noted. Some parenchymal remodeling, however, with mild deviation from curvilinear normalcy was observed. Pancreatic duct and capsular irregularities were present consistent with age related

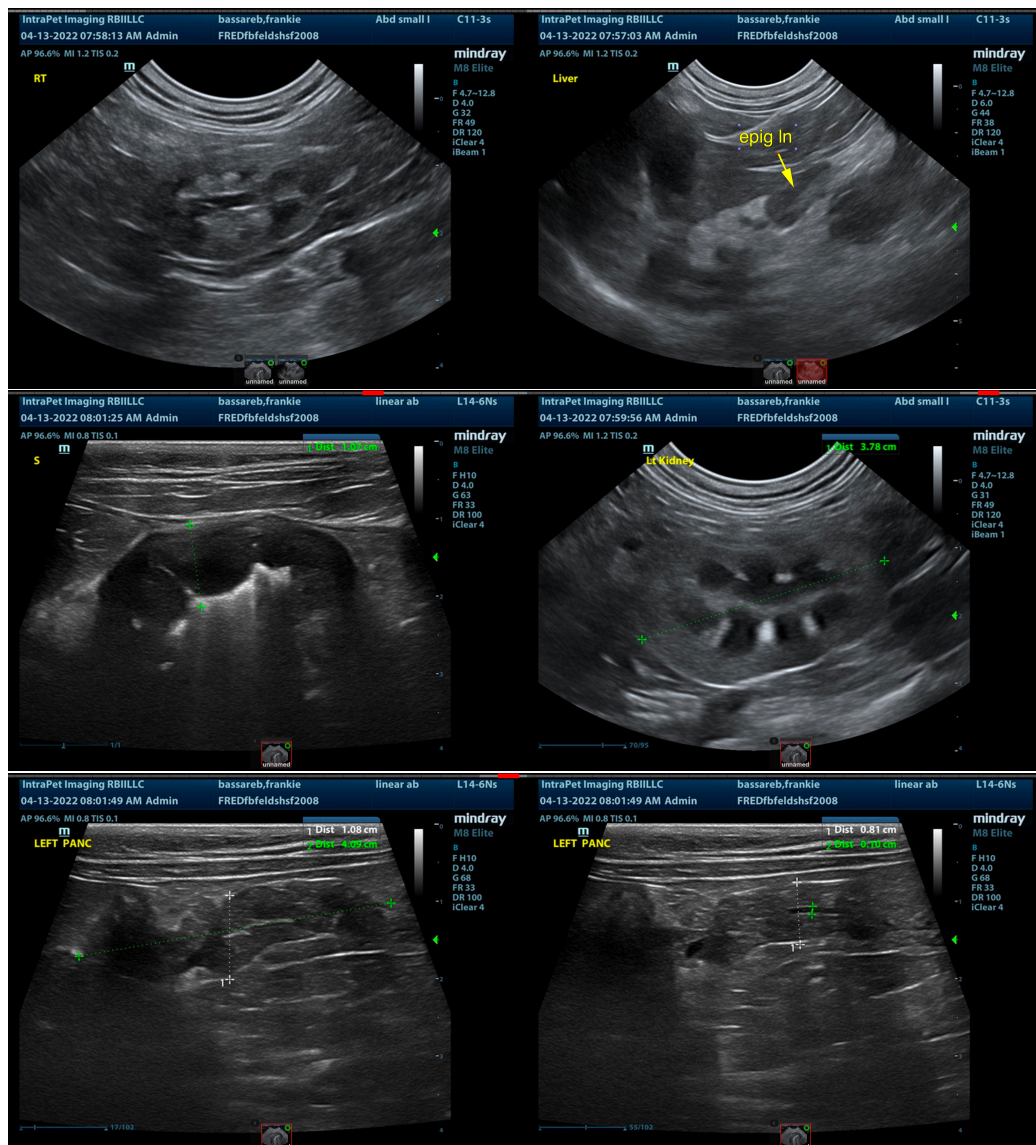
changes. If pain upon imaging (+ Murphy sign) was present or if the patient is focally painful in subxyphoid palpation then low-grade smoldering chronic pancreatitis should be suspected. The left limb measured 0.81 cm.

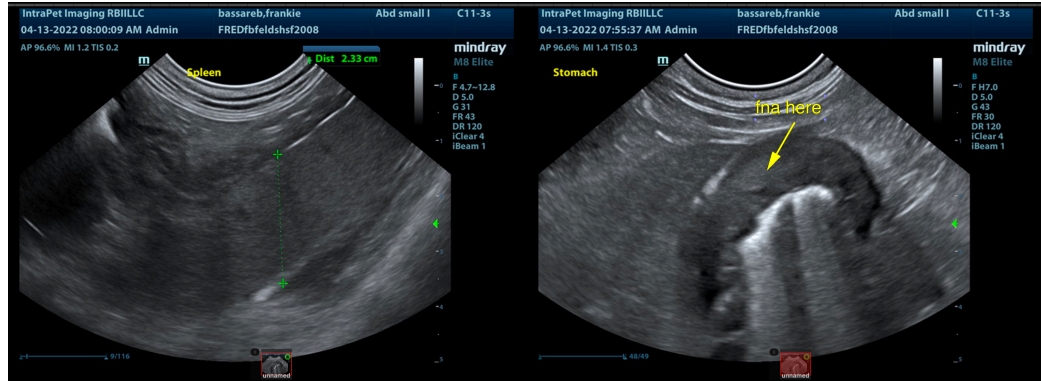
## ULTRASONOGRAPHIC FINDINGS

- Splenic and gastric infiltrative pattern – strongly suggestive for round cell neoplasia.
- Right renal dysplasia and mineralization

## INTERPRETATION OF THE FINDINGS & FURTHER RECOMMENDATIONS

Splenic and gastric FNAs indicated with immediate chemotherapeutic intervention.





The information and recommendations provided are based on the images presented by the referring veterinarian/sonographer. No evaluation can be communicated regarding pathology that was not visible in the image/video clips provided.

Thank you for this referral. If the clinical or image interpretation does not parallel your findings or if I can be of any further assistance please contact me.

Eric Lindquist, DMV, DABVP, Cert. IVUSS, CEO of SonoPath.com  
[info@SonoPath.com](mailto:info@SonoPath.com)