



PATIENT

Max Shipwash

SPECIES

Canine

BREED

Bichon Frise

SEX

Neutered male

AGE

6 years

WEIGHT

15 lbs

INTERPRETED BY

Eric Lindquist, DMV
DABVP, Cert. IVUSS

IMAGING PERFORMED BY

Jessica Green

HOSPITAL NAME

Stanglein VC

REFERRING VET

Dr. Stanglein

INVOICE

43831

DATE

4/12/23

PRESENTING CLINICAL SIGNS

History: A few week history of reduced appetite without vomiting/diarrhea or other compatible signs. Moderate dental disease but no difficulty chewing. No improvement in appetite when on gabapentin-prescribed for possible oral pain. Mild elevations in ALT, normal rads
Abnormal PE/Chem/CBC/UA Results: mild increase in ALT/AST; ALT 323

ULTRASONOGRAPHIC EXAMINATION OF THE ABDOMEN

Urinary System

The **urinary bladder** and visible pelvic urethra were unremarkable for the level of repletion presented. The urine, however, did present some mildly echogenic debris consistent with mucous, exfoliated cells from renal or bladder origin, and/or blood clots as these echogenic changes can all present similarly. This is often related to urinary tract infection but may represent simple evidence of exfoliated debris or sterile inflammation. Cystocentesis, urinalysis, +/- culture would be recommended to rule out and define any UTI.

The **kidneys** revealed normal size and structure, corticomedullary definition and ratio for this age. The cortices presented largely uniform texture with normal echogenic relationship to liver and spleen. Medullary structure differed distinctly from the cortex and no evidence of pelvic dilation was present. The capsules were acceptably uniform without significant irregularities. The right kidney measured 5.24 cm. The left kidney measured 5.02 cm.

Adrenal Glands

Both **adrenal glands** were visualized and recognized as having normal shape, size, position and echogenicity for this breed. The phrenic vasculature, glandular echogenicity and detail were unremarkable. Capsule, cortex, and medullary definition were normal for this age patient. The left adrenal gland is subnormal in size and measured 1.45 x 0.26 cm. The right adrenal gland measured 1.91 x 0.44 cm at the caudal pole and 0.6 cm at the cranial pole.

Spleen

The **spleen** presented a smooth homogeneous parenchyma hyperechoic to liver and renal cortical parenchyma. The capsule was smooth without noticeable expansion or deviation from within the spleen or adjacent pathology. The splenic vasculature demonstrated normal volume without signs of congestion or thrombosis. No sonographic evidence of acute or chronic inflammatory, neoplastic, or infarctual changes was noted.

Liver

The **liver** images submitted revealed subjectively normal liver size, contour, and structure. Parenchymal echogenicity was naturally coarse and hypoechoic to the spleen. Vascular and biliary tracts were of normal volume with no evidence of congestion. The gallbladder revealed a minor amount of debris. This is physiological.



PATIENT

Max Shipwash

SPECIES

Canine

BREED

Bichon Frise

SEX

Neutered male

AGE

6 years

WEIGHT

15 lbs

INTERPRETED BY

Eric Lindquist, DMV
DABVP, Cert. IVUSS

IMAGING PERFORMED BY

Jessica Green

HOSPITAL NAME

Stanglein VC

REFERRING VET

Dr. Stanglein

INVOICE

43831

DATE

4/12/23

Gastrointestinal

Examination of the **gastrointestinal tract** revealed a stomach and intestine free of stasis, of normal wall thickness, acceptable curvilinear mural detail, and peristaltic activity. Small and large intestine demonstrated normal luminal chyme and stool consistency respectively. No obstructive or overt infiltrative disease was noted. No associated abnormal lymphatic activity was noted.

Pancreas

The base and limbs of the **pancreas** were observed to be largely isoechoic to surrounding omental fat. Pancreatic duct and capsular contour were acceptably normal and parenchyma respected normal curvilinear patterns. No overt evidence of active inflammatory or neoplastic disease was noted.

ULTRASONOGRAPHIC FINDINGS

Structurally unremarkable abdomen with subjectively subnormal left adrenal size.

Bladder debris was noted.

INTERPRETATION OF THE FINDINGS & FURTHER RECOMMENDATIONS

The cause of poor appetite is not overtly evident. However, given the subnormal adrenal size and vague clinical signs baseline cortisol or ACTH stimulation is indicated. FNA of the liver can be considered to assess inflammatory cell type, yet structurally appears to be normal. This is likely reactive hepatopathy. Urinary work-up is warranted to assess for UTI if not already performed.

The hepatic clinical sonographic presentation is most consistent with Reactive Hepatopathy which is the most common cause of liver enzyme elevation in dogs and cats. The presumption is that gut and other organ antigen stimuli may be causing a low-grade immune response through portal system with which the liver is reacting to causing low-grade enzyme elevations. US-guided FNA could be performed to assess if low grade lymphoplasmacytic inflammation is present that would support this theory. If FNA is performed, please ask the cytologist to emphasize the primary inflammatory cell type. Empirical treatment measures to address this issue can include diet change to hydrolyzed diet, probiotics, deworming, nutraceuticals (SAME, Actigall...), dental exam and cleaning, and potentially antibiotics such as Clavamox. Metronidazole and Tylosin have traditionally been utilized for this purpose but new studies show that both these antibiotics can disrupt the normal intestinal bacterial flora (intestinal dysbiosis) for weeks and up to 4-6 months. Therefore, Metronidazole and Tylosin should be utilized as a last resort if other efforts have not been effective and sonographic organ appearance remains benign.



PATIENT

Max Shipwash

SPECIES

Canine

BREED

Bichon Frise

SEX

Neutered male

AGE

6 years

WEIGHT

15 lbs

INTERPRETED BY

Eric Lindquist, DMV
DABVP, Cert. IVUS

IMAGING PERFORMED BY

Jessica Green

HOSPITAL NAME

Stanglein VC

REFERRING VET

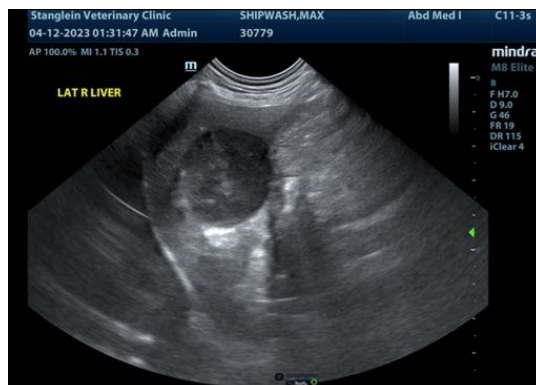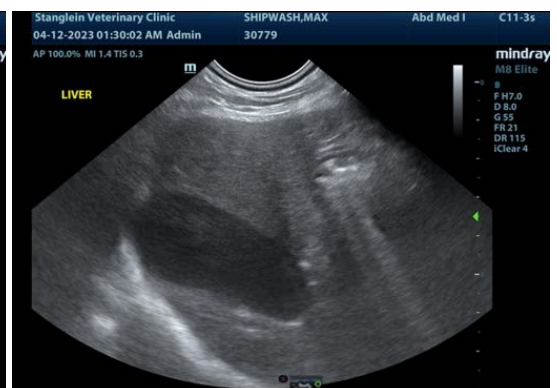
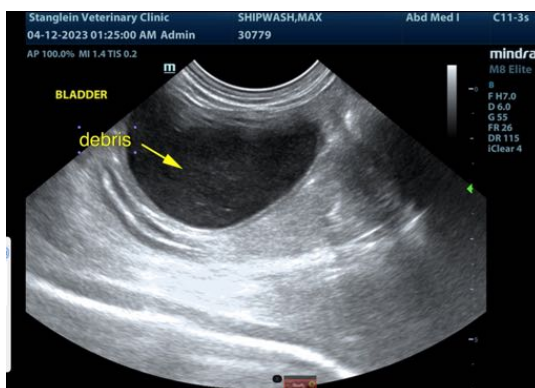
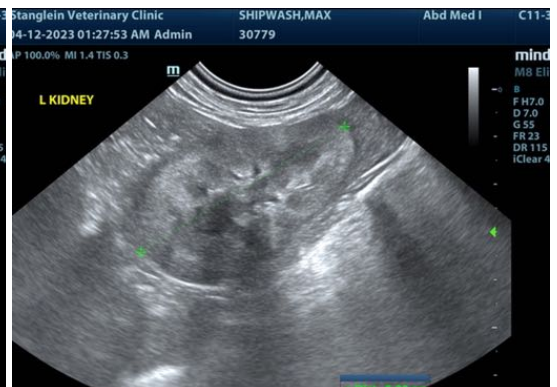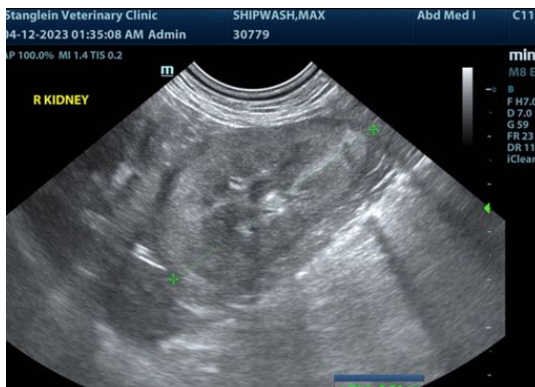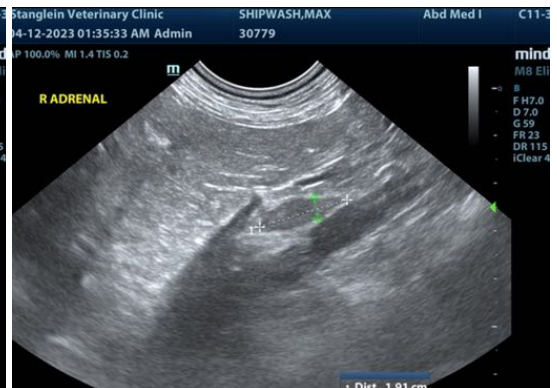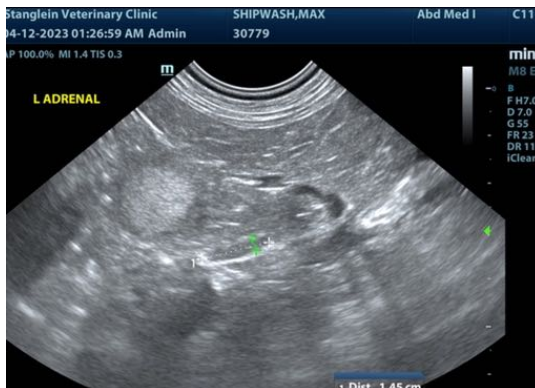Dr. Stanglein

INVOICE

43831

DATE

4/12/23





PATIENT

Max Shipwash

The information and recommendations provided are based on the images presented by the referring veterinarian/sonographer. No evaluation can be communicated regarding pathology that was not visible in the image/video clips provided.

SPECIES

Canine

Thank you for this referral. If the clinical or image interpretation does not parallel your findings or if I can be of any further assistance please contact me.

BREED

Bichon Frise

Eric Lindquist, DMV, DABVP, Cert. IVUSS, CEO of SonoPath.com
info@SonoPath.com

SEX

Neutered male

AGE

6 years

WEIGHT

15 lbs

INTERPRETED BY

Eric Lindquist, DMV
DABVP, Cert. IVUSS

**IMAGING
PERFORMED BY**

Jessica Green

HOSPITAL NAME

Stanglein VC

REFERRING VET

Dr. Stanglein

INVOICE

43831

DATE

4/12/23