



PATIENT

Reese McLean

SPECIES

Canine

BREED

Chihuahua X

SEX

Neutered Male

AGE

22 Months

WEIGHT

5.6 kg

INTERPRETED BY

Eric Lindquist, DMV

DABVP, Cert. IVUSS

IMAGING PERFORMED BY

Dr. Hayley Biederbeck

HOSPITAL NAME

Lomsnes Vet Hospital

REFERRING VET

Dr. Hayley Biederbeck

INVOICE

36838

DATE

4/12/22

PRESENTING CLINICAL SIGNS

Recheck GB, last time excessive debris and elevated ALT. On select protein diet now, didn't like hydrolyzed options

Abnormal PE/Chem/CBC/UA Results: ALT was 133 (10-125), now is 73 since starting ursodiol. Prev tested all other liver vals incl ggt and tbili and were normal

LIMITED ULTRASONOGRAPHIC EXAMINATION

Multiple images of the liver and gallbladder submitted.

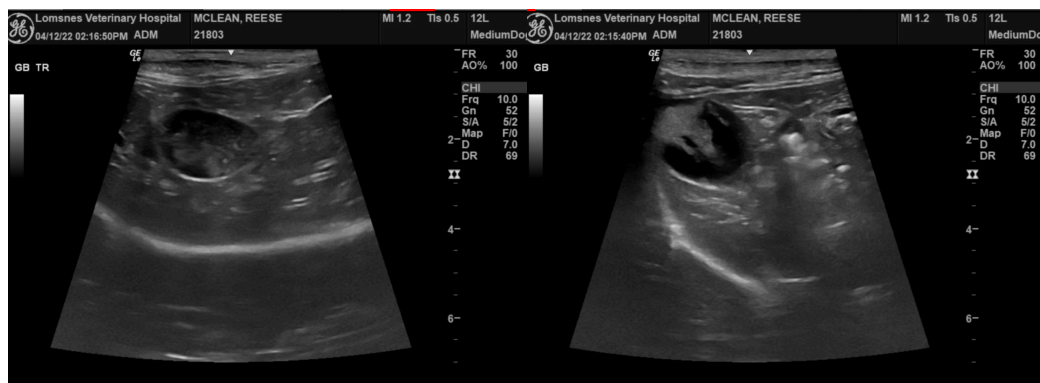
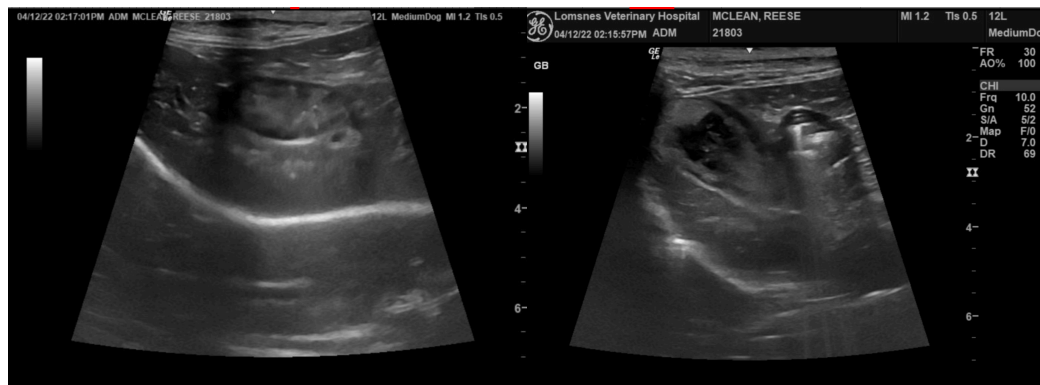
The gallbladder presented a minor amount of excessive debris with minor striation and minor overdistention, not to the level of mucocele formation. Liver parenchyma was uniform. The common bile duct was normal. No evidence of pathology.

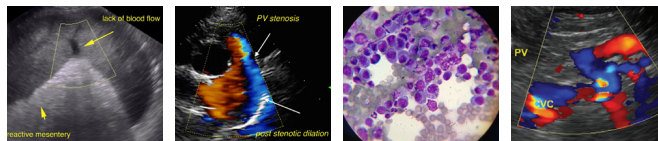
ULTRASONOGRAPHIC FINDINGS

- Minor excessive gallbladder debris – not overtly pathological, not likely causing any clinical signs at this time.

INTERPRETATION OF THE FINDINGS & FURTHER RECOMMENDATIONS

It's debatable on whether Ursodiol therapy is necessary in this patient, as the normal teardrop appearance appears to be maintained. If the gallbladder begins to start rounding with striating bile, Ursodiol therapy should be reinstated.





PATIENT

Reese McLean

The information and recommendations provided are based on the images presented by the referring veterinarian/sonographer. No evaluation can be communicated regarding pathology that was not visible in the image/video clips provided.

SPECIES

Canine

Thank you for this referral. If the clinical or image interpretation does not parallel your findings or if I can be of any further assistance please contact me.

Eric Lindquist, DMV, DABVP, Cert. IVUSS, CEO of SonoPath.com

info@SonoPath.com

BREED

Chihuahua X

SEX

Neutered Male

AGE

22 Months

WEIGHT

5.6 kg

INTERPRETED BY

Eric Lindquist, DMV

DABVP, Cert. IVUSS

IMAGING PERFORMED BY

Dr. Hayley Biederbeck

HOSPITAL NAME

Lomsnes Vet Hospital

REFERRING VET

Dr. Hayley Biederbeck

INVOICE

36838

DATE

4/12/22