



PATIENT

Princess Barrios

PRESENTING CLINICAL SIGNS

History: Choc. toxicity, ate toothpicks. Elevated GGT.

SPECIES

Canine

ULTRASONOGRAPHIC EXAMINATION OF THE ABDOMEN

Urinary System

BREED

Pomeranian

The **urinary bladder**, trigone, and pelvic urethra presented normal thicknesses and normal tone. The ureters were not visible which is normal. No uroliths or sediment were visualized and anechoic urine was present. No evidence of inflammatory or neoplastic changes was noted. Ureteral papillae were normal.

SEX

Female

The **kidneys** revealed normal size and structure, corticomedullary definition and ratio for this age. The cortices presented largely uniform texture with normal echogenic relationship to liver and spleen. Medullary structure differed distinctly from the cortex and no evidence of pelvic dilation was present. The capsules were acceptably uniform without significant irregularities. The right kidney measured 2.63 cm. The left kidney measured 3.0 cm.

AGE

1 year

WEIGHT

6.8 lbs

Adrenal Glands

Both **adrenal glands** were visualized and recognized as having normal shape, size, position and echogenicity for this breed. The phrenic vasculature, glandular echogenicity and detail were unremarkable. Capsule, cortex, and medullary definition were normal for this age patient. The right adrenal gland measured 1.09 x 1.07 cm at the cranial pole and 0.45 cm at the caudal pole. The left adrenal gland measured 1.27 x 0.33 cm at the cranial pole and 0.3 cm at the caudal pole.

INTERPRETED BY

Eric Lindquist, DMV
DABVP, Cert. IVUSS

Spleen

The **spleen** presented a smooth homogeneous parenchyma hyperechoic to liver and renal cortical parenchyma. The capsule was smooth without noticeable expansion or deviation from within the spleen or adjacent pathology. The splenic vasculature demonstrated normal volume without signs of congestion or thrombosis. No sonographic evidence of acute or chronic inflammatory, neoplastic, or infarctual changes was noted.

IMAGING PERFORMED BY

Shari Reffi, CVT

HOSPITAL NAME

Rockaway AH

REFERRING VET

Dr. Maniar

Liver

The **liver** images submitted revealed subjectively normal liver size, contour, and structure. Parenchymal echogenicity was naturally coarse and hypoechoic to the spleen. Vascular and biliary tracts were of normal volume with no evidence of congestion. The gallbladder presented acceptably thin walls with primarily anechoic content. The cystic and common bile ducts were normal. No pathological hepatic lymphadenopathy was evident. No overt structural evidence of inflammatory, infiltrative or regenerative pathology was evident.

INVOICE

99231

DATE

4/12/22



PATIENT

Gastrointestinal

Princess Barrios

The **gastrointestinal tract** revealed an edematous wall and hyperperistalsis with no loss of mural detail. Minor enhanced surrounding fat was noted around the regions of the gastrointestinal serosa. There was no evidence of foreign body or neoplastic criteria. Images from the stomach, small intestine and colon were presented. This is most consistent with gastroenteritis owing to viral, bacterial/endotoxin or possible parasitic disease.

SPECIES

Canine

BREED

Pancreas

Pomeranian

The base and limbs of the **pancreas** were observed to be largely isoechoic to surrounding omental fat. Pancreatic duct and capsular contour were acceptably normal and parenchyma respected normal curvilinear patterns. No overt evidence of active inflammatory or neoplastic disease was noted.

SEX

Female

ULTRASONOGRAPHIC FINDINGS

AGE

Non-specific gastroenteritis.

1 year

INTERPRETATION OF THE FINDINGS & FURTHER RECOMMENDATIONS

WEIGHT

There was no evidence of foreign bodies.

6.8 lbs

INTERPRETED BY

Eric Lindquist, DMV
DABVP, Cert. IVUSS

IMAGING PERFORMED BY

Shari Reffi, CVT

HOSPITAL NAME

Rockaway AH

REFERRING VET

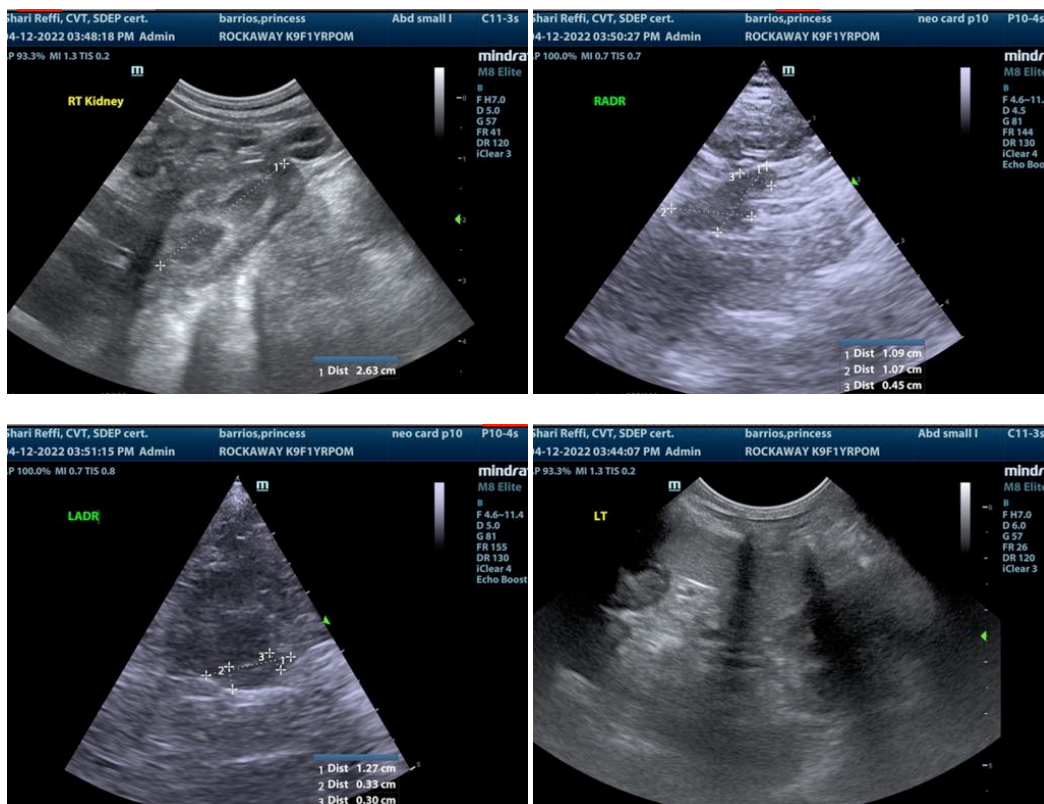
Dr. Maniar

INVOICE

99231

DATE

4/12/22





PATIENT

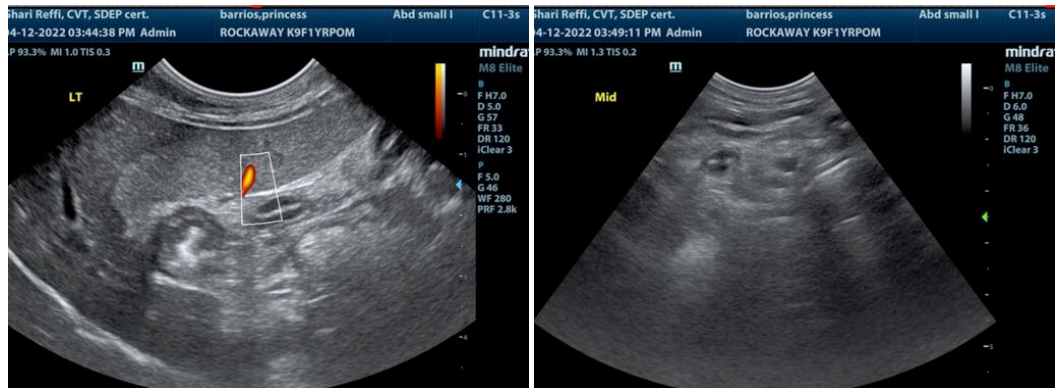
Princess Barrios

SPECIES

Canine

BREED

Pomeranian



SEX

Female

AGE

1 year

WEIGHT

6.8 lbs

INTERPRETED BY

Eric Lindquist, DMV
DABVP, Cert. IVUSS

IMAGING PERFORMED BY

Shari Reffi, CVT

HOSPITAL NAME

Rockaway AH

REFERRING VET

Dr. Maniar

INVOICE

99231

DATE

4/12/22

The information and recommendations provided are based on the images presented by the referring veterinarian/sonographer. No evaluation can be communicated regarding pathology that was not visible in the image/video clips provided.

Thank you for this referral. If the clinical or image interpretation does not parallel your findings or if I can be of any further assistance please contact me.

Eric Lindquist, DMV, DABVP, Cert. IVUSS, CEO of SonoPath.com
Info@SonoPath.com