



PATIENT

Oliver Mason

SPECIES

Canine

BREED

Cairn Terrier

SEX

Neutered male

AGE

15 years

WEIGHT

17.1 lbs

INTERPRETED BY

Eric Lindquist, DMV
DABVP, Cert. IVUSS

IMAGING PERFORMED BY

Dr. Schneck

HOSPITAL NAME

Willamette VH

REFERRING VET

Dr. Schneck

INVOICE

99225

DATE

4/12/22

PRESENTING CLINICAL SIGNS

History: -Presented for shaking in FL and unspecific pain. Historic liver mass diagnosed about 9 months ago.
-PE: abdominal pain. Chem: ALT 161, ALP 611 CBC: NSF CPL: abnormal Radiographs body/chest to be taken Dx: Pancreatitis r/o concurrent disease -Historic liver mass r/o extent and other organ involvement

ULTRASONOGRAPHIC EXAMINATION OF THE ABDOMEN

Urinary System

The **urinary bladder**, trigone, and pelvic urethra presented normal thicknesses and normal tone. The ureters were not visible which is normal. No uroliths or sediment were visualized and anechoic urine was present. No evidence of inflammatory or neoplastic changes was noted. Ureteral papillae were normal.

The **kidneys** revealed largely normal size and structure, corticomedullary definition and ratio (cortex 1/3 of medulla) were essentially maintained with some age-related loss of curvilinear patterns regarding the capsule and C/M junction. The cortices presented largely uniform texture with some increased echogenicity expected for this age patient. Medullary structure differed distinctly from that of the cortex. The left kidney measured 4.66 cm with slight pyelectasia. The right kidney measured 5.21 cm.

Adrenal Glands

Both **adrenal glands** were visualized and recognized as having normal shape, size, position and echogenicity for this breed. The phrenic vasculature, glandular echogenicity and detail were unremarkable. Capsule, cortex, and medullary definition were normal for this age patient. The left adrenal gland measured 0.5 cm.

Spleen

The **spleen** presented a smooth homogeneous parenchyma hyperechoic to liver and renal cortical parenchyma. The capsule was smooth without noticeable expansion or deviation from within the spleen or adjacent pathology. The splenic vasculature demonstrated normal volume without signs of congestion or thrombosis. No sonographic evidence of acute or chronic inflammatory, neoplastic, or infarctual changes was noted.

Liver

The **liver** revealed increased portal markings with multi-focal, hypoechoic nodular changes. The gallbladder revealed an echogenic wall with multiple calculi.

Gastrointestinal

The **stomach** in this patient revealed a 3.0 cm, hypoechoic mural mass. The mass occupied the pyloric outflow. The small intestines and colon were unremarkable.



PATIENT

Pancreas

Oliver Mason

The **pancreas** was heterogenous with mixed, hyperechoic parenchymal changes. This is consistent with remodeling.

SPECIES

Canine

ULTRASONOGRAPHIC FINDINGS

Pyloric/gastric mass.

BREED

Cairn Terrier

Nodular hepatic changes, possibly metastatic. Chronic cholangitis with gallbladder calculi.

Age related renal changes with slight pyelectasia.

SEX

Neutered male

INTERPRETATION OF THE FINDINGS & FURTHER RECOMMENDATIONS

FNA of the gastric mass or endoscopy or surgical biopsies are indicated. FNA of the liver is also indicated to assess for metastatic disease. Gastric carcinoma versus gastrinoma are the primary concerns.

AGE

15 years

WEIGHT

17.1 lbs

INTERPRETED BY

Eric Lindquist, DMV
DABVP, Cert. IVUSS

IMAGING PERFORMED BY

Dr. Schneck

HOSPITAL NAME

Willamette VH

REFERRING VET

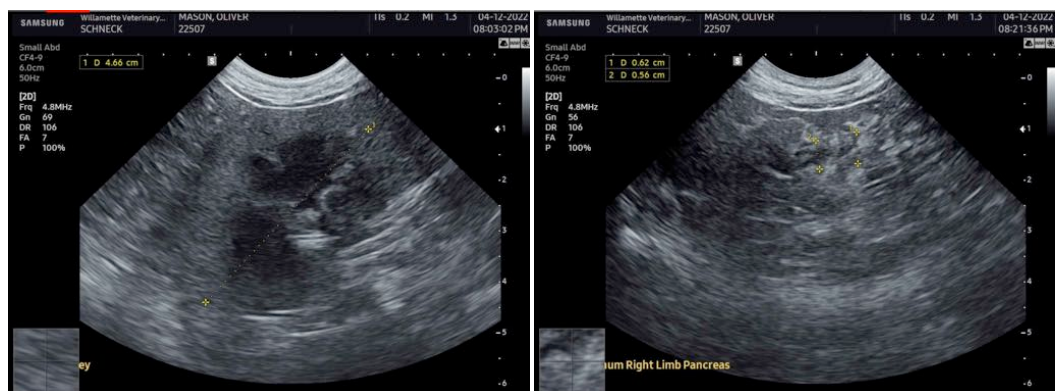
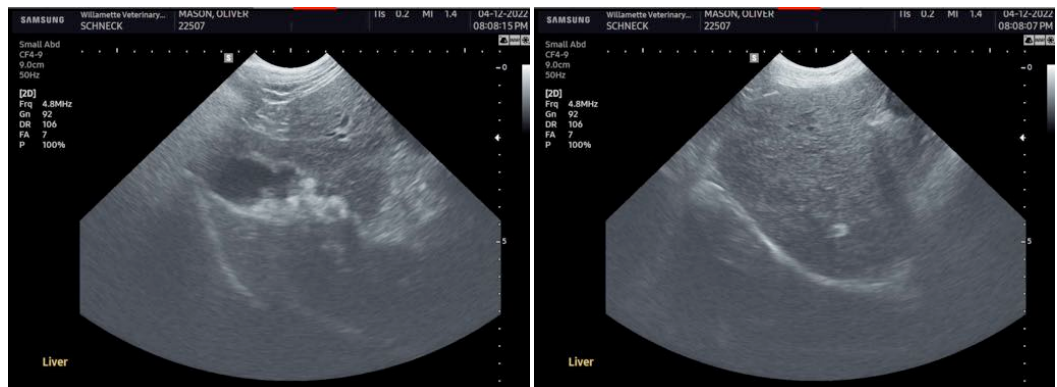
Dr. Schneck

INVOICE

99225

DATE

4/12/22





PATIENT

Oliver Mason

SPECIES

Canine

BREED

Cairn Terrier

SEX

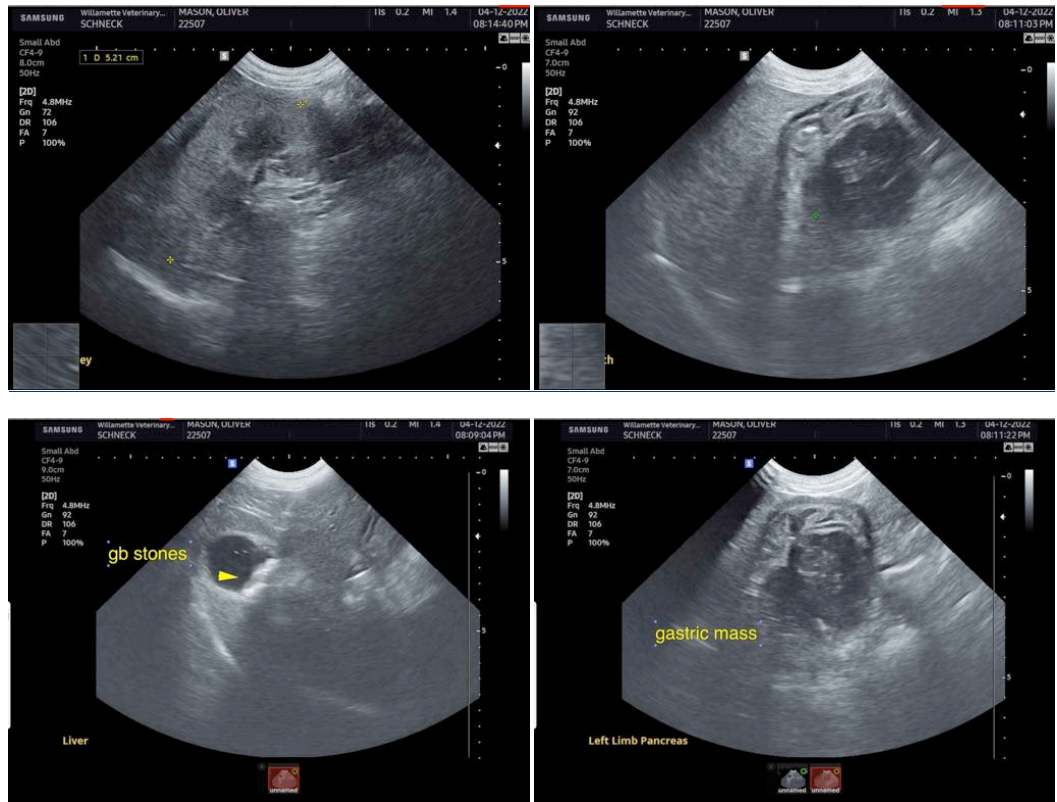
Neutered male

AGE

15 years

WEIGHT

17.1 lbs



INTERPRETED BY

Eric Lindquist, DMV
DABVP, Cert. IVUSS

IMAGING PERFORMED BY

Dr. Schneck

HOSPITAL NAME

Willamette VH

REFERRING VET

Dr. Schneck

INVOICE

99225

DATE

4/12/22

The information and recommendations provided are based on the images presented by the referring veterinarian/sonographer. No evaluation can be communicated regarding pathology that was not visible in the image/video clips provided.

Thank you for this referral. If the clinical or image interpretation does not parallel your findings or if I can be of any further assistance please contact me.

Eric Lindquist, DMV, DABVP, Cert. IVUSS, CEO of SonoPath.com
info@SonoPath.com