



PATIENT

Milo Belina

SPECIES

Feline

BREED

DSH

SEX

Neutered Male

AGE

6 Months

WEIGHT

8.36 Pounds

PRESENTING CLINICAL SIGNS

Milo was diagnosed with a grade 3 murmur when he was first presented for his kitten exams. Murmur has not changed over time. Owner wants to pursue surgery and anesthetic risk is being evaluated prior to surgery.

ULTRASONOGRAPHIC EXAMINATION OF THE HEART

FELINE CARDIAC PARAMETERS	BODY WEIGHT (kg)	HR (BPM)	IVSd (cm)	LVIDd (cm)	LVWd (cm)	FS (%)	EF (%)
NORMAL PARAMETER	-----	150-240	0.3-0.6	1.0-2.1	0.25-0.6	35-67	80-100
PATIENT		NM	0.48	1.51	0.29	54	87
FELINE CARDIAC PARAMETERS	LA/AO (Boon)	LA/AO HEART BASE (Sisson)	LA 2D 4-chamber long axis AS to FW (Sisson) (cm)		LVOT VEL. (m/s)	RVOT VEL. (m/s)	IVRT (m/)
NORMAL PARAMETER	<1.5	0.88-1.79	0.7-1.7		<1.6	<1.3	40-60
PATIENT		1.2			1.4		NM
Adapted from June Boon, Veterinary Echocardiography, 1998 Sisson D et al. JVIM 1991; 5: 232, Jacobs et al. Am J Vet Res 1985; 46:1705							

INTERPRETED BY

Eric Lindquist, DMV

DABVP, Cert. IVUSS

IMAGING PERFORMED BY

Dr. Becky Meier Gast

HOSPITAL NAME

Meier Vet Clinic

REFERRING VET

Dr. Becky Meier Gast

Cardiac Presentation

The echocardiogram in this patient demonstrated normal **left atrial** size based on 3 separate LA measurements. The cranial and caudal **mitral** valve leaflets presented normal linear structure and kinetics.. The **left ventricle** presented normal thicknesses with linear contour and was not dilated nor restricted. The **myocardium** presented normal echogenicity without subjective evidence of significant fibrotic or ischemic disease. **Contractility** of the ventricular walls was adequate and in normal range for this patient evidenced by the fractional shortening measurement and subjective evaluation of the different regions and angles of the myocardium. The **left ventricular outflow** tract demonstrated normal laminar flow and subjective structural integrity. **Right atrial** size was mildly excessive with a 1:1 ratio with the left atrium. No evidence of pulmonic stenosis. Trivial **tricuspid** insufficiency present. The **right ventricle** was of normal size (1/3 diameter of LV), chordae structure, myocardial echogenicity and thickness. **Pulmonic** tract assessment revealed normal valve structure, laminar flow, and diameter (approx. 1:1 pa/ao ratio). No visible **pericardial** or free pleura fluid was noted or extra cardiac pathology in the visible planes. The cranial **mediastinum and pericardial regions** were free of masses in the visible window.

ULTRASONOGRAPHIC FINDINGS

- Minor tricuspid insufficiency
- Prominent right atrium

INTERPRETATION OF THE FINDINGS & FURTHER RECOMMENDATIONS

No evidence of significant disease. Essentially flow murmur. No cardiac dysfunction. No overt anesthetic risk in this patient. Torbutrol pre-med, Propofol induction, Isoflurane maintenance.

INVOICE

36834

DATE

4/12/22



PATIENT

Milo Belina

SPECIES

Feline

BREED

DSH

SEX

Neutered Male

AGE

6 Months

WEIGHT

8.36 Pounds

INTERPRETED BY

Eric Lindquist, DMV

DABVP, Cert. IVUSS

IMAGING PERFORMED BY

Dr. Becky Meier Gast

HOSPITAL NAME

Meier Vet Clinic

REFERRING VET

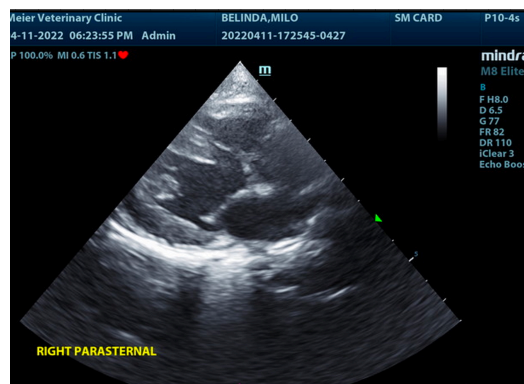
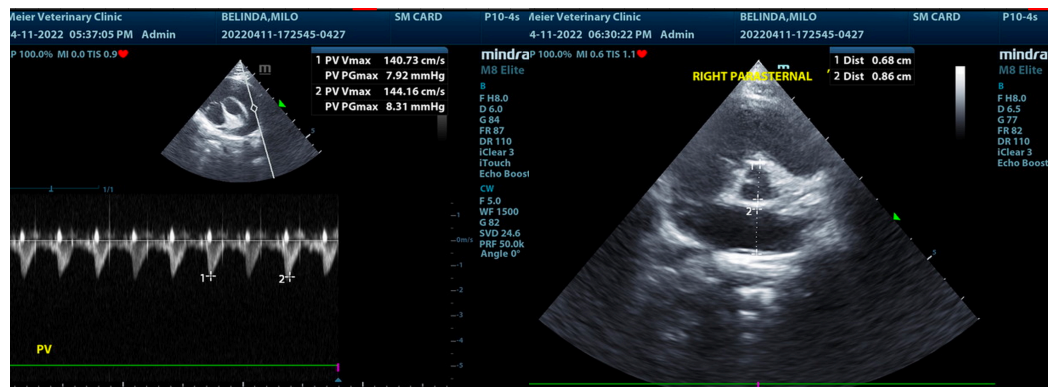
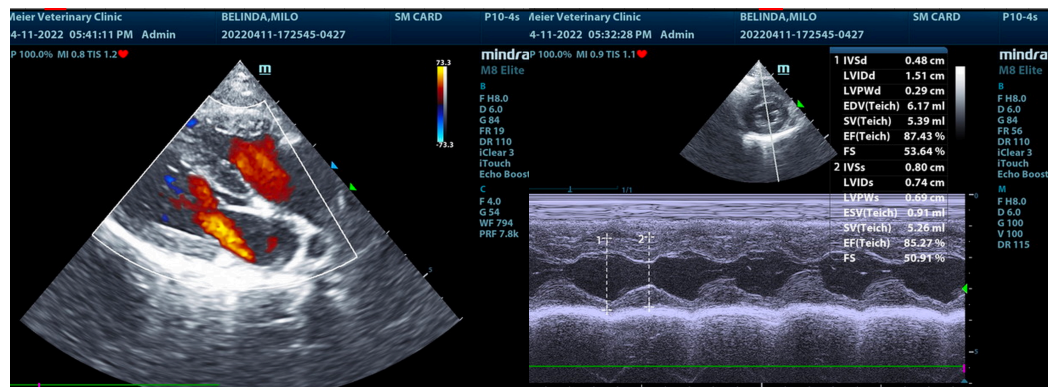
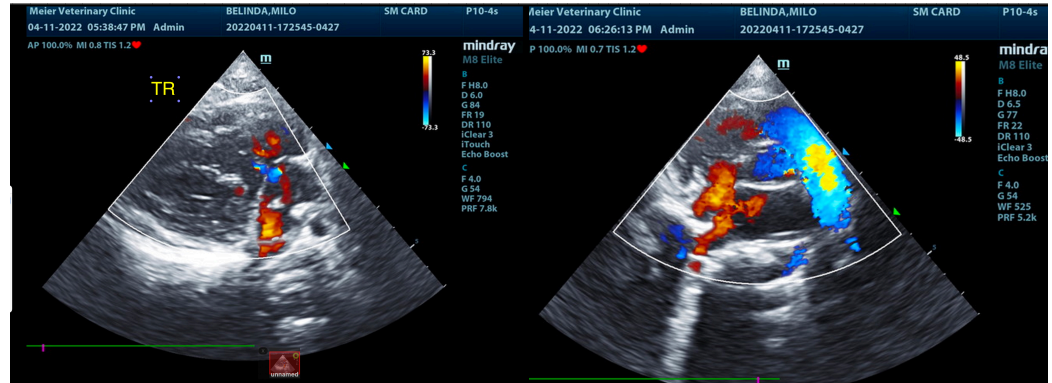
Dr. Becky Meier Gast

INVOICE

36834

DATE

4/12/22





PATIENT

Milo Belina

The information and recommendations provided are based on the images presented by the referring veterinarian/sonographer. No evaluation can be communicated regarding pathology that was not visible in the image/video clips provided.

SPECIES

Feline

Thank you for this referral. If the clinical or image interpretation does not parallel your findings or if I can be of any further assistance please contact me.

Eric Lindquist, DMV, DABVP, Cert. IVUSS, CEO of SonoPath.com

BREED

DSH

info@SonoPath.com

SEX

Neutered Male

AGE

6 Months

WEIGHT

8.36 Pounds

INTERPRETED BY

Eric Lindquist, DMV

DABVP, Cert. IVUSS

IMAGING PERFORMED BY

Dr. Becky Meier Gast

HOSPITAL NAME

Meier Vet Clinic

REFERRING VET

Dr. Becky Meier Gast

INVOICE

36834

DATE

4/12/22