



PATIENT PRESENTING CLINICAL SIGNS

Kaiser Elliott History: Mast cell tumor on the scrotum Chronic heart disease patient
 Abnormal PE/Chem/CBC/UA Results: PE: Grade III/VI murmur with exercise intolerance 0.3 x 0.5 cm mast cell tumor in scrotal area Rads: Enlarged heart, enlarged liver, irregular spleen, loss of detail in central abdomen CBC: WNL CHEM: ALKP 359

SPECIES

Canine

ULTRASONOGRAPHIC EXAMINATION OF THE ABDOMEN

BREED

Urinary System

Pit Bull

The **urinary bladder**, trigone, and pelvic urethra presented normal thicknesses and normal tone. The ureters were not visible which is normal. No uroliths or sediment were visualized and anechoic urine was present. No evidence of inflammatory or neoplastic changes was noted. Ureteral papillae were normal.

SEX

Neutered male

AGE

12 years

The **kidneys** revealed largely normal size and structure, corticomedullary definition and ratio (cortex 1/3 of medulla) were essentially maintained with some age-related loss of curvilinear patterns regarding the capsule and C/M junction. The cortices presented largely uniform texture with some increased echogenicity expected for this age patient. Medullary structure differed distinctly from that of the cortex and no evidence of pelvic dilation was present. The kidneys measured 6.0 cm each.

WEIGHT

75 lbs

Adrenal Glands

INTERPRETED BY

Eric Lindquist, DMV DABVP, Cert. IVUSS

The left **adrenal gland** was visualized and recognized as having normal shape, size, position and echogenicity for this breed. The phrenic vasculature, glandular echogenicity and detail were unremarkable. Capsule, cortex, and medullary definition were normal for this age patient. The left adrenal gland measured 0.6 cm. The right adrenal gland was not visualized.

IMAGING PERFORMED BY

Dr. Griffin

Spleen

HOSPITAL NAME

Northside VH

The **spleen** revealed a mixed, hypoechoic 3.0 cm mass. A separate splenic mass was noted and measured 4.0 cm in the midbody.

REFERRING VET

Dr. Griffin

Liver

The **liver** presented minor, hypoechoic nodular changes in the left limb. The gallbladder presented acceptably thin walls with primarily anechoic content. The cystic and common bile ducts were normal. No pathological hepatic lymphadenopathy was evident.

INVOICE

99234

Gastrointestinal

DATE

4/12/22

Examination of the **gastrointestinal tract** revealed a stomach and intestine free of stasis, of normal wall thickness, acceptable curvilinear mural detail, and peristaltic activity. Small and large intestine demonstrated normal luminal chyme and stool consistency respectively. No obstructive or overt infiltrative disease was noted. No associated abnormal lymphatic activity was noted.



PATIENT

Pancreas

Kaiser Elliott

A 3.0 cm, mixed echogenic mass was noted and appeared to be deriving from the **pancreas**.

SPECIES

Canine

ULTRASONOGRAPHIC FINDINGS

Two separate splenic masses.

BREED

Pit Bull

Third mass, likely deriving from the pancreas.

Heterogenous hepatic changes.

SEX

Neutered male

INTERPRETATION OF THE FINDINGS & FURTHER RECOMMENDATIONS

The tumors are not typical for mast cell tumors. I recommend FNA for screening and oncological evaluation. If the liver is not involved then the abdominal lesions appear to be potentially resectable with splenectomy and tumor removal around the left limb of the pancreas.

AGE

12 years

WEIGHT

75 lbs

INTERPRETED BY

Eric Lindquist, DMV
DABVP, Cert. IVUSS

IMAGING PERFORMED BY

Dr. Griffin

HOSPITAL NAME

Northside VH

REFERRING VET

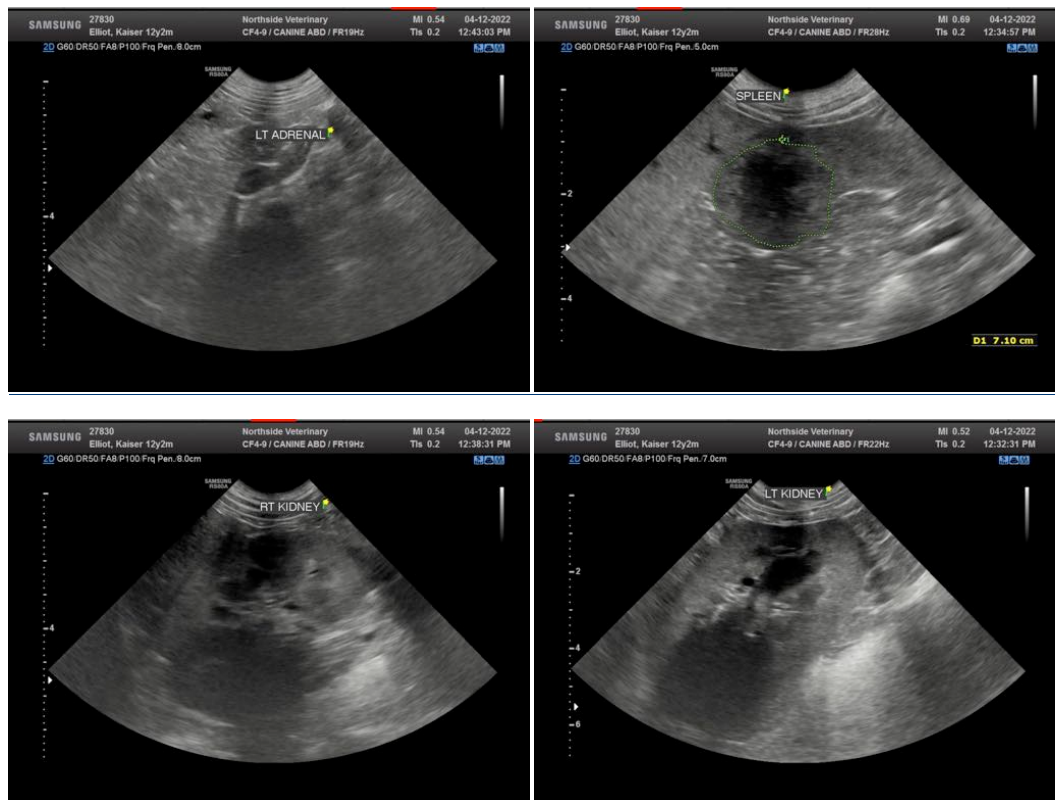
Dr. Griffin

INVOICE

99234

DATE

4/12/22





PATIENT

Kaiser Elliott

SPECIES

Canine

BREED

Pit Bull

SEX

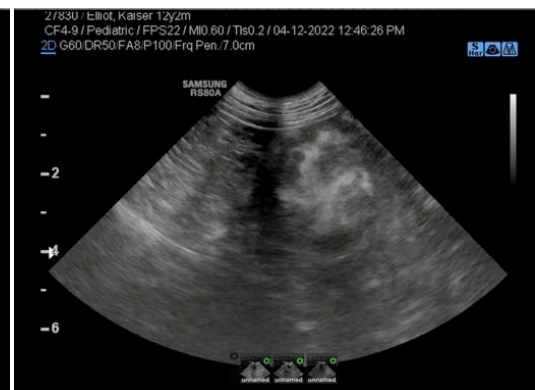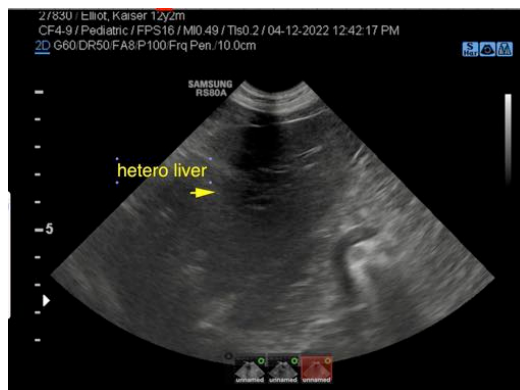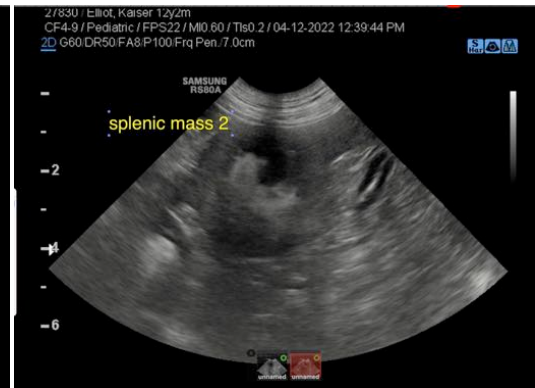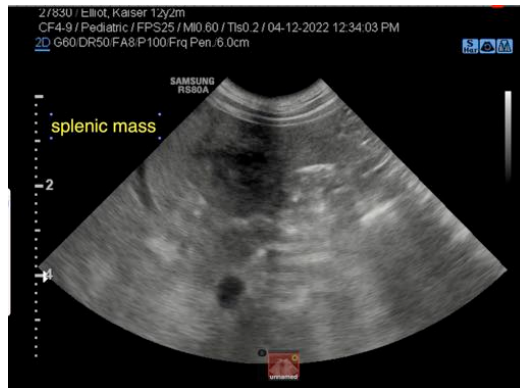Neutered male

AGE

12 years

WEIGHT

75 lbs



INTERPRETED BY

Eric Lindquist, DMV
DABVP, Cert. IVUSS

IMAGING PERFORMED BY

Dr. Griffin

HOSPITAL NAME

Northside VH

REFERRING VET

Dr. Griffin

INVOICE

99234

DATE

4/12/22

The information and recommendations provided are based on the images presented by the referring veterinarian/sonographer. No evaluation can be communicated regarding pathology that was not visible in the image/video clips provided.

Thank you for this referral. If the clinical or image interpretation does not parallel your findings or if I can be of any further assistance please contact me.

Eric Lindquist, DMV, DABVP, Cert. IVUSS, CEO of SonoPath.com
info@SonoPath.com