

**PATIENT**

May Kim

**SPECIES**

Canine

**BREED**

Siberian Husky

**SEX**

Female

**AGE**

13 Years

**WEIGHT**

45.9 pounds

**INTERPRETED BY**

Eric Lindquist, DMV,  
DABVP(CFM), Cert.  
IVUS

**IMAGING PERFORMED BY**

Dr. Han

**HOSPITAL NAME**

Tenafly Vet Center

**REFERRING VET**

Dr. Han

**INVOICE**

15021

**DATE**

04/11/26

**PRESENTING CLINICAL SIGNS**

May - 13 yr old SF . She is sedated with Torbu( 0.2mg/kg/IV) and Alfaxan( 2mg/ kg/ im) 10 minutes prior to the echocardiogram. NO heart murmur nor arrhythmia are noted during exam . Slight elevation of cardioprobnp( 1001) . She was panting while blood pressure was checking. Systolic bp: 190 .

**LIMITED ULTRASONOGRAPHIC EXAMINATION**

**Liver**

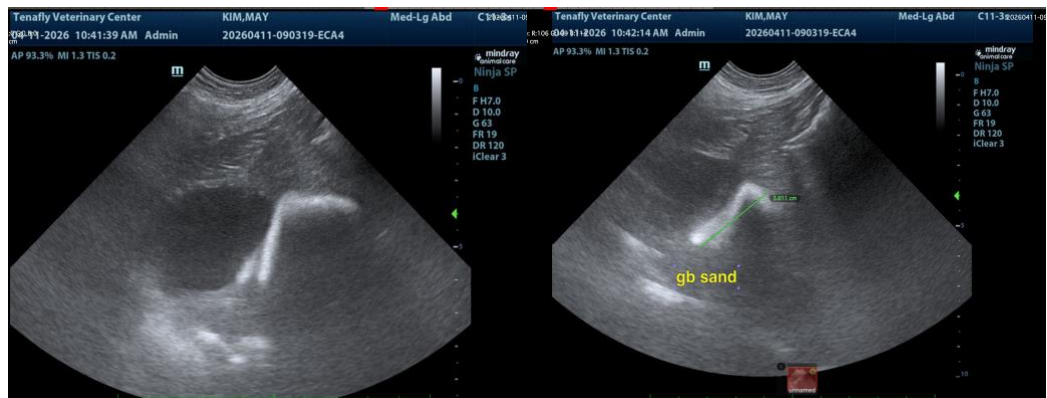
The **liver** images from right and left intercostal as well as subcostal views revealed subjectively normal liver size, contour, and structure. Some age-related parenchymal remodeling was noted but likely not clinically significant at this time. Vascular and biliary tracts were of normal volume and no evidence of congestion was noted. The cystic and common bile ducts were normal. No overt evidence of active inflammatory, infiltrative or regenerative pathology was noted but should be paired with current or past LE elevations regarding any clinical significance to this presentation. The hepatic lymph nodes were unremarkable. The gallbladder revealed a mild/moderate amount of sand and calculi accumulation and appeared nonobstructive measuring 3.0 cm.

**ULTRASONOGRAPHIC FINDINGS**

- Gallbladder sand/calculi- nonobstructive at this time.
- Hepatic remodeling.

**INTERPRETATION OF THE FINDINGS & FURTHER RECOMMENDATIONS**

Ursodiol over the next 6-8 week period and recheck sonogram could be considered. No evidence of gallbladder inflammation at this time.





## PATIENT

May Kim

## SPECIES

Canine

## BREED

Siberian Husky

## SEX

Female

## AGE

13 Years

## WEIGHT

45.9 pounds

## INTERPRETED BY

Eric Lindquist, DMV,  
DABVP(CFM), Cert.  
IVUSS

## IMAGING PERFORMED BY

Dr. Han

## HOSPITAL NAME

Tenafly Vet Center

## REFERRING VET

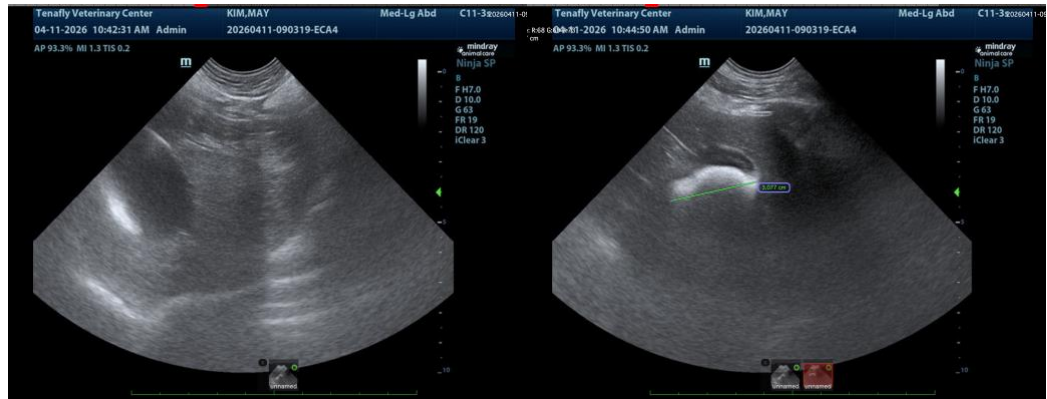
Dr. Han

## INVOICE

15021

## DATE

04/11/26



The information and recommendations provided are based on the images presented by the referring veterinarian/sonographer. No evaluation can be communicated regarding pathology that was not visible in the image/video clips provided.

Thank you for this referral. If the clinical or image interpretation does not parallel your findings or if I can be of any further assistance, please contact me.

**Eric Lindquist, DMV, DABVP(CFM), Cert. IVUSS,**

CEO, Owner, Founder -- SonoPath.com

[info@SonoPath.com](mailto:info@SonoPath.com)