



PATIENT

Tim Hartzell

SPECIES

Feline

BREED

Domestic Shorthair

SEX

Neutered male

AGE

5 years

WEIGHT

13.5 lbs

INTERPRETED BY

Eric Lindquist, DMV
DABVP, Cert. IVUS

IMAGING PERFORMED BY

JK

HOSPITAL NAME

Hamburg VC

REFERRING VET

Dr. Shaw

PRESENTING CLINICAL SIGNS

History: Grade 2-3/6 murmur. Unstable at home, falling to left side
Abnormal PE/Chem/CBC/UA Results: Blood pending

ULTRASONOGRAPHIC EXAMINATION OF THE HEART

The echocardiogram in this patient demonstrated normal **left atrial** size based on 3 separate LA measurements. The cranial and caudal **mitral** valve leaflets presented normal linear structure and kinetics. The **left ventricle** presented normal thicknesses with linear contour and was not dilated nor restricted. The **myocardium** presented normal echogenicity without subjective evidence of significant fibrotic or ischemic disease. **Contractility** of the ventricular walls was adequate and in normal range for this patient evidenced by the fractional shortening measurement and subjective evaluation of the different regions and angles of the myocardium. The **left ventricular outflow** tract demonstrated normal laminar flow and subjective structural integrity. The **right atrium** and auricle revealed normal size, structure and content. No evidence of masses was noted or chamber overload. **Tricuspid** valvular assessment demonstrated adequate linear morphology and kinetics. The **right ventricle** was of normal size (1/3 diameter of LV), chordae structure, myocardial echogenicity and thickness. **Pulmonic** tract assessment revealed normal valve structure, laminar flow, and diameter (approx. 1:1 pa/ao ratio). No visible **pericardial** or free pleura fluid was noted or extra cardiac pathology in the visible planes. The cranial **mediastinum and pericardial regions** were free of masses in the visible window.

FELINE CARDIAC PARAMETERS	BODY WEIGHT (kg)	HR (BPM)	IVSd (cm)	LVIDd (cm)	LWVd (cm)	FS (%)	EF (%)
NORMAL PARAMETER	-----	150-240	0.3-0.6	1.0-2.1	0.25-0.6	35-67	80-100
PATIENT		114		1.35	0.53	40	75
FELINE CARDIAC PARAMETERS	LA/AO (Boon)	LA/AO HEART BASE (Sisson)	LA 2D 4-chamber long axis AS to FW (Sisson) (cm)		LVOT VEL. (m/s)	RVOT VEL. (m/s)	IVRT (m)
NORMAL PARAMETER	<1.5	0.88-1.79	0.7-1.7		<1.6	<1.3	40-60
PATIENT	1.46	1.5	1.3 max			0.93	NM
Adapted from June Boon, Veterinary Echocardiography, 1998 Sisson D et al. JVIM 1991; 5: 232, Jacobs et al. Am J Vet Res 1985; 46:1705							

INVOICE

43800

DATE

4/11/23

ULTRASONOGRAPHIC FINDINGS

Normal echocardiogram.



PATIENT

Tim Hartzell

SPECIES

Feline

BREED

Domestic Shorthair

SEX

Neutered male

AGE

5 years

WEIGHT

13.5 lbs

INTERPRETED BY

Eric Lindquist, DMV
DABVP, Cert. IVUSS

IMAGING PERFORMED BY

JK

HOSPITAL NAME

Hamburg VC

REFERRING VET

Dr. Shaw

INVOICE

43800

DATE

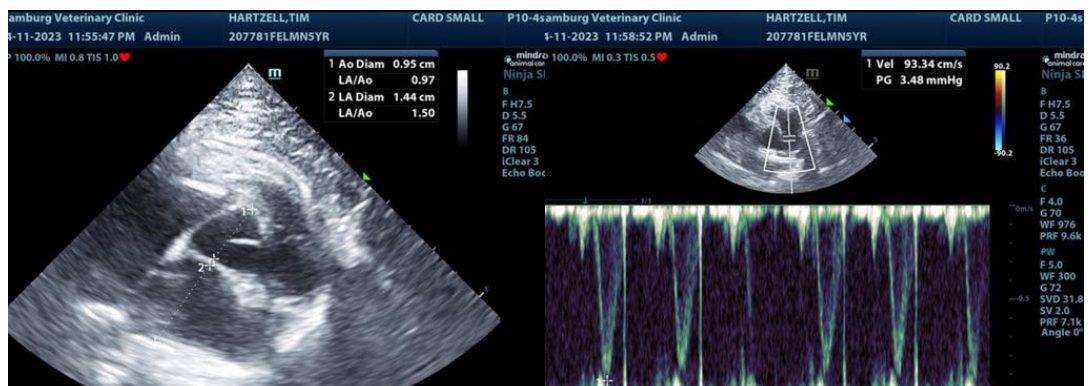
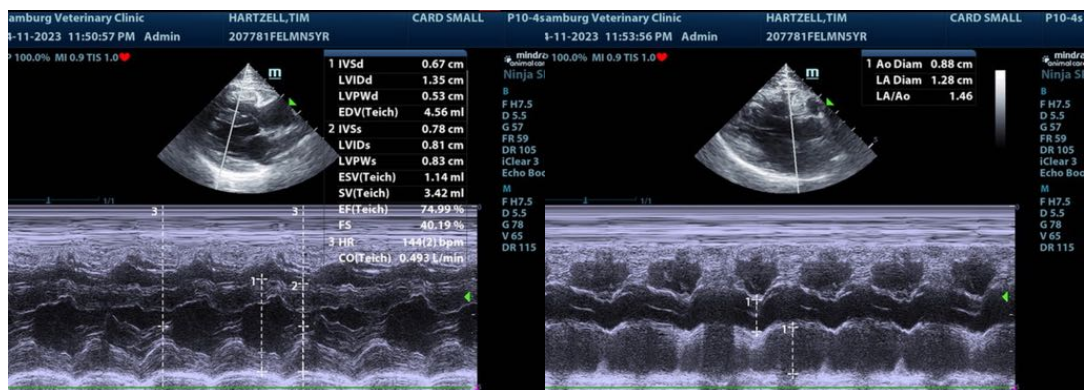
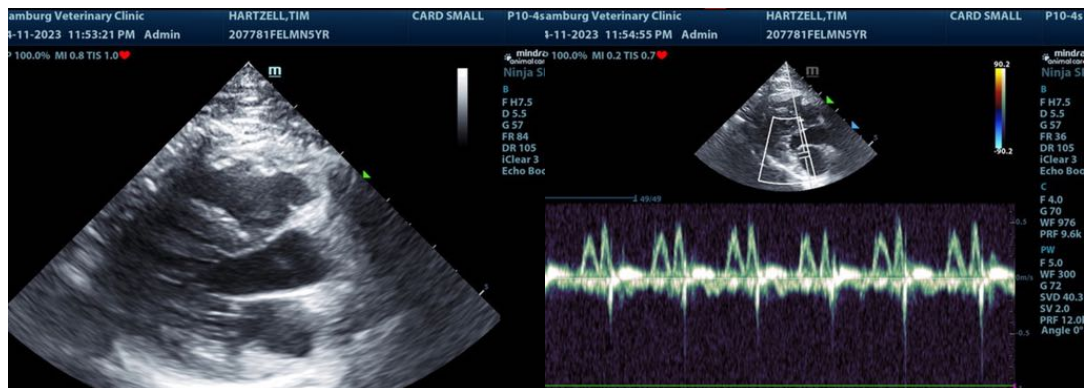
4/11/23

INTERPRETATION OF THE FINDINGS & FURTHER RECOMMENDATIONS

There is no evidence of cardiac disease that would be responsible for the clinical signs. Given the patient's history skull and cervical spine CT is indicated with contrast.

ABOUT SONOPATH CT SERVICES:

SonoPath CT Services are offered at the SonoPath Imaging and Veterinary Education Center, 141 Main St (rt 206), Andover, New Jersey, a 20-minute drive west on route 80/206 North from the route 80/287 interchange/Parsippany, New Jersey. More information can be found at <https://sonopath.com/resources/sonopaths-teleconsultation-services-and-sdep-certification/sonopath-ct-services>





PATIENT

Tim Hartzell

The information and recommendations provided are based on the images presented by the referring veterinarian/sonographer. No evaluation can be communicated regarding pathology that was not visible in the image/video clips provided.

SPECIES

Feline

Thank you for this referral. If the clinical or image interpretation does not parallel your findings or if I can be of any further assistance please contact me.

BREED

Domestic Shorthair

Eric Lindquist, DMV, DABVP, Cert. IVUSS, CEO of SonoPath.com
info@SonoPath.com

SEX

Neutered male

AGE

5 years

WEIGHT

13.5 lbs

INTERPRETED BY

Eric Lindquist, DMV
DABVP, Cert. IVUSS

**IMAGING
PERFORMED BY**

JK

HOSPITAL NAME

Hamburg VC

REFERRING VET

Dr. Shaw

INVOICE

43800

DATE

4/11/23