



PATIENT

Maisy Tackette

PRESENTING CLINICAL SIGNS

History: Hx of recurrent UTI

SPECIES

Canine

ULTRASONOGRAPHIC EXAMINATION OF THE ABDOMEN

Urinary System

The **urinary bladder**, trigone, and pelvic urethra presented normal thicknesses and normal tone. The ureters were not visible which is normal. No uroliths or sediment were visualized and anechoic urine was present. No evidence of inflammatory or neoplastic changes was noted. Ureteral papillae were normal.

BREED

Cocker Spaniel

The uterus was unremarkable with no evidence of pathology.

SEX

Intact female

The **kidneys** revealed normal size and structure, corticomedullary definition and ratio for this age. The cortices presented largely uniform texture with normal echogenic relationship to liver and spleen. Medullary structure differed distinctly from the cortex and no evidence of pelvic dilation was present. The capsules were acceptably uniform without significant irregularities. The right kidney measured 5.52 cm. The left kidney measured 4.89 cm.

AGE

4 years

WEIGHT

38 lbs

Adrenal Glands

The left **adrenal gland** was uniform and measured 1.48 x 0.53 cm at the caudal pole and 0.45 cm at the cranial pole. The region of the right adrenal gland was unremarkable.

INTERPRETED BY

Eric Lindquist, DMV
DABVP, Cert. IVUSS

Spleen

The **spleen** presented a smooth homogeneous parenchyma hyperechoic to liver and renal cortical parenchyma. The capsule was smooth without noticeable expansion or deviation from within the spleen or adjacent pathology. The splenic vasculature demonstrated normal volume without signs of congestion or thrombosis. No sonographic evidence of acute or chronic inflammatory, neoplastic, or infarctual changes was noted.

IMAGING PERFORMED BY

Dr. Waffle

HOSPITAL NAME

Torch Lake VC

Liver

The **liver** images submitted revealed subjectively normal liver size, contour, and structure. Parenchymal echogenicity was naturally coarse and hypoechoic to the spleen. Vascular and biliary tracts were of normal volume with no evidence of congestion. The gallbladder presented acceptably thin walls with primarily anechoic content. The cystic and common bile ducts were normal. No pathological hepatic lymphadenopathy was evident. No overt structural evidence of inflammatory, infiltrative or regenerative pathology was evident.

REFERRING VET

Dr. Waffle

INVOICE

43801

Gastrointestinal

Examination of the **gastrointestinal tract** revealed a stomach and intestine free of stasis, of normal wall thickness, acceptable curvilinear mural detail, and peristaltic activity. Small and large intestine

DATE

4/11/23



PATIENT

demonstrated normal luminal chyme and stool consistency respectively. No obstructive or overt infiltrative disease was noted. No associated abnormal lymphatic activity was noted.

Maisy Tackette

SPECIES

Pancreas

Canine

The base and limbs of the **pancreas** were observed to be largely isoechoic to surrounding omental fat. Pancreatic duct and capsular contour were acceptably normal and parenchyma respected normal curvilinear patterns. No overt evidence of active inflammatory or neoplastic disease was noted.

BREED

Cocker Spaniel

ULTRASONOGRAPHIC FINDINGS

SEX

Structurally unremarkable abdomen.

Intact female

INTERPRETATION OF THE FINDINGS & FURTHER RECOMMENDATIONS

AGE

There is no evidence of pathology. Examination of the vaginal vestibule is recommended to assess for recessed vulva or urine pooling is indicated.

4 years

WEIGHT

38 lbs

INTERPRETED BY

Eric Lindquist, DMV
DABVP, Cert. IVUS

IMAGING PERFORMED BY

Dr. Waffle

HOSPITAL NAME

Torch Lake VC

REFERRING VET

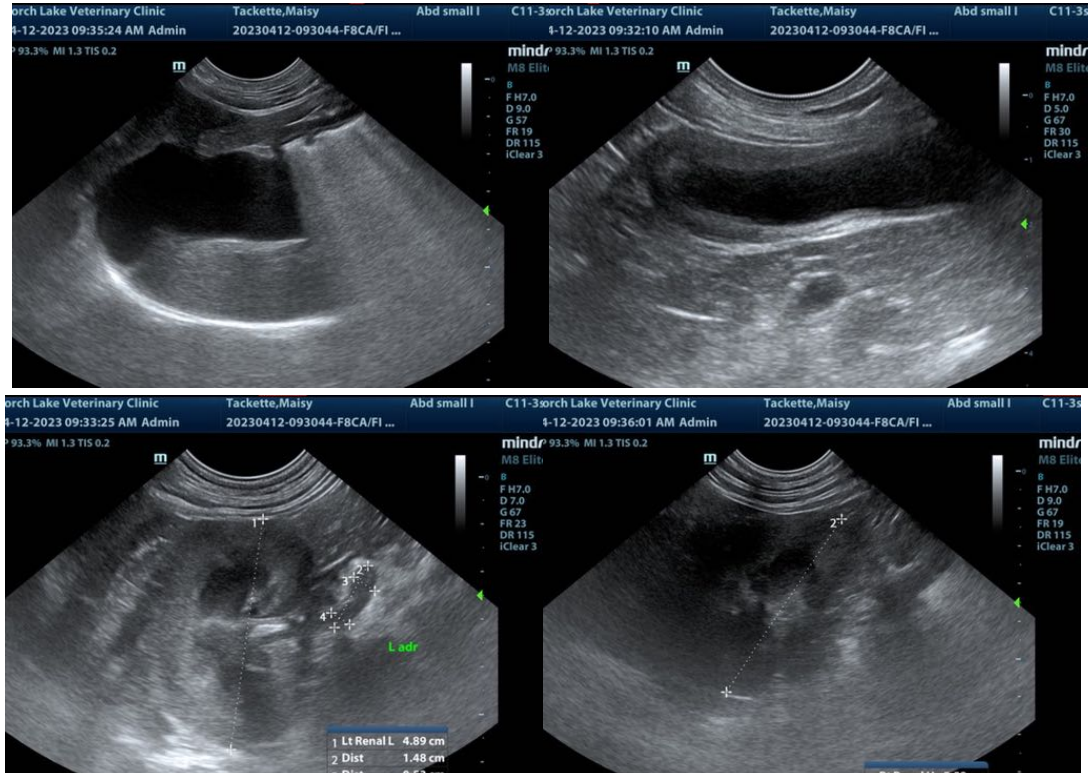
Dr. Waffle

INVOICE

43801

DATE

4/11/23



The information and recommendations provided are based on the images presented by the referring veterinarian/sonographer. No evaluation can be communicated regarding pathology that was not visible in the image/video clips provided.

Thank you for this referral. If the clinical or image interpretation does not parallel your findings or if I



PATIENT

can be of any further assistance please contact me.

Maisy Tackette

Eric Lindquist, DMV, DABVP, Cert. IVUSS, CEO of SonoPath.com
info@SonoPath.com

SPECIES

Canine

BREED

Cocker Spaniel

SEX

Intact female

AGE

4 years

WEIGHT

38 lbs

INTERPRETED BY

Eric Lindquist, DMV
DABVP, Cert. IVUSS

**IMAGING
PERFORMED BY**

Dr. Waffle

HOSPITAL NAME

Torch Lake VC

REFERRING VET

Dr. Waffle

INVOICE

43801

DATE

4/11/23