

PATIENT

Justine Maldonado

PRESENTING CLINICAL SIGNS

History: Anorexia Evaluate for neoplasia. ALKP 2179, ALT 273, glucose 55.

SPECIES

Canine

ULTRASONOGRAPHIC EXAMINATION OF THE ABDOMEN

Urinary System

The **urinary bladder**, trigone, and pelvic urethra presented normal thicknesses and normal tone. The ureters were not visible which is normal. No uroliths or sediment were visualized and anechoic urine was present. No evidence of inflammatory or neoplastic changes was noted. Ureteral papillae were normal.

BREED

Chihuahua

SEX

Neutered male

The **kidneys** revealed largely normal size and structure, corticomedullary definition and ratio (cortex 1/3 of medulla) were essentially maintained with some age-related loss of curvilinear patterns regarding the capsule and C/M junction. The cortices presented largely uniform texture with some increased echogenicity expected for his age patient. Medullary structure differed distinctly from that of the cortex and no evidence of pelvic dilation was present. The right kidney measured 5.02 cm. An anechoic cyst was noted at the dorsal cortex of the left kidney at 0.97 cm. The left kidney measured 5.12 cm.

AGE

10 years

WEIGHT

14.4 lbs

Adrenal Glands

Both **adrenal glands** were visualized and recognized as having normal shape, size, position and echogenicity for this breed. The phrenic vasculature, glandular echogenicity and detail were unremarkable. Capsule, cortex, and medullary definition were normal for this age patient. The right adrenal gland measured 1.84 x 0.51 cm at the caudal pole and 0.49 cm at the cranial pole. The left adrenal gland measured 2.0 x 0.57 cm at the caudal pole and 0.52 cm at the cranial pole.

INTERPRETED BY

Eric Lindquist, DMV
DABVP, Cert. IVUSS

Spleen

The **spleen** presented a smooth homogeneous parenchyma hyperechoic to liver and renal cortical parenchyma. The capsule was smooth without noticeable expansion or deviation from within the spleen or adjacent pathology. The splenic vasculature demonstrated normal volume without signs of congestion or thrombosis. No sonographic evidence of acute or chronic inflammatory, neoplastic, or infarctual changes was noted.

IMAGING PERFORMED BY

Denise Bruno, LVT,
RDMS

HOSPITAL NAME

Kenilworth AH

Liver

The **liver** revealed multi-focal, hypoechoic nodular changes measuring up to 1.4 cm. Parenchymal cysts were also noted in the liver with an over distended gallbladder and suspended debris. Some striation was noted. Cranial liver cyst measured 2.0 x 1.12 cm. Mildly increased portal markings were noted.

REFERRING VET

Dr. Mansour

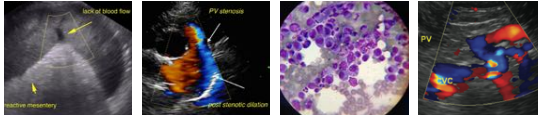
INVOICE

43814

Gastrointestinal

DATE

4/11/23



PATIENT

Justine Maldonado

There was some residual chyme and gas was noted in the **stomach**, yet not pathological. This is consistent with end post prandial presentation. Transit of chyme into the small intestine was normal. Curvilinear patterns were maintained throughout the GI tract. No evidence of pathology. Small and large intestine demonstrated normal luminal chyme and stool consistency respectively. No obstructive or overt infiltrative disease was noted. No associated abnormal lymphatic activity was noted.

SPECIES

Canine

Pancreas

BREED

Chihuahua

The base and limbs of the **pancreas** were observed to be largely isoechoic to surrounding omental fat. Pancreatic duct and capsular contour were acceptably normal and parenchyma respected normal curvilinear patterns. No overt evidence of active inflammatory or neoplastic disease was noted.

SEX

Neutered male

ULTRASONOGRAPHIC FINDINGS

AGE

10 years

Nodular cystic and hepatic changes. Inflammatory hepatopathy/nodular hyperplasia is likely.

Minor, excessive gallbladder debris.

Minor cortical infarcts and echogenic foci noted in both kidneys.

WEIGHT

14.4 lbs

INTERPRETATION OF THE FINDINGS & FURTHER RECOMMENDATIONS

FNA of the liver nodule is recommended +/- cyst drainage and culture. Ursodiol therapy can be justified. There was no evidence of neoplasia. The cause of anorexia is not overtly evident in the abdomen unless the nodular hepatic changes are playing a role in manifesting an early neoplastic process, yet this is most consistent with nodular hyperplasia.

INTERPRETED BY

Eric Lindquist, DMV
DABVP, Cert. IVUSS

CT Screen Autotext

There is no evidence of pathology. If suspicion of pathology in the CNS, thorax, or orthopedic regions is present, then CT of the region would be indicated.

IMAGING PERFORMED BY

Denise Bruno, LVT,
RDMS

HOSPITAL NAME

Kenilworth AH

REFERRING VET

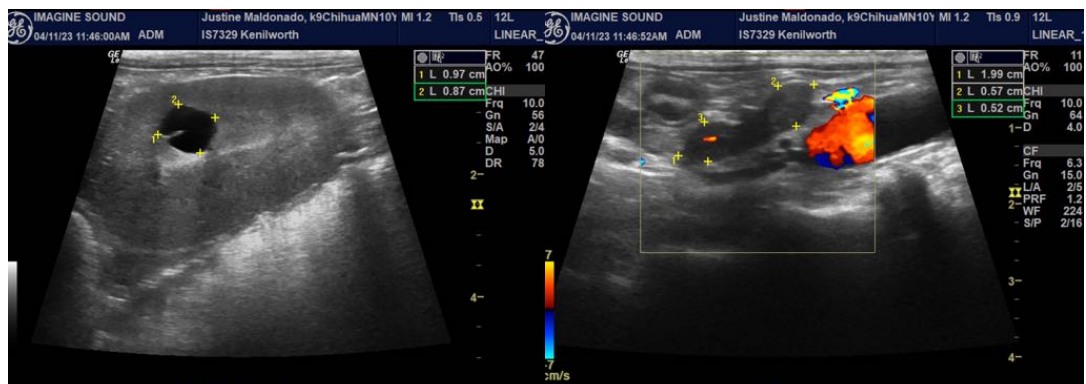
Dr. Mansour

INVOICE

43814

DATE

4/11/23





PATIENT

Justine Maldonado

SPECIES

Canine

BREED

Chihuahua

SEX

Neutered male

AGE

10 years

WEIGHT

14.4 lbs

INTERPRETED BY

Eric Lindquist, DMV
DABVP, Cert. IVUS

**IMAGING
PERFORMED BY**

Denise Bruno, LVT,
RDMS

HOSPITAL NAME

Kenilworth AH

REFERRING VET

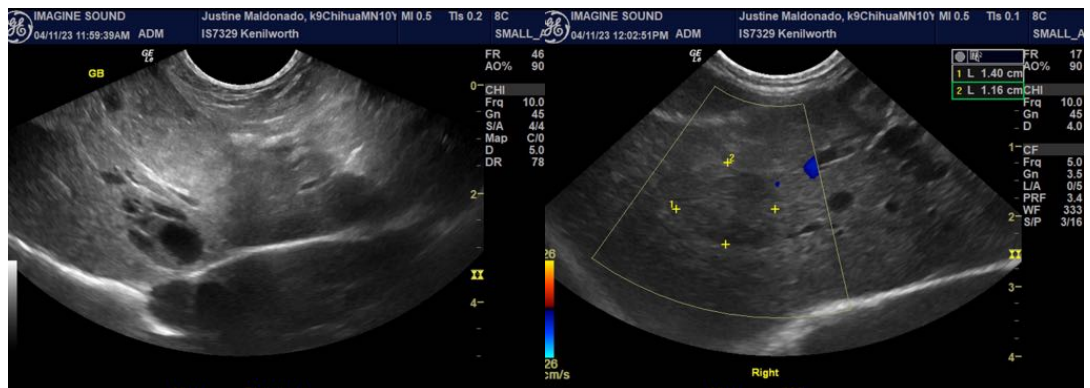
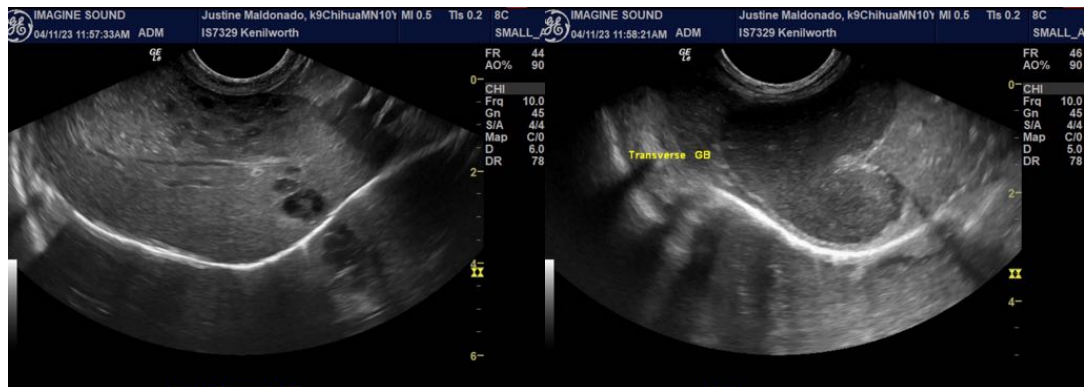
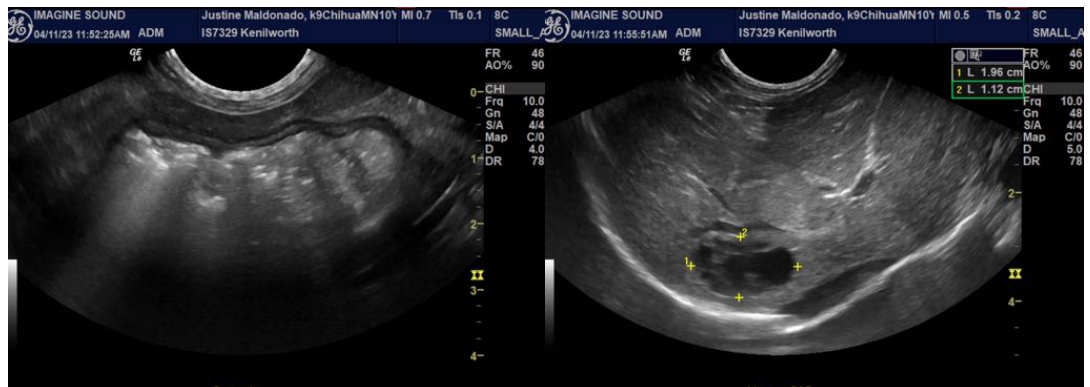
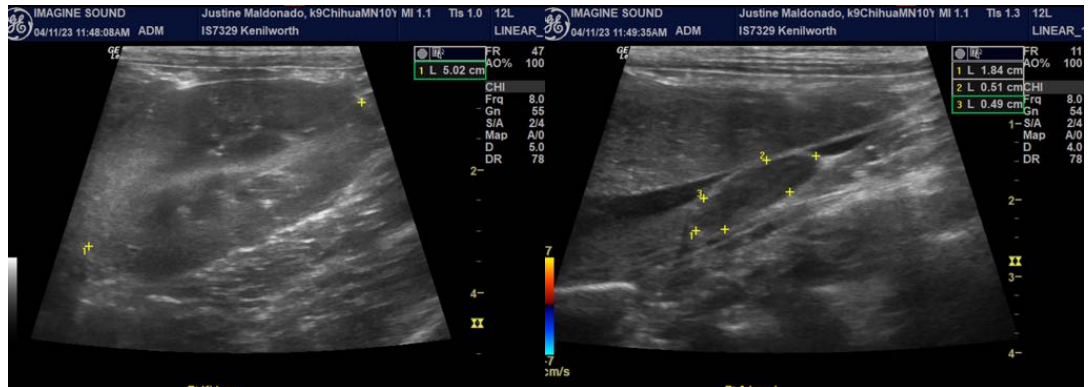
Dr. Mansour

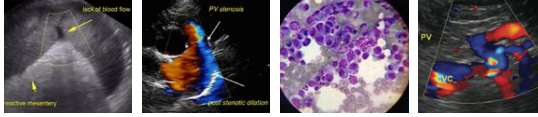
INVOICE

43814

DATE

4/11/23





PATIENT

Justine Maldonado

The information and recommendations provided are based on the images presented by the referring veterinarian/sonographer. No evaluation can be communicated regarding pathology that was not visible in the image/video clips provided.

SPECIES

Canine

Thank you for this referral. If the clinical or image interpretation does not parallel your findings or if I can be of any further assistance please contact me.

BREED

Chihuahua

Eric Lindquist, DMV, DABVP, Cert. IVUSS, CEO of SonoPath.com
Eric.Lindquist@SonoPath.com

SEX

Neutered male

AGE

10 years

WEIGHT

14.4 lbs

INTERPRETED BY

Eric Lindquist, DMV
DABVP, Cert. IVUSS

**IMAGING
PERFORMED BY**

Denise Bruno, LVT,
RDMS

HOSPITAL NAME

Kenilworth AH

REFERRING VET

Dr. Mansour

INVOICE

43814

DATE

4/11/23