



PATIENT PRESENTING CLINICAL SIGNS

Zeke Santi Hx of cystine stones. Has a cystotomy in January. Owner noticed hematuria yesterday
Abnormal PE/Chem/CBC/UA Results: OE unremarkable

SPECIES ULTRASONOGRAPHIC EXAMINATION OF THE ABDOMEN

Canine

Urinary System

BREED

English Mastiff

The **urinary bladder**, trigone, and pelvic urethra presented normal thicknesses and normal tone. The ureters were not visible which is normal. A large bladder calculus was noted and measured 1.5 cm. Suspended debris was noted along with polypoid bladder wall changes and other smaller calculi. There is no evidence of neoplasia. Chronic cystitis is likely. There is a mild potential transitional cell carcinoma. The polypoid changes appeared to be largely localized to the apex of the urinary bladder. Partial cystectomy is recommended to remove the polypoid would be ideal.

SEX

Male

The **prostate** was uniformly enlarged with lobar swelling appeared to impinge upon the urethra and mildly deviate the descending colon. The prostatic tissue was hyperechoic containing focal areas of decreased echogenicity. These changes are suggestive of either chronic inflammatory episodes, benign cystic pathology or both. Underlying neoplasia cannot be completely ruled-out but is lower on the differential list. This presentation is most consistent with benign prostatic hyperplasia with possible active prostatitis. Neutering or off-label Finasteride (Propecia) (0.1-0.5 mg/kg Sid) treatment is indicated +/- FNA or prostatic wash cytology and culture. The prostate measured 4.0 cm.

AGE

1 year

WEIGHT

192 lbs

ULTRASONOGRAPHIC FINDINGS

INTERPRETED BY

Eric Lindquist, DMV
DABVP, Cert. IVUSS

Bladder calculi. Polypoid cystitis pattern.

Mild, BPH prostate.

IMAGING PERFORMED BY

Dr. Waffle

INTERPRETATION OF THE FINDINGS & FURTHER RECOMMENDATIONS

Neutering, cystotomy, and apical partial cystectomy is indicated. Stone analysis and culture are indicated. There is minimal potential for bladder wall neoplasia, yet this cannot be completely ruled out histopathology.

HOSPITAL NAME

Torch Lake VC

REFERRING VET

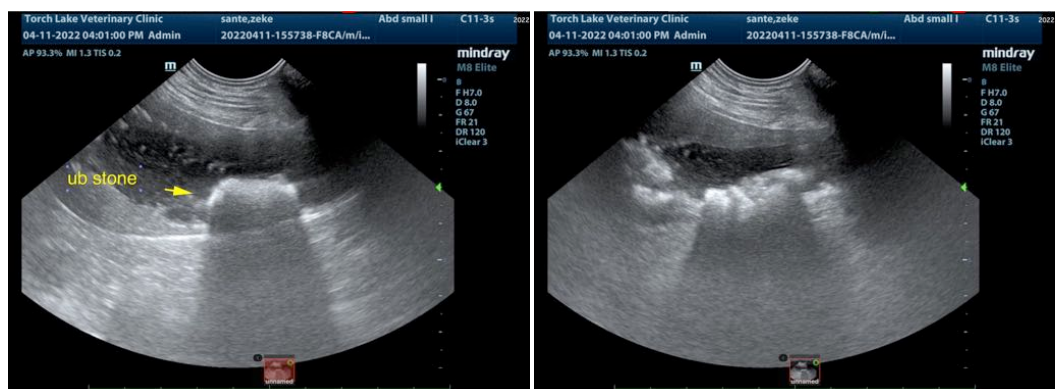
Dr. Waffle

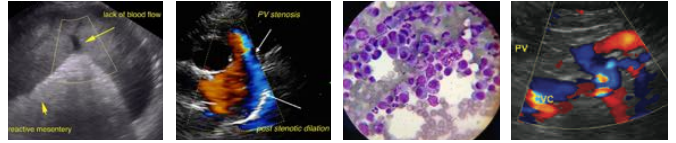
INVOICE

99199

DATE

4/11/22





PATIENT

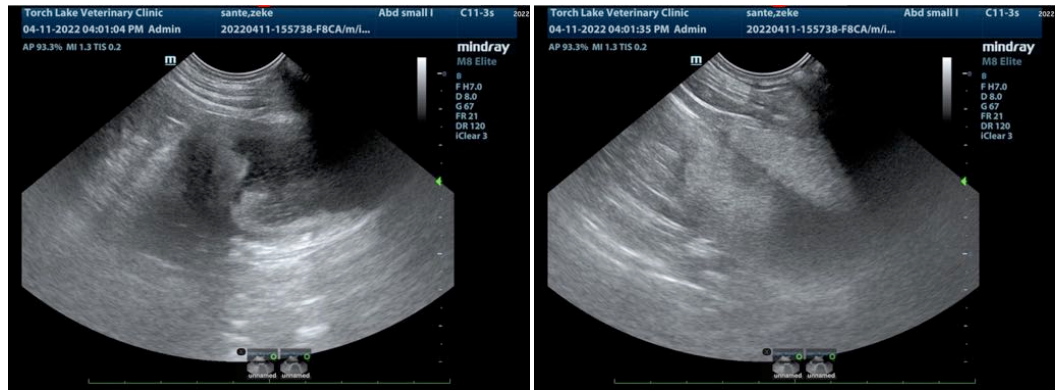
Zeke Santi

SPECIES

Canine

BREED

English Mastiff



SEX

Male

The information and recommendations provided are based on the images presented by the referring veterinarian/sonographer. No evaluation can be communicated regarding pathology that was not visible in the image/video clips provided.

AGE

1 year

Thank you for this referral. If the clinical or image interpretation does not parallel your findings or if I can be of any further assistance please contact me.

WEIGHT

192 lbs

Eric Lindquist, DMV, DABVP, Cert. IVUSS, CEO of SonoPath.com
info@SonoPath.com

INTERPRETED BY

Eric Lindquist, DMV
DABVP, Cert. IVUSS

IMAGING PERFORMED BY

Dr. Waffle

HOSPITAL NAME

Torch Lake VC

REFERRING VET

Dr. Waffle

INVOICE

99199

DATE

4/11/22