



PATIENT

Wyatt McGregor

PRESENTING CLINICAL SIGNS

History: Cryptorchidism. Testicular hunt.

SPECIES

Canine

ULTRASONOGRAPHIC EXAMINATION

The descended testicle in this patient was uniform and intact. The testicle measured 2.5 cm. The epididymis is unremarkable. The undescended testicle was in the subcutaneous fascia in an extra abdominal position and measured approximately 2.0 cm. This should be palpable. The prostate was uniform with minor edema lines.

BREED

Springer Spaniel

ULTRASONOGRAPHIC FINDINGS

Subcutaneous cryptorchid, extra abdominal.

SEX

Male

INTERPRETATION OF THE FINDINGS & FURTHER RECOMMENDATIONS

The left and right sides were not labeled. Therefore, I could not distinguish which testicle was distended and which was crypt; however, the cryptorchid is in the subcutaneous position and should be palpable just outside the body wall caudal to the inguinal ring.

AGE

1 year

WEIGHT

22 kg

INTERPRETED BY

Eric Lindquist, DMV
DABVP, Cert. IVUSS

IMAGING PERFORMED BY

Dave Stasiuk RDMS,
RDCS

HOSPITAL NAME

Resolution Veterinary
Ultrasound

REFERRING VET

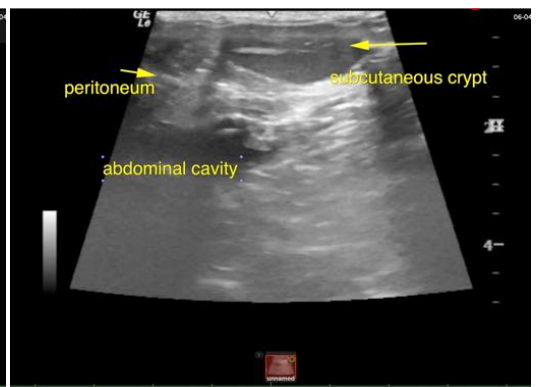
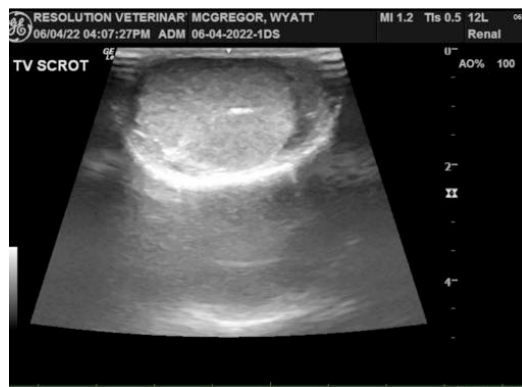
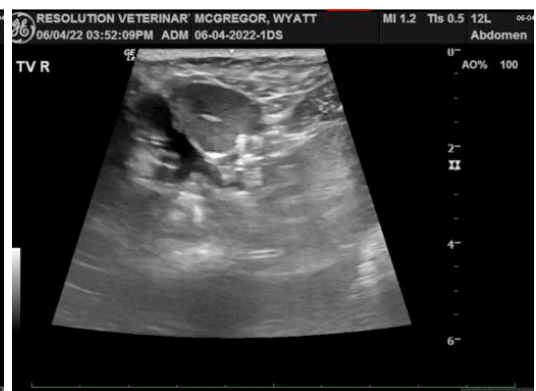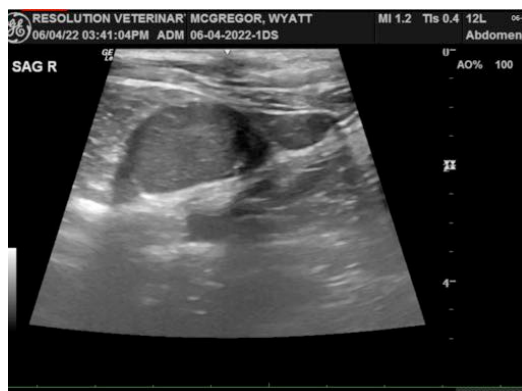Dr. Katz

INVOICE

99201

DATE

4/11/22





PATIENT

Wyatt McGregor

SPECIES

Canine

BREED

Springer Spaniel

SEX

Male

AGE

1 year

WEIGHT

22 kg

INTERPRETED BY

Eric Lindquist, DMV
DABVP, Cert. IVUSS

**IMAGING
PERFORMED BY**

Dave Stasiuk RDMS,
RDMS

HOSPITAL NAME

Resolution Veterinary
Ultrasound

REFERRING VET

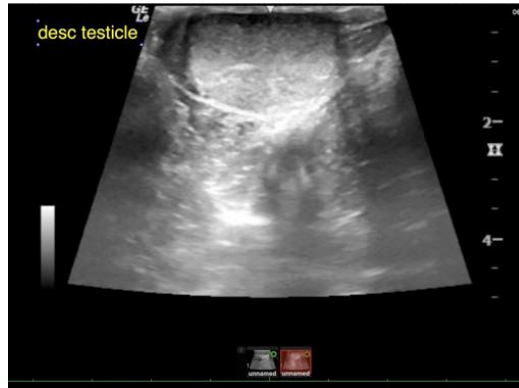
Dr. Katz

INVOICE

99201

DATE

4/11/22



The information and recommendations provided are based on the images presented by the referring veterinarian/sonographer. No evaluation can be communicated regarding pathology that was not visible in the image/video clips provided.

Thank you for this referral. If the clinical or image interpretation does not parallel your findings or if I can be of any further assistance please contact me.

Eric Lindquist, DMV, DABVP, Cert. IVUSS, CEO of SonoPath.com
info@SonoPath.com