



PATIENT PRESENTING CLINICAL SIGNS

Luna Safir History: Recheck CV dz, well controlled. Current meds: Vetmed, Furosemide

SPECIES ULTRASONOGRAPHIC EXAMINATION OF THE ABDOMEN

Canine The echocardiogram in this patient presented persistent mitral valve prolapse with mild persistent left atrial enlargement, primarily in the LA max position. The contractility appeared adequate. The heart rate is controlled. The right heart was unremarkable with tricuspid insufficiency and velocities that are consistent with pulmonary hypertension.

BREED

Chihuahua

SEX

Spayed Female

AGE

10 years

WEIGHT

8 lbs

INTERPRETED BY

Eric Lindquist, DMV
DABVP, Cert. IVUSS

IMAGING PERFORMED BY

Shari Reffi, CVT

HOSPITAL NAME

Rockaway AH

REFERRING VET

Dr. Maniar

INVOICE

99192

DATE

4/11/22

CANINE CARDIAC PARAMETERS	MR VMAX (m/s)	TR VMAX (m/s)	LA/AO (Boon method)	LA/AO (Heart Base; Swe)	FS (%)	EF (%)	EPSS (cm)
NORMAL PARAMETER	4.5-5.5	<2.7	1.3	<1.3	28-40	40-100	<0.6
PATIENT	5.11	3.5	1.63	1.62			0.32
CANINE CARDIAC PARAMETERS	HR (BPM)	AV VMAX (m/s)	PV MAX (m/s)	BODY WEIGHT	LA 2D short axis Base view (cm)	LVIDd Avg; 2D and m-mode short axis (cm)	LVIDs Avg; 2D and m-mode short axis (cm)
NORMAL PARAMETER	50-100	0.7-1.7	0.7-1.6				
PATIENT		1.0	1.0	8 lbs	2.5 max		

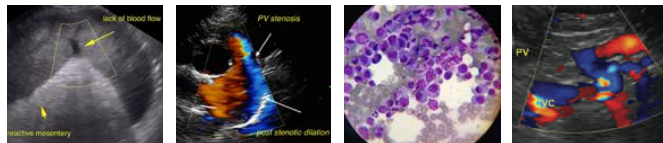
ULTRASONOGRAPHIC FINDINGS

Mitral valve prolapse, valvular disease, mild left atrial volume overload.

INTERPRETATION OF THE FINDINGS & FURTHER RECOMMENDATIONS

The cardiac presentation appears to be somewhat compensated at this time. Refinement of therapy is indicated. I recommend adding ace inhibitor at 0.5 mg/kg s.i.d. progressing to b.i.d. Recheck echocardiogram in 1-3 months

The heart has some volume overload and is working to compensate for the valvular insufficiency. Target respiratory rate is < 20 resp/minute after therapy. After initiating therapy, I recommend recheck on the clinical exam, BUN, Creatinine, USG, Chest radiographs & Blood pressure in 5-7 days. Earlier if clinical decompensation is occurring. I do not recommend anesthesia at this time until stabilization has occurred on the recommended medications. Repeat preanesthetic echo is ideal if anesthesia is eventually necessary



PATIENT

Luna Safir

SPECIES

Canine

BREED

Chihuahua

SEX

Spayed Female

AGE

10 years

WEIGHT

8 lbs

INTERPRETED BY

Eric Lindquist, DMV
DABVP, Cert. IVUSS

IMAGING PERFORMED BY

Shari Reffi, CVT

HOSPITAL NAME

Rockaway AH

REFERRING VET

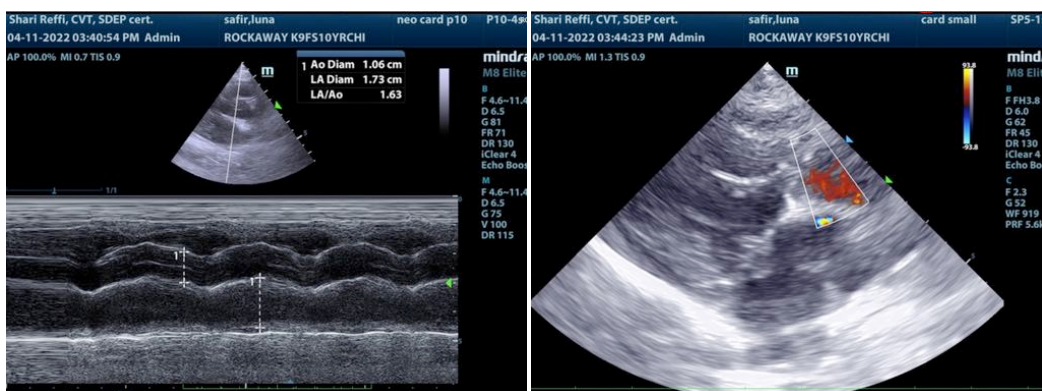
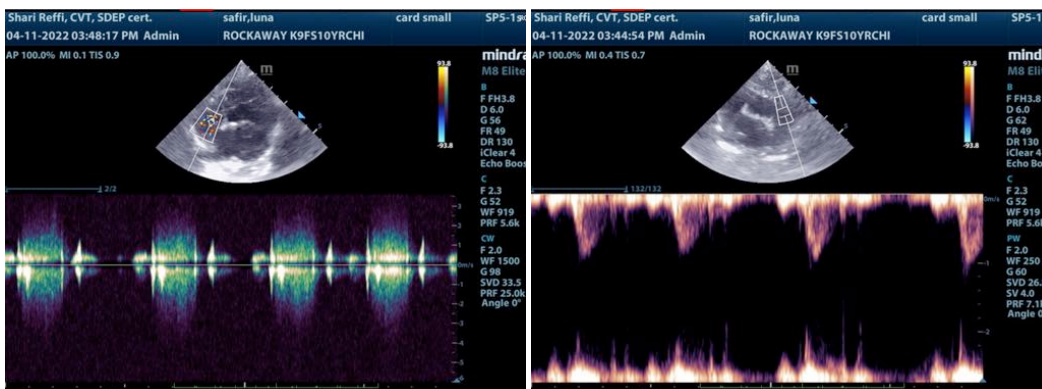
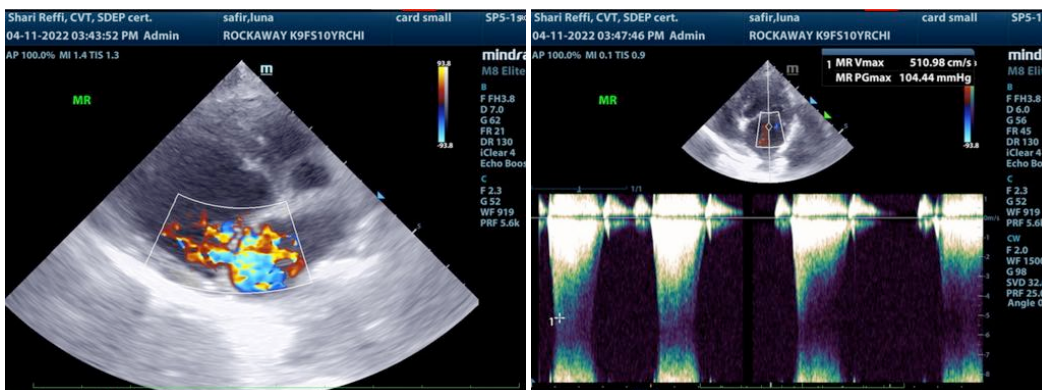
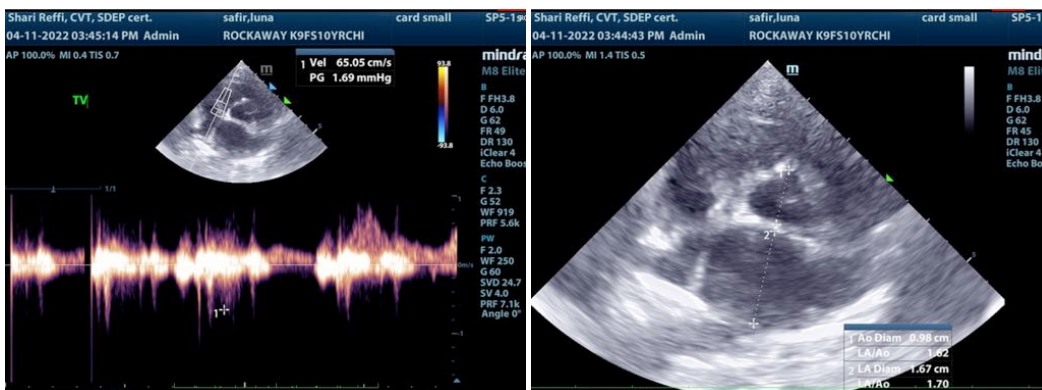
Dr. Maniar

INVOICE

99192

DATE

4/11/22





PATIENT

Luna Safir

The information and recommendations provided are based on the images presented by the referring veterinarian/sonographer. No evaluation can be communicated regarding pathology that was not visible in the image/video clips provided.

SPECIES

Canine

Thank you for this referral. If the clinical or image interpretation does not parallel your findings or if I can be of any further assistance please contact me.

BREED

Chihuahua

Eric Lindquist, DMV, DABVP, Cert. IVUSS, CEO of SonoPath.com
Info@SonoPath.com

SEX

Spayed Female

AGE

10 years

WEIGHT

8 lbs

INTERPRETED BY

Eric Lindquist, DMV
DABVP, Cert. IVUSS

**IMAGING
PERFORMED BY**

Shari Reffi, CVT

HOSPITAL NAME

Rockaway AH

REFERRING VET

Dr. Maniar

INVOICE

99192

DATE

4/11/22