



PATIENT

Amias Castania

PRESENTING CLINICAL SIGNS

Grade 2/6 murmur. No clinical signs
Abnormal PE/Chem/CBC/UA Results: BP 178/103(153),144/84(115),125/85(105)

SPECIES

Feline

ULTRASONOGRAPHIC EXAMINATION OF THE HEART

The echocardiogram in this patient demonstrated normal **left atrial** size based on 3 separate LA measurements. The cranial and caudal **mitral** valve leaflets presented normal linear structure and kinetics.. The **left ventricle** presented normal thicknesses with linear contour and was not dilated nor restricted. The **myocardium** presented normal echogenicity without subjective evidence of significant fibrotic or ischemic disease. **Contractility** of the ventricular walls was adequate and in normal range for this patient evidenced by the fractional shortening measurement and subjective evaluation of the different regions and angles of the myocardium. The **left ventricular outflow** tract demonstrated normal laminar flow and subjective structural integrity. The **right atrium** and auricle revealed normal size, structure and content. No evidence of masses was noted or chamber overload. **Tricuspid** valve was mildly thickened in this patient with mild insufficiency. The **right ventricular** free wall hypertrophy was noted. **Pulmonic** tract assessment revealed normal valve structure, laminar flow, and diameter (approx.1:1 pa/ao ratio). No visible **pericardial** or free pleura fluid was noted or extra cardiac pathology in the visible planes. The cranial **mediastinum** and **pericardial** regions were free of masses in the visible window.

BREED

Domestic Shorthair

SEX

Neutered male

AGE

4 years

WEIGHT

9 lbs

INTERPRETED BY

Eric Lindquist, DMV
DABVP, Cert. IVUSS

IMAGING PERFORMED BY

JK

HOSPITAL NAME

Hamburg VC

REFERRING VET

Dr. Martens

FELINE CARDIAC PARAMETERS	BODY WEIGHT (kg)	HR (BPM)	IVSd (cm)	LVIDd (cm)	LVWd (cm)	FS (%)	EF (%)
NORMAL PARAMETER	-----	150-240	0.3-0.6	1.0-2.1	0.25-0.6	35-67	80-100
PATIENT		178	0.57	1.72	0.57	66	95
FELINE CARDIAC PARAMETERS	LA/AO (Boon)	LA/AO HEART BASE (Sisson)	LA 2D 4-chamber long axis AS to FW (Sisson) (cm)	LVOT VEL. (m/s)	RVOT VEL. (m/s)	IVRT (m/)	
NORMAL PARAMETER	<1.5	0.88-1.79	0.7-1.7	<1.6	<1.3	40-60	
PATIENT	1.3	1.1	1.5 max	1.6	1.3	NM	
Adapted from June Boon, Veterinary Echocardiography, 1998 Sisson D et al. JVIM 1991; 5: 232, Jacobs et al. Am J Vet Res 1985; 46:1705							

INVOICE

98182

ULTRASONOGRAPHIC FINDINGS

Minor tricuspid insufficiency and right ventricular hypertrophy, not clinically significant.

DATE

4/11/22

INTERPRETATION OF THE FINDINGS & FURTHER RECOMMENDATIONS

No therapy is recommended at this time. A recheck echocardiogram is recommended in 1 year.



PATIENT

Amias Castania

SPECIES

Feline

BREED

Domestic Shorthair

SEX

Neutered male

AGE

4 years

WEIGHT

9 lbs

INTERPRETED BY

Eric Lindquist, DMV
DABVP, Cert. IVUSS

IMAGING PERFORMED BY

JK

HOSPITAL NAME

Hamburg VC

REFERRING VET

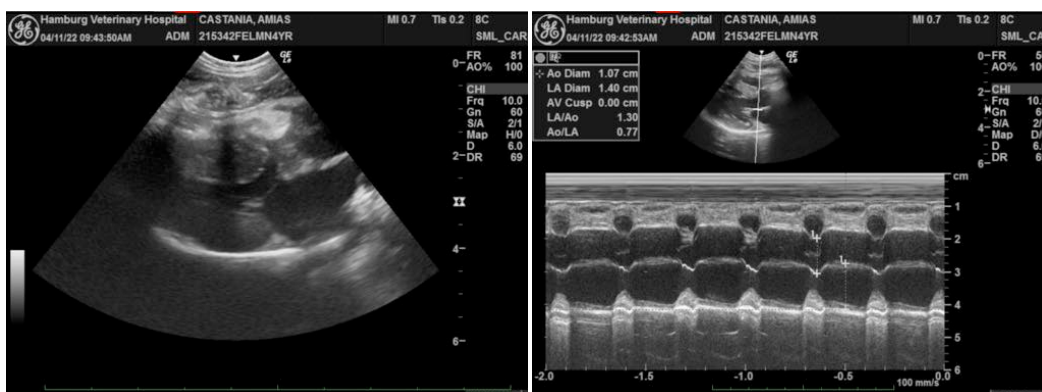
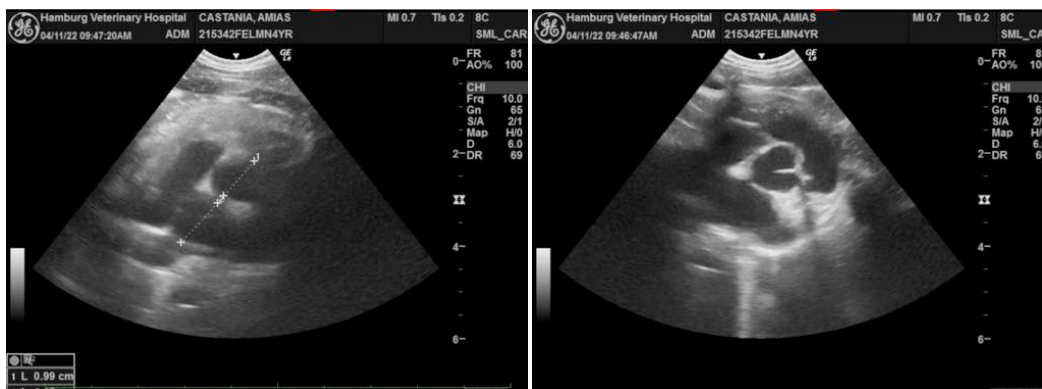
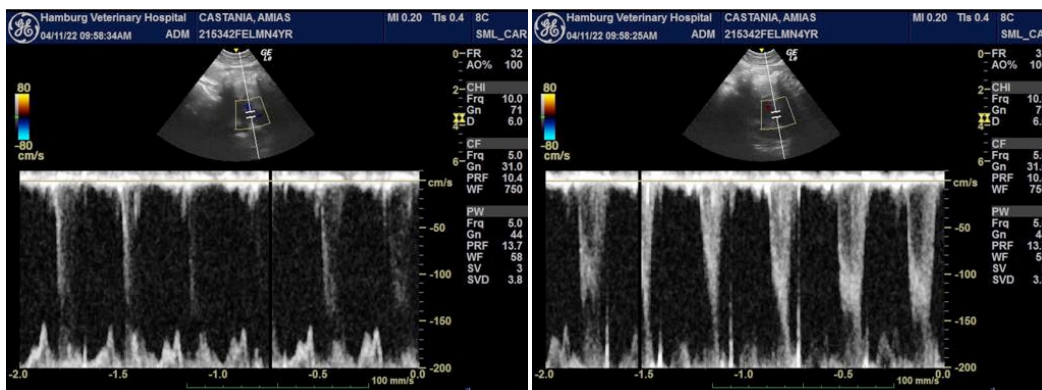
Dr. Martens

INVOICE

98182

DATE

4/11/22





PATIENT

Amias Castania

SPECIES

Feline

BREED

Domestic Shorthair

SEX

Neutered male

AGE

4 years

WEIGHT

9 lbs

INTERPRETED BY

Eric Lindquist, DMV
DABVP, Cert. IVUSS

IMAGING PERFORMED BY

JK

HOSPITAL NAME

Hamburg VC

REFERRING VET

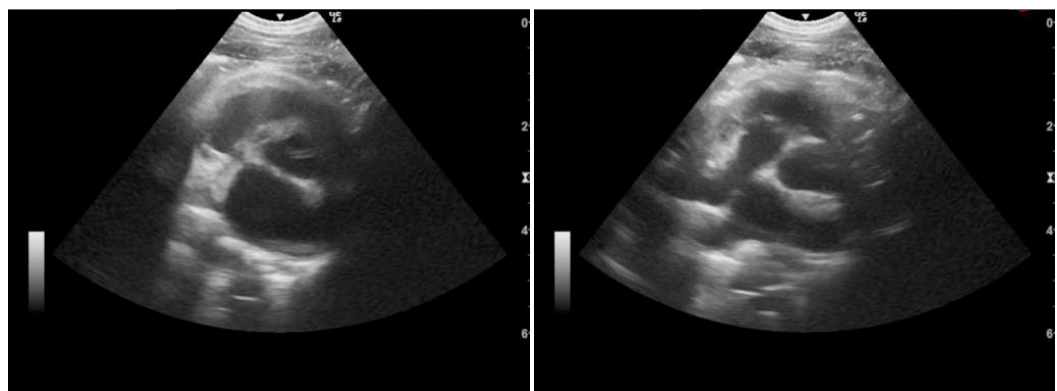
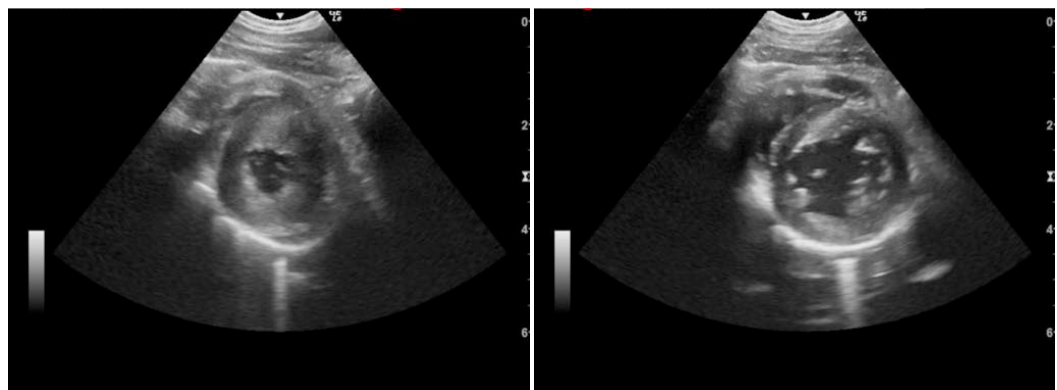
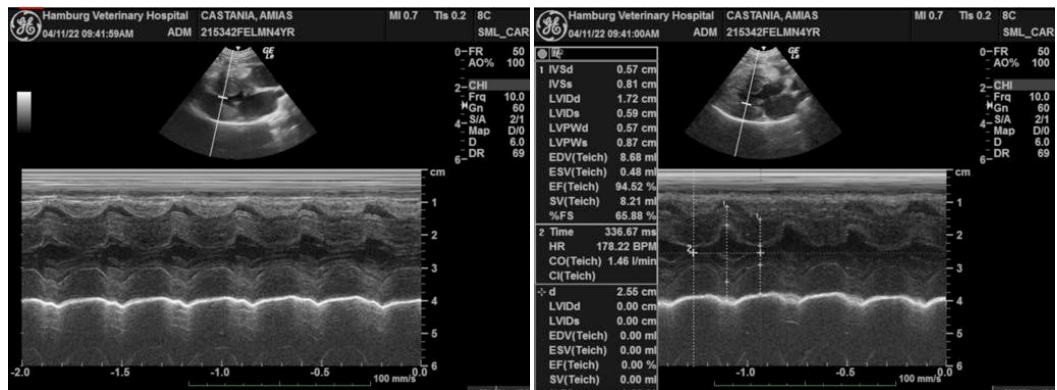
Dr. Martens

INVOICE

98182

DATE

4/11/22



The information and recommendations provided are based on the images presented by the referring veterinarian/sonographer. No evaluation can be communicated regarding pathology that was not visible in the image/video clips provided.

Thank you for this referral. If the clinical or image interpretation does not parallel your findings or if I can be of any further assistance please contact me.



PATIENT

Amias Castania

Eric Lindquist, DMV, DABVP, Cert. IVUSS, CEO of SonoPath.com
info@SonoPath.com

SPECIES

Feline

BREED

Domestic Shorthair

SEX

Neutered male

AGE

4 years

WEIGHT

9 lbs

INTERPRETED BY

Eric Lindquist, DMV
DABVP, Cert. IVUSS

**IMAGING
PERFORMED BY**

JK

HOSPITAL NAME

Hamburg VC

REFERRING VET

Dr. Martens

INVOICE

98182

DATE

4/11/22