



PATIENT

Trigger Zavala

SPECIES

Canine

BREED

Chihuahua

SEX

Neutered Male

AGE

15

WEIGHT

7

INTERPRETED BY

Eric Lindquist, DMV,
DABVP (CFM), Cert.
IVUS

IMAGING PERFORMED BY

Matt Heinlein

HOSPITAL NAME

TLC Animal Hospital

REFERRING VET

Priscilla Rubio, DVM

INVOICE

74402

DATE

4/10/26

PRESENTING CLINICAL SIGNS

Tigger is a 15yo MN Chihuahua that presented for annual bloodwork where results showed normal CBC, hypercalcemia, elevated SDMA, elevated ALT (188) and ALP (382) on Feb 21st, however today ALT is 227 and ALP 425. Hypercalcemia was confirmed via hypercalcemia of malignancy panel and results point toward primary hyperparathyroidism. Patient also has Stage B1 DVD and 4/6 heart murmur confirmed via echocardiogram. Radiographs show renal stones and possible ureteral stone. P has stage 4/4 periodontal disease. Asymptomatic at this time. Goal is to find possible underlying causes for elevated liver values, renal work up, and check for parathyroid gland neoplasia.

ULTRASONOGRAPHIC EXAMINATION OF THE THYROID & ABDOMEN

Thyroid

The thyroid regions were imaged. Normal salivary glands, trachea, esophagus, and regional tissues. The visible portions of the thyroid lobes were uniform, measuring approximately 5.0 mm. Occasional normal parathyroid noted. No evidence of primary adenomas, however I cannot rule out their presence.

Urinary System

The **urinary bladder** revealed a grouping of calculi measuring approximately 1.0 cm as a grouping, with slight thickening of the cystourethral junction. The bladder wall itself was unremarkable.

The prostate was uniform at 5.0 mm.

The **kidneys** revealed largely normal size and structure, corticomedullary definition and ratio (cortex 1/3 of medulla) were essentially maintained with some age-related loss of curvilinear patterns regarding the capsule and C/M junction. The cortices presented largely uniform texture with some increased echogenicity expected for his age patient. Medullary structure differed distinctly from that of the cortex and no evidence of pelvic dilation was present. Moderate mineralization noted in both kidneys. Both pelvic and corticomedullary calculi noted. The right kidney measured 3.7 cm. The left kidney measured 3.1 cm. Cortical infarcts and regional collapse also noted.

Adrenal Glands

The **left adrenal gland** was slightly enlarged, measuring 0.80 cm at the caudal pole and 0.65 cm at the cranial pole.

The **right adrenal gland** was enlarged, irregular and nodular, with slight phrenic vein occupation. The adrenal appears resectable. The right adrenal gland measured 1.8 cm x 1.3 cm.

Spleen

The **spleen** presented a smooth homogeneous parenchyma hyperechoic to liver and renal cortical parenchyma. The capsule was smooth without noticeable expansion or deviation from within the spleen or adjacent pathology. The splenic vasculature demonstrated normal volume without signs of congestion or thrombosis. No sonographic evidence of acute or chronic inflammatory, neoplastic, or infarctual changes were noted.

Liver

Exam of the cranial abdomen demonstrated excessive **liver** size, swollen contour, with conserved uniform architecture. Parenchymal echogenicity was diffusely isoechoic to the spleen and falciform fat.



PATIENT

Trigger Zavala

The gallbladder was overdilated with suspended debris. This is expected for this type of presentation. There was no overt pathology.

SPECIES

Canine

Gastrointestinal

Examination of the **gastrointestinal tract** revealed a stomach and intestine free of stasis, of normal wall thickness, acceptable curvilinear mural detail, and peristaltic activity. Small and large intestine demonstrated normal luminal chyme and stool consistency respectively. No obstructive or overt infiltrative disease was noted. No associated abnormal lymphatic activity was noted.

BREED

Chihuahua

Pancreas

The base and limbs of the **pancreas** were observed to be largely isoechoic to surrounding omental fat. Pancreatic duct and capsular contour were acceptably normal and parenchyma respected normal curvilinear patterns. No overt evidence of active inflammatory or neoplastic disease was noted.

SEX

Neutered Male

ULTRASONOGRAPHIC FINDINGS

AGE

15

- Enlarged, nodular right adrenal gland with slight phrenic vein occupation – carcinoma, pheochromocytoma, adenoma all possible.
- Slightly enlarged left adrenal gland.
- Urinary bladder calculi.
- Age related renal changes with calculi.
- Vacuolar hepatopathy.

WEIGHT

7

INTERPRETATION OF THE FINDINGS & FURTHER RECOMMENDATIONS

INTERPRETED BY

Eric Lindquist, DMV,
DABVP (CFM), Cert.
IVUSS

Serial blood pressure measurements are recommended in this patient. If hypertension is an issue metanephrine level is recommended. If the patient appears Cushingoid and urine specific gravity is less than 1.020 then work-up for adrenal dependent Cushing's is indicated. Recheck is recommended in 2-3 weeks to assess for any progression of the adrenal gland.

IMAGING PERFORMED BY

Matt Heinlein

HOSPITAL NAME

TLC Animal Hospital

REFERRING VET

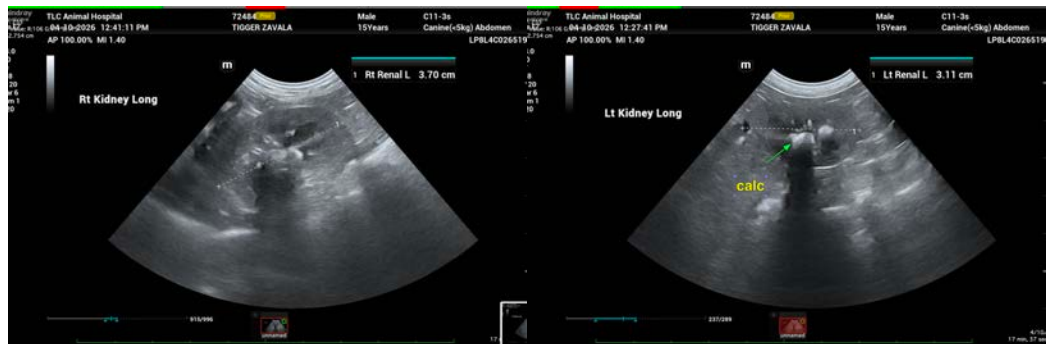Priscilla Rubio, DVM

INVOICE

74402

DATE

4/10/26





PATIENT

Trigger Zavala

SPECIES

Canine

BREED

Chihuahua

SEX

Neutered Male

AGE

15

WEIGHT

7

INTERPRETED BY

Eric Lindquist, DMV,
DABVP (CFM), Cert.
IVUSS

IMAGING PERFORMED BY

Matt Heinlein

HOSPITAL NAME

TLC Animal Hospital

REFERRING VET

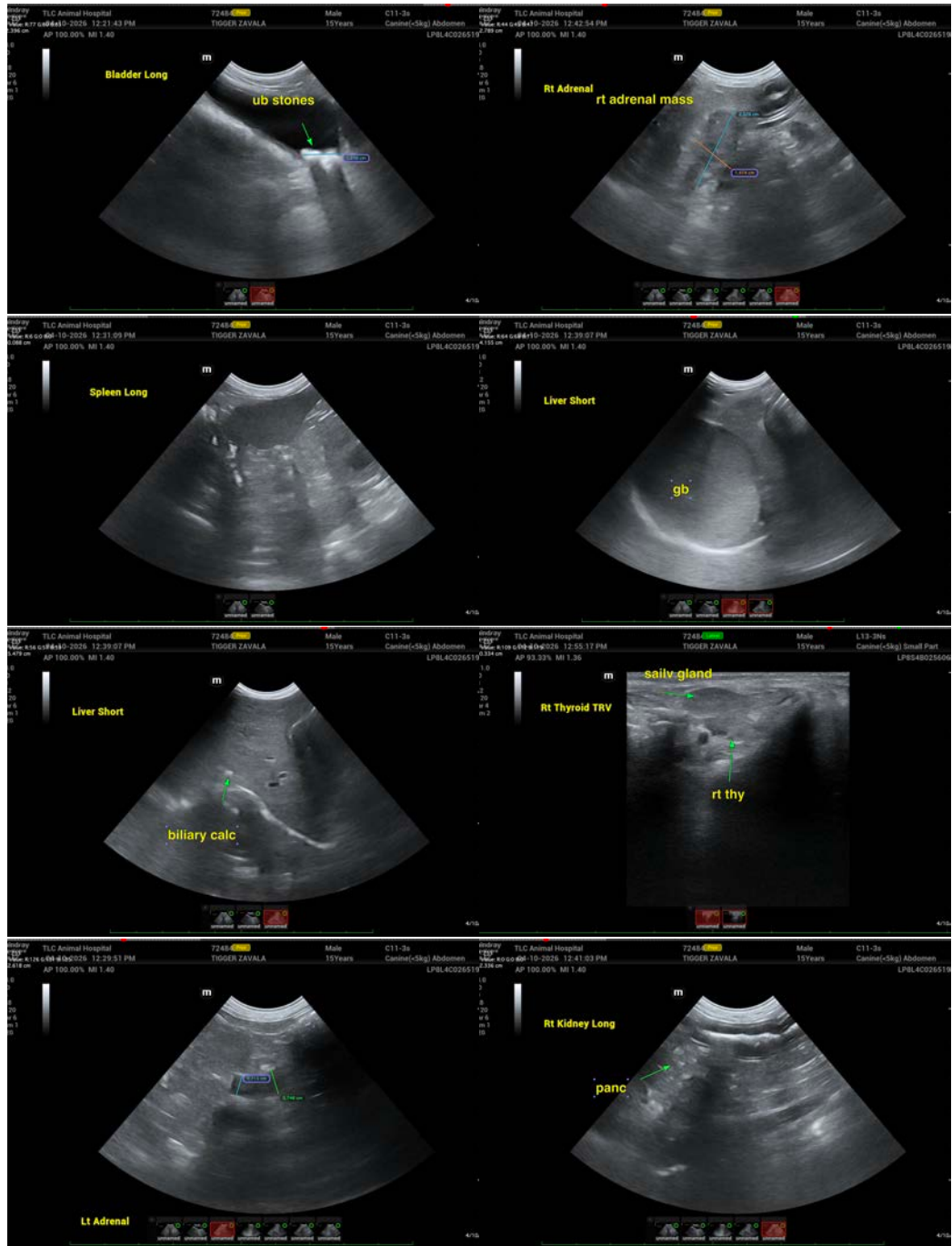
Priscilla Rubio, DVM

INVOICE

74402

DATE

4/10/26





PATIENT

Trigger Zavala

SPECIES

Canine

BREED

Chihuahua

SEX

Neutered Male

AGE

15

WEIGHT

7

INTERPRETED BY

Eric Lindquist, DMV,
DABVP (CFM), Cert.
IVUSS

IMAGING PERFORMED BY

Matt Heinlein

HOSPITAL NAME

TLC Animal Hospital

REFERRING VET

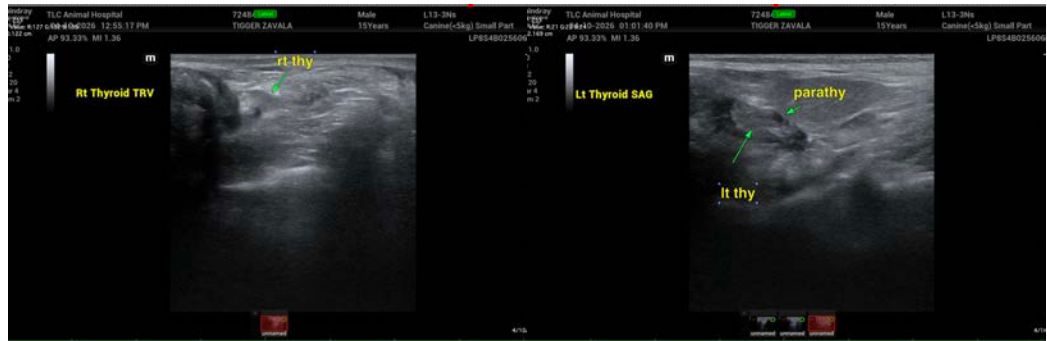Priscilla Rubio, DVM

INVOICE

74402

DATE

4/10/26



The information and recommendations provided are based on the images presented by the referring veterinarian/sonographer. No evaluation can be communicated regarding pathology that was not visible in the image/video clips provided.

Thank you for this referral. If the clinical or image interpretation does not parallel your findings or if I can be of any further assistance please contact me.

Eric Lindquist, DMV, DABVP(CFM), Cert. IVUSS,
CEO, Owner, Founder -- SonoPath.com
info@SonoPath.com



PATIENT

Trigger Zavala

SPECIES

Canine

BREED

Chihuahua

SEX

Neutered Male

AGE

15

WEIGHT

7

INTERPRETED BY

Eric Lindquist, DMV,
DABVP (CFM), Cert.
IVUSS

IMAGING PERFORMED BY

Matt Heinlein

HOSPITAL NAME

TLC Animal Hospital

REFERRING VET


Priscilla Rubio, DVM

INVOICE

74402

DATE

4/10/26



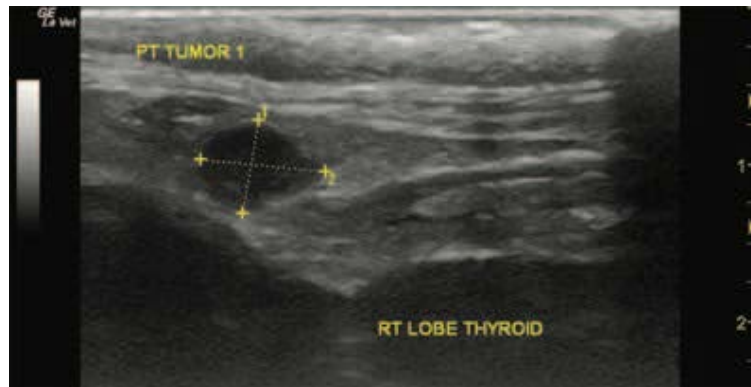The following is an applicable excerpt from the *Curbside Guide to Diagnosis & Treatment of Sonographic Disease* offered by [SonoPath.com](http://sonopath.com) Lindquist, Frank, Lobetti, and Modler.

An essential quick guide for every general practitioner and sonographer.

<https://sonopath.com/products/curbside-guide-editing-due-release-12012015>

CANINE HYPERCALCEMIA

<http://www.sonopath.com/CanineHypercalcemia>

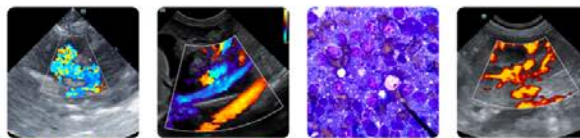


Long axis of the right thyroid lobe in a dog with a parathyroid adenoma. The right internal parathyroid gland (between calipers) shows severe uniform enlargement of more than 7mm.

Description: Hypercalcemia is defined as either a persistently elevated total calcium serum (> 12 mg/dl) or ionized calcium (> 1.45 mmol/l) concentration. Clinical signs are often absent with mild hypercalcemia (< 13 mg/dl). In fact, hypercalcemia is often only discovered when serum biochemistry is done for unrelated reasons. Clinical signs are usually mild when the serum calcium concentration is less than 14 mg/dl; however, signs become more readily apparent when the concentration exceeds 15 mg/dl. Life-threatening cardiac arrhythmias can develop when the serum calcium exceeds 18 mg/dl.

Common etiologies of hypercalcemia include humoral hypercalcemia of malignancy (HHM), hypoadrenocorticism, chronic kidney disease (CKD), hypervitaminosis D, and primary hyperparathyroidism. Less common etiologies include bone neoplasia, osteomyelitis, hypertrophic osteodystrophy, granulomatous disease, calcium supplementation, and oral phosphate binders.

Clinical Signs: Common clinical signs include polyuria, polydipsia, lethargy, inappetence, and weakness. With chronic hypercalcemia, calcium oxalate and calcium phosphate uroliths can form, resulting in clinical signs suggestive of lower urinary tract disease. Systemic signs of illness are suggestive of HHM.



PATIENT

Trigger Zavala

SPECIES

Canine

BREED

Chihuahua

SEX

Neutered Male

AGE

15

WEIGHT

7

INTERPRETED BY

Eric Lindquist, DMV,
DABVP (CFM), Cert.
IVUSS

IMAGING PERFORMED BY

Matt Heinlein

HOSPITAL NAME

TLC Animal Hospital

REFERRING VET

Priscilla Rubio, DVM

INVOICE

74402

DATE

4/10/26

Diagnosics: One important etiology of hypercalcemia is laboratory error; therefore, hypercalcemia should always be confirmed before embarking on any further diagnostic evaluation. Results of a CBC, serum biochemistry panel, and urinalysis, in conjunction with a patient history and findings from a physical examination, can often provide enough information to arrive at a diagnosis. The appendicular skeleton, peripheral lymph nodes, abdominal cavity, and rectum should all be carefully palpated for masses, lymphadenopathy, hepatomegaly, splenomegaly, and/or pain in the long bones. The following diagnostic tests are helpful for identifying an underlying malignancy: thoracic and abdominal radiographs; abdominal ultrasound; cytological evaluation of aspirates of the liver, spleen, lymph nodes, and bone marrow; determination of serum ionized calcium, parathyroid hormone (PTH), and parathyroid hormone-related protein concentration (PTHrP); and ultrasound of the neck. Ascertaining the concentrations of serum ionized calcium, PTH, and PTHrP helps differentiate primary hyperparathyroidism from HHM. The finding of one or more enlarged parathyroid glands upon conducting an ultrasound of the neck supports a diagnosis of primary hyperparathyroidism.

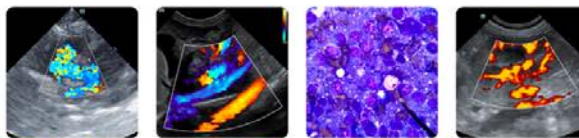
Hypoadrenocorticism-induced hypercalcemia usually occurs in conjunction with hyponatremia, hyperkalemia, and prerenal azotemia. With HHM and primary hyperparathyroidism, serum phosphorus concentration is often in the low to low-normal reference range. If the serum phosphorus concentration is high but kidney function is normal, hypervitaminosis D or osteolysis should be suspected.

It can be difficult to determine whether kidney failure is primary or secondary to hypercalcemia when hyperphosphatemia and hypercalcemia coexist with azotemia. Serum ionized calcium concentrations are typically normal or decreased in cases of renal failure and increased in cases of hypercalcemia caused by other disorders.

Sternal and hilar lymphadenopathy is common with lymphoma-induced hypercalcemia and can be readily identified on thoracic radiographs. In cases of multiple myeloma, discrete lytic lesions in the vertebrae or long bones, hyperproteinemia, proteinuria, and plasma cell infiltration in the bone marrow may be present. Cytological evaluation of the peripheral lymph nodes, bone marrow, and spleen can be helpful in identifying lymphoma.

Increased serum ionized calcium concentrations, detectable serum PTHrP concentrations, and non-detectable serum PTH concentrations are all diagnostic for HHM. Lymphoma is the most common etiology of HHM, but other tumors, such as apocrine gland adenocarcinoma and various carcinomas (e.g. mammary gland, squamous cell, bronchogenic), can all give rise to hypercalcemia. Increased serum ionized calcium, normal to increased serum PTH, and non-detectable PTHrP concentrations are diagnostic of primary hyperparathyroidism.

Differentials for Hypercalcemia: "HARD IONS"



PATIENT

Trigger Zavala

SPECIES

Canine

BREED

Chihuahua

SEX

Neutered Male

AGE

15

WEIGHT

7

INTERPRETED BY

Eric Lindquist, DMV,
DABVP (CFM), Cert.
IVUSS

IMAGING PERFORMED BY

Matt Heinlein

HOSPITAL NAME

TLC Animal Hospital

REFERRING VET

Priscilla Rubio, DVM

INVOICE

74402

DATE

4/10/26

Hyperparathyroid

Addison's

Renal

D-toxicity

Idiopathic

Osteolytic

Neoplastic

Spurious

PTH tumor: Elevated total and ionized Ca, low PTHrP, and normal/high PTH. Keeshonds, German Shepherds, and Golden Retrievers are all predisposed.

Addison's disease: Elevated total and normal ionized Ca, elevated BUN, hypoalbuminemia and hyperkalemia.

Renal failure: Elevated to normal total Ca, low ionized Ca, low PTHrP, elevated PTH, azotemia, and low urine specific gravity.

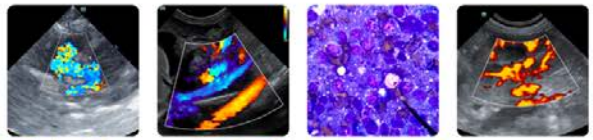
Vitamin D toxicity: Elevated total and ionized Ca, low PTHrP, and normal/low PTH.

Hypercalcemia of malignancy (HHM): Elevated total and ionized Ca, high PTHrP, and low PTH.

Granulomatous disease: Elevated total and ionized Ca, low PTHrP, and low PTH.

Renal failure: Elevated to normal total Ca, low ionized Ca, low PTHrP, elevated PTH, azotemia, and low urine specific gravity.

Treatment: Therapies for hypercalcemia are aimed at correcting the underlying etiology; however, because prolonged hypercalcemia can result in kidney damage, the use of fluid therapy, furosemide, and possibly prednisone is indicated in all cases to reduce serum calcium levels. Suggested dosages include saline (0.9% 120-180 ml/kg day IV), furosemide (1-4 mg/kg PO TID), and prednisone (0.25 mg/kg PO Q24hr).



PATIENT

Trigger Zavala

SPECIES

Canine

BREED

Chihuahua

SEX

Neutered Male

AGE

15

WEIGHT

7

INTERPRETED BY

Eric Lindquist, DMV,
DABVP (CFM), Cert.
IVUS

IMAGING PERFORMED BY

Matt Heinlein

HOSPITAL NAME

TLC Animal Hospital

REFERRING VET

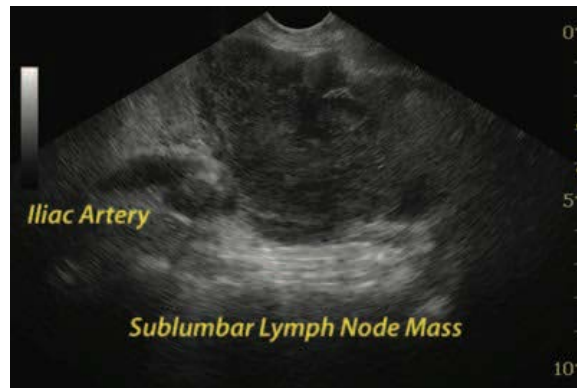
Priscilla Rubio, DVM

INVOICE

74402

DATE

4/10/26



Long axis of the left hypogastric lymph node in a hypercalcemic dog with lymphoma and hypercalcemia of malignancy. The lymph node is severely enlarged and rounded with a short-to-long-axis ratio > 0.5 indicating malignant infiltration. The regular echoarchitecture is lost, the hilus is not recognized, lymph node parenchyma is hypoechoic and heterogenous. Also note the mass effect on the external iliac artery. In light of hypercalcemia, lymphadenopathy in this region could also be owing to anal gland adenocarcinoma which can also be imaged sonographically.

References:

Chew DJ, Schenck PA, Jaege JQ. Clinical disorders of hypercalcemia and hypocalcemia in dogs and cats. Proceedings from the American College of Veterinary Internal Medicine, Charlotte, NC, June 4-7, 2003.

Feldman EC. Disorders of the parathyroid glands. In: Ettinger SJ, Feldman EC, ed. *Textbook of Veterinary Internal Medicine, 7th ed.* St. Louis, MO: Saunders Elsevier; 2010:1722-50.

Peterson ME. Hypercalcemia in dogs & cats: differential diagnosis & treatment. Proceedings from the Western Veterinary Conference, Las Vegas, NV, February 19-23, 2012.