



PATIENT

Stella Lowry

SPECIES

Canine

BREED

German Shepherd

SEX

Spayed Female

AGE

5 Years 5 Months

WEIGHT

113

INTERPRETED BY

Eric Lindquist, DMV,
DABVP (Canine &
Feline), Cert. IVUSS

PRESENTING CLINICAL SIGNS

History: brought in on 4/4 for lethargy, pt since stopped eating, has been in remission for lymphoma since December - stopped chemo then has been seeing oncologist monthly, rapid shallow breathing, seems confused to o, THOP chemo protocol finished thyroid meds 1.0 - 1/2 tab SID. Abnormal PE/Chem/CBC/UA Results: 4/6 - mch (lo) - 21.6, SDMA - 20(hi), creat - 1.8 (hi), chol - 439 (hi), proBNP - 10,000

ULTRASONOGRAPHIC EXAMINATION OF THE HEART & ABDOMEN

CANINE CARDIAC PARAMETERS	MR VMAX (m/s)	TR VMAX (m/s)	LA/AO (M-Mode)	LA/AO (Heart Base; Swe)	FS (%)	EF (%)	EPSS (cm)
NORMAL PARAMETER	4.5-5.5	<2.7	1.3	Up to 1.6	28-40	40-100	<0.6
PATIENT	--	--	NM	1.8	10	--	1.0
CANINE CARDIAC PARAMETERS	HR (BPM)	AV VMAX (m/s)	PV MAX (m/s)	BODY WEIGHT	LAD LA MAX 4 Chamber	LVIDd Avg; 2D and m-mode short axis (cm)	LVIDs Avg; 2D and m-mode short axis (cm)
NORMAL PARAMETER	50-100	0.7-1.7	0.7-1.6				
PATIENT	--	--	--	113	5.6	4.0	--

IMAGING PERFORMED BY

Heather

HOSPITAL NAME

ACC Flanders

REFERRING VET

Dr. Hallihan

INVOICE

36509

DATE

4/10/26

Cardiac Presentation

The **cardiac presentation** in this patient revealed volume overload and hypocontractility. Bradycardia was noted. Mitral insufficiency was noted. The right atrium and right ventricle were mildly dilated and mildly overloaded. Comet tail lung pattern was noted (suspect left sided heart failure); this should be assessed on radiographs.

Urinary System

The **urinary bladder**, trigone, and pelvic urethra presented normal thicknesses and normal tone. The ureters were not visible which is normal. No uroliths or sediment were visualized and anechoic urine was present. No evidence of inflammatory or neoplastic changes were noted. Ureteral papillae were normal. The pelvic urethra was imaged 2.0 cm beyond the cystourethral junction.

The **kidneys** revealed normal size and structure, corticomedullary definition and ratio for this age. The cortices presented largely uniform texture with normal echogenic relationship to liver and spleen. Medullary structure differed distinctly from the cortex and no evidence of pelvic dilation was present. The capsules were acceptably uniform without significant irregularities. The left kidney measured 6.0 cm. The right kidney measured 7.2 cm.

Adrenal Glands



PATIENT

The regions of the **adrenal glands** were imaged and revealed no evident pathology.

Stella Lowry

Spleen

SPECIES

The **spleen** presented a smooth homogeneous parenchyma hyperechoic to liver and renal cortical parenchyma. The capsule was smooth without noticeable expansion or deviation from within the spleen or adjacent pathology. The splenic vasculature demonstrated normal volume without signs of congestion or thrombosis. No sonographic evidence of acute or chronic inflammatory, neoplastic, or infarctual changes were noted.

Canine

BREED

German Shepherd

Liver

SEX

The **liver** revealed uniform enlargement. The gallbladder and common bile duct were unremarkable. The hepatic veins were dilated owing to passive congestion from emerging right sided heart failure.

Spayed Female

Gastrointestinal

AGE

Examination of the **gastrointestinal tract** revealed a stomach and intestine free of stasis, of normal wall thickness, acceptable curvilinear mural detail, and peristaltic activity. Small and large intestine demonstrated normal luminal chyme and stool consistency respectively. No obstructive or overt infiltrative disease was noted. No associated abnormal lymphatic activity was noted.

5 Years 5 Months

WEIGHT

113

Pancreas

The base and limbs of the **pancreas** were observed to be largely isoechoic to surrounding omental fat. Pancreatic duct and capsular contour were acceptably normal and parenchyma respected normal curvilinear patterns. No overt evidence of active inflammatory or neoplastic disease was noted.

INTERPRETED BY

Eric Lindquist, DMV,
DABVP (Canine &
Feline), Cert. IVUSS

ULTRASONOGRAPHIC FINDINGS

- Left and right sided heart failure- DCM type presentation
- Bradyarrhythmia
- Comet tail lung pattern
- Normal abdomen with passive congestion liver pattern

IMAGING PERFORMED BY

Heather

INTERPRETATION OF THE FINDINGS & FURTHER RECOMMENDATIONS

HOSPITAL NAME

ACC Flanders

If the patient was treated with Adriamycin, this may be a chemotherapeutic induced issue or idiopathic myocarditis. Taurine deficiency/nutritional cardiomyopathy are possible. Recommend initiating pimobendan at a dose of 0.3 mg/kg BID, Lasix at a dose of 2.0-3.0 mg/kg BID, ACE inhibitor 0.5 mg/kg SID, progressing to BID, and spironolactone at a dose of 1.0-2.0 mg/kg SID. Recheck echo in 7-14 days. Thyroid assessment is warranted. EKG is indicated. The patient is at risk for sudden death.

REFERRING VET

Dr. Hallihan

INVOICE

36509

DATE

4/10/26



PATIENT

Stella Lowry

SPECIES

Canine

BREED

German Shepherd

SEX

Spayed Female

AGE

5 Years 5 Months

WEIGHT

113

INTERPRETED BY

Eric Lindquist, DMV,
DABVP (Canine & Feline), Cert. IVUS

IMAGING PERFORMED BY

Heather

HOSPITAL NAME

ACC Flanders

REFERRING VET

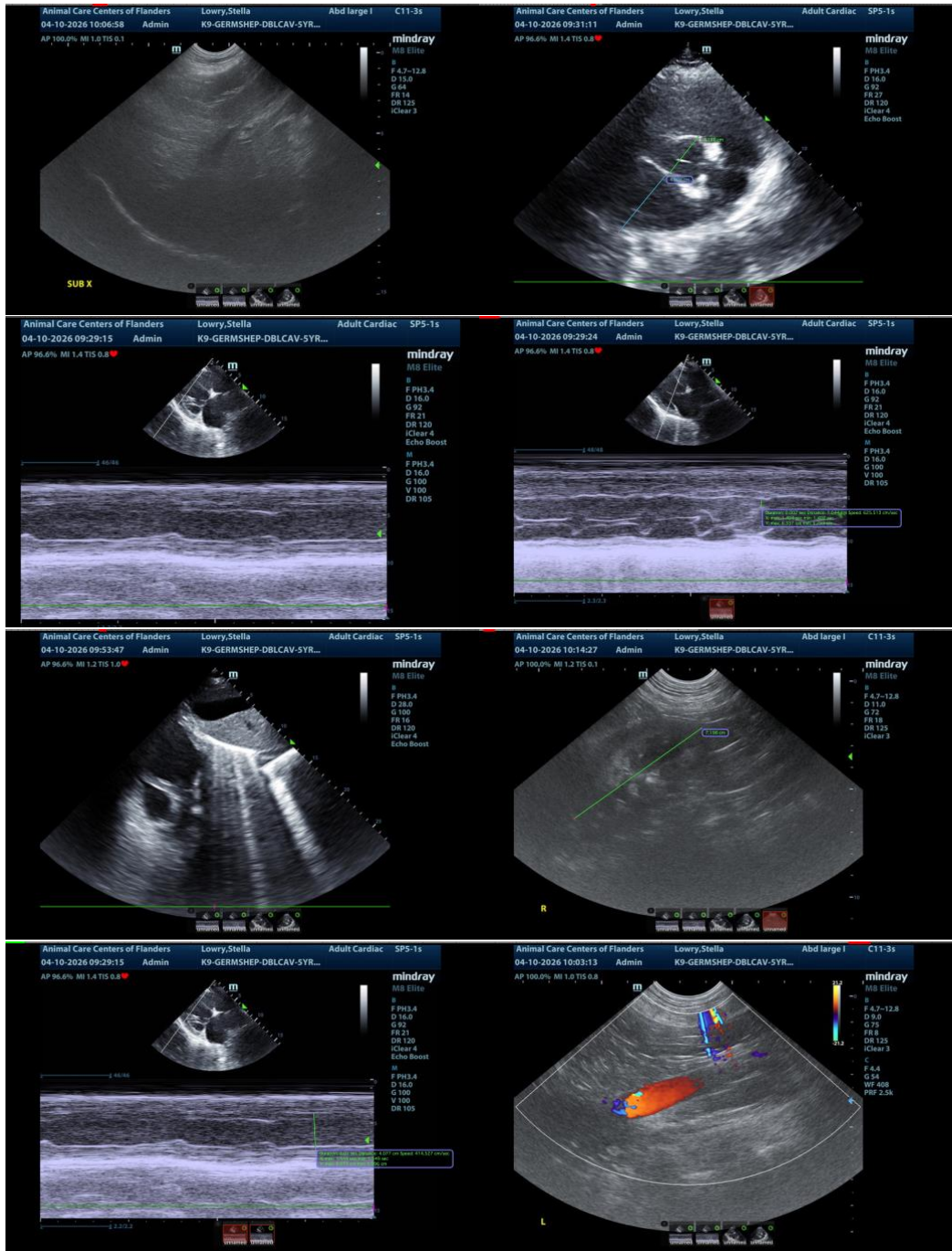
Dr. Hallihan

INVOICE

36509

DATE

4/10/26





PATIENT

Stella Lowry

SPECIES

Canine

BREED

German Shepherd

SEX

Spayed Female

AGE

5 Years 5 Months

WEIGHT

113

INTERPRETED BY

Eric Lindquist, DMV,
DABVP (Canine &
Feline), Cert. IVUSS

IMAGING PERFORMED BY

Heather

HOSPITAL NAME

ACC Flanders

REFERRING VET

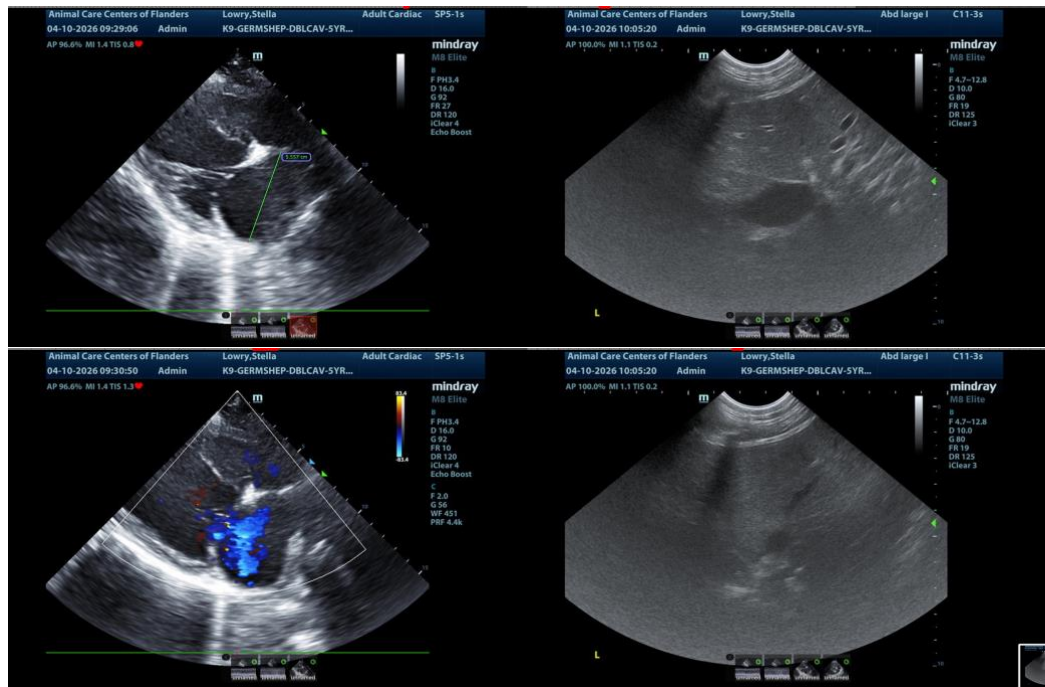
Dr. Hallihan

INVOICE

36509

DATE

4/10/26



The information and recommendations provided are based on the images presented by the referring veterinarian/sonographer. No evaluation can be communicated regarding pathology that was not visible in the image/video clips provided.

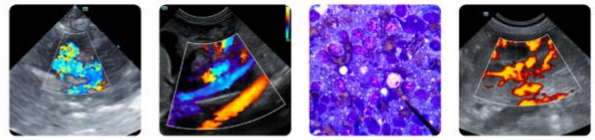
Thank you for this referral. If the clinical or image interpretation does not parallel your findings or if I can be of any further assistance please contact me.

Eric Lindquist, DMV, DABVP(CFM), Cert. IVUSS,
CEO, Owner, Founder -- SonoPath.com
info@SonoPath.com

Canine Dilated Cardiomyopathy

<http://www.sonopath.com/DilatedCMY>

Description: Dilated cardiomyopathy (DCM) is the most significant acquired cardiac disease of large to giant breed dogs; it especially affects Doberman Pinschers, Great Danes, and Labrador Retrievers. DCM is primarily a systolic dysfunction caused by a progressive decrease in myocardial contractility. As contractility worsens, all chambers of the heart progressively dilate and the walls become increasingly stiff as intracardiac pressure rises. The net result is reduced cardiac output, which causes a decrease in muscle perfusion. As the disease progresses, the left ventricle continues to dilate, causing the mitral valve annulus to widen; cardiac output is further reduced as a result of mitral regurgitation. The reduced cardiac output stimulates the sympathetic nervous



PATIENT

Stella Lowry

SPECIES

Canine

BREED

German Shepherd

SEX

Spayed Female

AGE

5 Years 5 Months

WEIGHT

113

INTERPRETED BY

Eric Lindquist, DMV,
DABVP (Canine &
Feline), Cert. IVUSS

IMAGING PERFORMED BY

Heather

HOSPITAL NAME

ACC Flanders

REFERRING VET

Dr. Hallihan

INVOICE

36509

DATE

4/10/26

system to increase preload (diastolic volume), heart rate, and peripheral vascular resistance. Consequently, there is an increase in volume and pressure, and clinically, it is at this stage of the disease that most animals develop pulmonary edema.

Although the most common etiology is idiopathic, it can also be the result of hypothyroidism, taurine deficiency, L-carnitine deficiency, parvovirus, Lyme disease, and possibly myocarditis. In Doberman Pinschers there is some evidence that there may be a causative genetic mutation. Doxorubicin chemotherapy may induce a DCM-type presentation due to its myocardial toxicity. In Boxers, it is possible for primary myocarditis to precipitate DCM in the later stages of the condition. Hypothyroidism may also be a complicating factor in DCM as it has the potential to further aggravate the systolic dysfunction.

Clinical signs: Clinical signs include weakness, lethargy, exercise intolerance, coughing, anorexia, ascites, syncope, tachypnea, and dyspnea. Pulses are weak and rapid, and often there are pulse deficits. Pulmonary crackles may be auscultated. Jugular distention and muffled heart sounds may also be present.

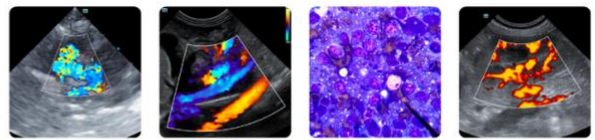
Diagnostics: It is possible that NT-proBNP testing will be utilized in the future to detect occult DCM. One recent study showed that NT-proBNP levels were higher in dogs with DCM as well as apparently healthy patients that went on to develop DCM within 1.5 years of the samples being obtained.

The echocardiographic parameters for diagnosing DCM include an increased left ventricular (LV) diameter, depressed fractional shortening, and increased EPSS (> 0.8 cm); there is the possibility of an enlarged left atrium. A recent study showed that the best discriminating value for differentiating healthy Doberman Pinschers from those with DCM was the LV diastolic diameter (> 48mm for male dogs and > 46 mm for female dogs).

Ideally, an ECG should be performed with a Holter monitor over a 24-hour period. Fifty to 100 VPCs are considered diagnostic for DCM in Doberman Pinschers when other systemic causes for arrhythmias have been excluded. The absence of detectable VPCs in the 5-minute ECG, however, should not lead to the assumption that the dog is healthy. Even one VPC in a 5-minute ECG strongly warrants further examination.

When congestive heart failure (CHF) develops, patients will exhibit an increased respiratory rate and there will be evidence of pulmonary edema on survey radiographs. One might also note elevated NT-proBNP levels.

Treatment: Pimobendan (0.25-0.3 mg/kg PO BID) is a phosphodiesterase inhibitor and positive inotropic medication. (Note: The latter is a more powerful positive inotrope than digoxin.) Studies have shown that pimobendan significantly prolongs survivability in Dobermans with DCM and CHF; their mean survival time was 329 days compared to 50 days for those in the placebo group. There was also clinical improvement in dogs that had CHF.



PATIENT

Stella Lowry

SPECIES

Canine

BREED

German Shepherd

SEX

Spayed Female

AGE

5 Years 5 Months

WEIGHT

113

INTERPRETED BY

Eric Lindquist, DMV,
DABVP (Canine &
Feline), Cert. IVUSS

IMAGING PERFORMED BY

Heather

HOSPITAL NAME

ACC Flanders

REFERRING VET

Dr. Hallihan

INVOICE

36509

DATE

4/10/26

Diuretics: Lasix should be administered at 2-4 mg/kg PO BID-TID as needed and subsequently reduced to the lowest tolerated dose to maintain respiratory comfort, which is approximately 2 mg/kg PO BID (higher doses will be required as the disease progresses). Spironolactone (0.5 mg/kg PO BID) is used primarily for its anti-aldosterone effect and to decrease remodeling of the heart. In human trials, the addition of spironolactone to standard therapy has been shown to increase life span in cases of CHF.

Angiotensin-converting enzyme (ACE) inhibitors: Enalapril (0.5 mg/kg BID) or benazepril (0.5 mg/kg PO Q12-24hr) therapy decreases systemic afterload, which diminishes the chamber stretching effects on the myocardium and thereby improves oxygen carrying capacity. A recent retrospective study showed that the early use of benazepril prolonged the onset of overt DCM in Dobermans with occult DCM.

Anti-arrhythmics: These should be used as needed. In cases of ventricular tachycardia where severe systolic dysfunction is a possibility, amiodarone (10 mg/kg PO Q24hr until stabilized and then 8 mg/kg PO Q24hr) and mexilitine (5-8 mg/kg PO TID) can be used. Although beta blockers, such as sotalol, can be used, they must be prescribed with extreme caution in dogs with severe systolic dysfunction as they have a decreased inotropic effect. Therapy for atrial fibrillation would include diltiazem (start at 0.5 mg/kg PO TID and increase to a target dose of 2 mg/kg PO TID) and/or digoxin, or amiodarone.

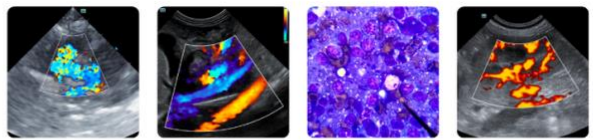
Carvedilol: Carvedilol is a calcium channel blocker, acts as a positive inotrope and free radical scavenger, and has ACE inhibiting effects. The target dose is approximately 1 mg/kg BID; it should be titrated up gradually from 0.25 mg/kg with dose adjustments made every 2 weeks until the ideal dose is reached.

Morphine: Morphine (0.025-0.05 mg/kg IV) decreases anxiety and improves respiratory efficiency and oxygen consumption. Morphine also dilates splanchnic vasculature and increases venous capacitance thereby reducing pulmonary edema.

Supplements: These may aid in some cases of DCM. In taurine-deficient patients (based on plasma or whole blood taurine levels), one should supplement taurine at 500 mg PO BID and L-carnitine at 175 mg/kg PO BID. Coenzyme Q10 is also used as a means of myocardial ischemic prevention (30-90mg BID). Omega-3 fatty acid supplements can help with cell membrane stabilization and be used as inflammatory mediators (EPA 40mg/kg, DHA 25mg/kg PO Q24hr).

Salt restriction: An optimized high-quality protein diet (4gm/100kcal) that is mildly restricted in salt should be considered to minimize the onset of sodium-induced volume overloads.

Monitoring: Serum chemistry (i.e., BUN/creatinine, electrolytes), blood pressure, and thoracic radiographs should be performed as needed 5-7 days after therapy has been initiated. One should conduct a follow-up echocardiogram in 1-6 months to assess myocardial function and the possible progression of the systolic dysfunction; medication should be changed or modified as needed. An



PATIENT

Stella Lowry

SPECIES

Canine

BREED

German Shepherd

SEX

Spayed Female

AGE

5 Years 5 Months

WEIGHT

113

INTERPRETED BY

Eric Lindquist, DMV,
DABVP (Canine &
Feline), Cert. IVUSS

IMAGING PERFORMED BY

Heather

HOSPITAL NAME

ACC Flanders

REFERRING VET

Dr. Hallihan

INVOICE

36509

DATE

4/10/26

electrocardiogram should be repeated as needed to monitor arrhythmias and the patient's response to therapy. The best means of monitoring progress at home is to observe the resting respiratory rate. A study showed that the resting respiratory rate obtained at home was the strongest predictor of improving or worsening of CHF and/or pulmonary edema.

Prognosis: The prognosis is variable and largely dependent on the individual animal and its response to therapy.

References:

Fuentes VL, Corcoran B, French A, Schober KE, Kleemann R, Justus C. A double-blind, randomized, placebo-controlled study of pimobendan in dogs with dilated cardiomyopathy. *J Vet Intern Med.* 2002;16:255-261.

O'Grady MR, Minors SL, O'Sullivan ML, et al. Effect of pimobendan on case fatality rate in Doberman Pinschers with congestive heart failure caused by dilated cardiomyopathy. *J Vet Intern Med* 2008;22:897-904.

O'Grady MR, O'Sullivan ML, Minors SL, et al. Efficacy of benazepril hydrochloride to delay the progression of occult dilated cardiomyopathy in Doberman Pinschers. *J Vet Intern Med* 2009;23:977-83.

O'Grady MR, O'Sullivan ML, Pyle WG, et al. Evaluation of 10 genes encoding cardiac proteins in Doberman Pinschers with dilated cardiomyopathy. *Am J Vet Res* 2011;72:932-39.

Wess G, Butz V, Mahling M, et al. Evaluation of N-terminal pro-B-type natriuretic peptide as a diagnostic marker of various stages of cardiomyopathy in Doberman Pinschers. *Am J Vet Res* 2011;72:642-49.