

PATIENT

Rozy Yaw

SPECIES

Feline

BREED

DSH

SEX

Female

AGE

18 Months

WEIGHT

1.4 kg

INTERPRETED BY

Eric Lindquist, DMV,
DABVP (CFM), Cert.
IVUSS

IMAGING PERFORMED BY

Dr. Samad Khan

HOSPITAL NAME

The Veterinary Surgery
– Street 805

REFERRING VET

Dr. Samad Khan

INVOICE

74395

DATE

4/10/26

PRESENTING CLINICAL SIGNS

Not thriving well, anemia, ALT high, bilirubin mild high, pred and doxy

LIMITED ULTRASONOGRAPHIC EXAMINATION

Incomplete image set provided.

Thickened irregular renal cortices noted. The kidneys measured approximately 3.0-3.5 cm each.

The spleen presented a smooth homogeneous parenchyma hyperechoic to liver and renal cortical parenchyma. The capsule was smooth without noticeable expansion or deviation from within the spleen or adjacent pathology. The splenic vasculature demonstrated normal volume without signs of congestion or thrombosis. No sonographic evidence of acute or chronic inflammatory, neoplastic, or infarctual changes were noted.

The visible liver was unremarkable other than minor increased portal markings. Portal vein to vena cava ratio was 1:1.

Examination of the gastrointestinal tract revealed a stomach and intestine free of stasis, of normal wall thickness, acceptable curvilinear mural detail, and peristaltic activity. Small and large intestine demonstrated normal luminal chyme and stool consistency respectively. No obstructive or overt infiltrative disease was noted. No associated abnormal lymphatic activity was noted.

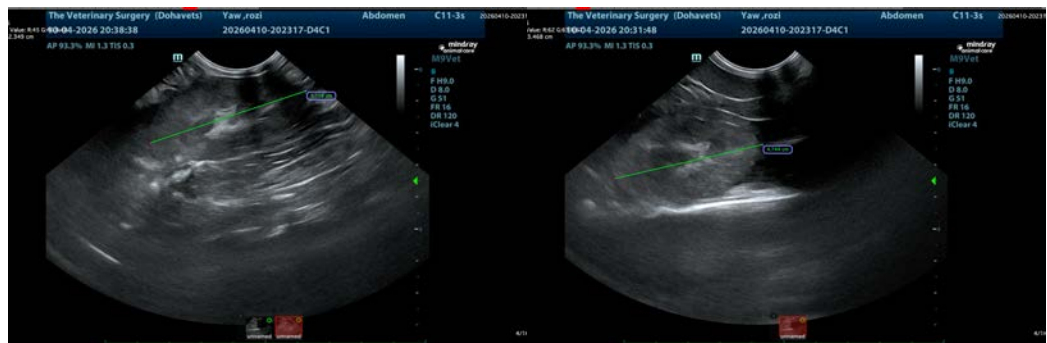
The pancreas was visible and uniform, no evident pathology.

ULTRASONOGRAPHIC FINDINGS

- Chronic irregular renal changes.
- Non-specific inflammatory hepatopathy.

INTERPRETATION OF THE FINDINGS & FURTHER RECOMMENDATIONS

Given the patient history, potential underlying FIP may be playing a role. No overt evidence of neoplasia. No evidence of portosystemic shunting. Underlying infectious disease may be playing a role. The Prednisolone may be suppressing a more significant presentation.





PATIENT

Rozy Yaw

SPECIES

Feline

BREED

DSH

SEX

Female

AGE

18 Months

WEIGHT

1.4 kg

INTERPRETED BY

Eric Lindquist, DMV,
DABVP (CFM), Cert.
IVUSS

IMAGING PERFORMED BY

Dr. Samad Khan

HOSPITAL NAME

The Veterinary Surgery
- Street 805

REFERRING VET

Dr. Samad Khan

INVOICE

74395

DATE

4/10/26

The information and recommendations provided are based on the images presented by the referring veterinarian/sonographer. No evaluation can be communicated regarding pathology that was not visible in the image/video clips provided.

Thank you for this referral. If the clinical or image interpretation does not parallel your findings or if I can be of any further assistance please contact me.

Eric Lindquist, DMV, DABVP(CFM), Cert. IVUSS,
CEO, Owner, Founder -- SonoPath.com
info@SonoPath.com