



PATIENT

Pouncey Welch

SPECIES

Feline

BREED

DSH

SEX

Spayed Female

AGE

16 Years

WEIGHT

9.6 lbs

INTERPRETED BY

Eric Lindquist, DMV,
DABVP (CFM), Cert.
IVUSS

IMAGING PERFORMED BY

Jocelyn Smith, CVT

HOSPITAL NAME

Annvil-Cleona
Veterinary Associates

REFERRING VET

Dr. Bruce Keck

INVOICE

74393

DATE

4/10/26

PRESENTING CLINICAL SIGNS

Lethargy / anorexia starting December - GI diagnostics came back inconclusive including maldigestion profile and AUS. Started PredL and GI diet (hill's biome). Seizure like episodes March 02, 2026 - since starting zonisamide, episodes have ceased. Gained 1lb from 2/11-4/8. Progressive labored breathing about 1 week ago. Pleural effusion on radiographs 4/8/26 - removed 100mL of fluid this day - patient improved some. started Lasix and continuing to improve. After fluid removal and starting lasix, patient back to normal weight.

Abnormal PE/Chem/CBC/UA Results: ProBNP snap test = Abnormal results Hyperthyroid - treating with methimazole Abdominal u/s (1/7/26) bloodwork attached

ULTRASONOGRAPHIC EXAMINATION OF THE HEART

FELINE CARDIAC PARAMETERS	BODY WEIGHT (lbs)	HR (BPM)	IVSd (cm)	LVIDd (cm)	LWVd (cm)	FS (%)	EF (%)
NORMAL PARAMETER	-----	150-240	0.3-0.6	1.0-2.1	0.25-0.6	35-67	80-100
PATIENT	9.6	NM	0.5	1.6	0.5	30	--
FELINE CARDIAC PARAMETERS	LA/AO (M-mode)	LA/AO HEART BASE (Sisson)	LAD LA MAX 4 Chamber		LVOT VEL. (m/s)	RVOT VEL. (m/s)	IVRT (m/)
NORMAL PARAMETER	<1.5	1.6	0.7-1.7		<1.6	<1.3	40-60
PATIENT	--	1.9	2.0		--	--	NM

Adapted from June Boon, Veterinary Echocardiography, 1998
Sisson D et al. JVIM 1991; 5: 232, Jacobs et al. Am J Vet Res 1985; 46:1705

Cardiac Presentation

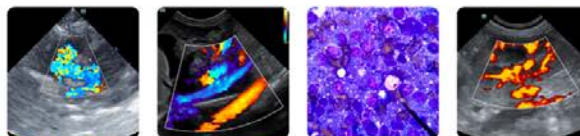
The cardiac presentation presented mild to moderate and left and severe right atrial enlargement, mainly on the LA max position. Septal and free wall thicknesses and left ventricular volumes were normal. Pericardial enlargement and pleural effusion noted, with variable areas of tissue consolidation in the dorsal thorax. Areas of lung consolidation also noted. Hepatic veins were also mildly dilated.

ULTRASONOGRAPHIC FINDINGS

- Pleural effusion with volume overload of the left and right heart with variable tissue consolidations in the thorax.

INTERPRETATION OF THE FINDINGS & FURTHER RECOMMENDATIONS

Unclassified cardiomyopathy with emerging left and right-sided failure. However, I'm concerned for extracardiac thoracic disease such as a neoplastic event. Pleurocentesis and immediate cytospin warranted. Lasix, Pimobendan, ACE inhibitor all indicated, with Plavix therapy. However, I'm concerned this is not a pure cardiogenic issue but a combination of both cardiogenic and non-cardiogenic pleural



PATIENT

Pouncey Welch

SPECIES

Feline

BREED

DSH

SEX

Spayed Female

AGE

16 Years

WEIGHT

9.6 lbs

INTERPRETED BY

Eric Lindquist, DMV,
DABVP (CFM), Cert.
IVUSS

IMAGING PERFORMED BY

Jocelyn Smith, CVT

HOSPITAL NAME

Annvile-Cleona
Veterinary Associates

REFERRING VET

Dr. Bruce Keck

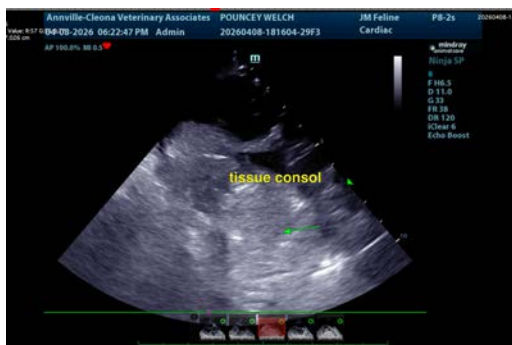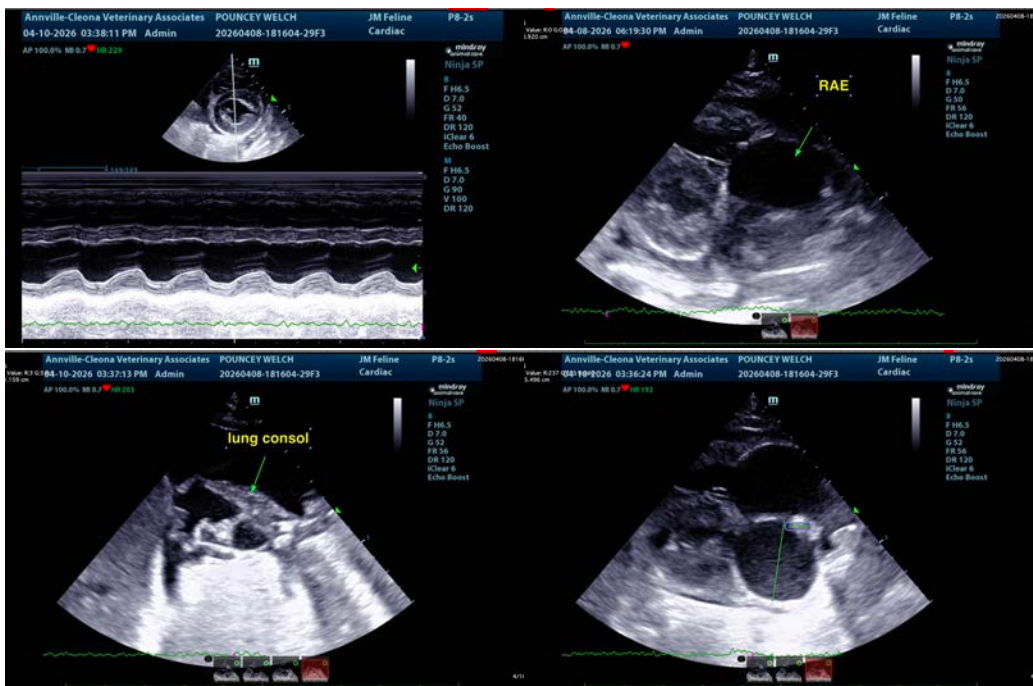
INVOICE

74393

DATE

4/10/26

effusion. Abdominal sonogram recommended for further definition and to assess for primary disease that may be playing a role. Recheck echocardiogram in one week.



The information and recommendations provided are based on the images presented by the referring veterinarian/sonographer. No evaluation can be communicated regarding pathology that was not visible in the image/video clips provided.

Thank you for this referral. If the clinical or image interpretation does not parallel your findings or if I can be of any further assistance please contact me.

Eric Lindquist, DMV, DABVP(CFM), Cert. IVUSS,
CEO, Owner, Founder -- SonoPath.com
info@SonoPath.com