



PATIENT

Maggie Valadez

SPECIES

Canine

BREED

Border Collie x

SEX

Spayed Female

AGE

8 Years 8 Months

WEIGHT

67.8 lbs

INTERPRETED BY

Eric Lindquist, DMV,
DABVP (CFM), Cert.
IVUS

IMAGING PERFORMED BY

Dr. Julie Kang

HOSPITAL NAME

Sabino Veterinary
Clinic

REFERRING VET

Dr. Julie Kang

INVOICE

74406

DATE

4/10/26

PRESENTING CLINICAL SIGNS

AUS/Echo to workup polycythemia with upward trend, determine underlying cause and ideal approach to treatment for long-term management, aside from PRN therapeutic phlebotomy.

Abnormal PE/Chem/CBC/UA Results: CBC - mod/marked polycythemia (RBC 11.0/HCT 78% <-- 10.0/72% in 7/2025 <-- 9.4/64% in 6/2024 <-- 9.7/70% in 7/2023 <-- 9.4/71 in 4/2024 <-- 9.9/70% in 11/2022 <-- 10.1/70% in 7/2022 <-- 10.4/72% in 3/2021). Chem10 - mild hyperglobulinemia (4.1 <-- 3.5/WNL in 7/2025), mild ALKP elevation (306 <-- 247 in 7/2025 <-- 77/WNL in 6/2024), IRIS stage 1. PT/APTT - WNL. Cocci - IgM/IgG negative.

ULTRASONOGRAPHIC EXAMINATION OF THE HEART & ABDOMEN

CANINE CARDIAC PARAMETERS	MR VMAX (m/s)	TR VMAX (m/s)	LA/AO (M-Mode)	LA/AO (Heart Base; Swe)	FS (%)	EF (%)	EPSS (cm)
NORMAL PARAMETER	4.5-5.5	<2.7	1.3	Up to 1.6	28-40	40-100	<0.6
PATIENT	--	--	1.0	1.3	30	58	0.2
CANINE CARDIAC PARAMETERS	HR (BPM)	AV VMAX (m/s)	PV MAX (m/s)	BODY WEIGHT (lbs)	LAD LA MAX 4 Chamber	LVIDd Avg; 2D and m-mode short axis (cm)	LVIDs Avg; 2D and m-mode short axis (cm)
NORMAL PARAMETER	50-100	0.7-1.7	0.7-1.6				
PATIENT	~50	1.5	1.0	67.8	4.97	4.46	--

Cardiac Presentation

The echocardiogram in this patient demonstrated normal **left atrial** size based on 3 separate methods of LA evaluation. Trivial mitral insufficiency noted, likely owing to sedation. The **left ventricle** presented thicknesses with linear contour and was not dilated nor restricted. The **myocardium** presented normal echogenicity without subjective evidence of significant fibrotic or ischemic disease. **Contractility** of the ventricular walls was adequate and in normal range for this patient evidenced by the fractional shortening measurement and subjective evaluation of the different regions of the myocardium. The **left ventricular outflow** tract demonstrated normal laminar flow and subjective structural integrity. The **right atrium** and auricle revealed normal size, structure and content. No evidence of masses was noted. Minor **tricuspid** insufficiency noted. The **right ventricle** was of normal size (1/3 diameter of LV), chordae structure, myocardial echogenicity and thickness. Trivial pulmonic insufficiency noted, likely secondary to sedation. No visible **pericardial** or free pleura fluid was noted. The cranial **mediastinum** and **pericardial and extra-cardiac regions** were free of masses in the visible window.

Given sedation, artificial volume overload noted in the left atrium on LA max position. Heart rate was slow owing to sedation.



PATIENT

Maggie Valadez

SPECIES

Canine

BREED

Border Collie x

SEX

Spayed Female

AGE

8 Years 8 Months

WEIGHT

67.8 lbs

INTERPRETED BY

Eric Lindquist, DMV,
DABVP (CFM), Cert.
IVUSS

IMAGING PERFORMED BY

Dr. Julie Kang

HOSPITAL NAME

Sabino Veterinary
Clinic

REFERRING VET

Dr. Julie Kang

INVOICE

74406

DATE

4/10/26

Urinary System

The **urinary bladder** presented normal thicknesses and normal tone. The ureters were not visible which is normal. No uroliths or sediment were visualized and anechoic urine was present. No evidence of inflammatory or neoplastic changes were noted. Ureteral papillae were normal. The pelvic urethra was imaged 3.0 cm beyond the cystourethral junction. Poor urethral tone noted.

The **kidneys** revealed normal size and structure, corticomedullary definition and ratio for this age. The cortices presented largely uniform texture with normal echogenic relationship to liver and spleen. Medullary structure differed distinctly from the cortex and no evidence of pelvic dilation was present. The capsules were acceptably uniform without significant irregularities. Left kidney measured 7.6 cm. Right kidney measured 7.37 cm.

Adrenal Glands

The **left adrenal gland** was enlarged, hypoechoic and expansive, measuring 3.57 cm x 1.43 cm at the cranial pole and 0.74 cm at the caudal pole. The left adrenal was imaged from both the right and left approach. No evidence of vascular invasion.

The **right adrenal gland** was somewhat flattened, measuring 0.52 cm.

Spleen

The **spleen** was mildly enlarged and folded upon itself cranially and caudally, not overtly pathological.

Liver

The **liver** images submitted revealed subjectively normal liver size, contour, and structure. Parenchymal echogenicity was naturally coarse and hypoechoic to the spleen. Vascular and biliary tracts were of normal volume with no evidence of congestion. The gallbladder presented acceptably thin walls with primarily anechoic content. The cystic and common bile ducts were normal. No pathological hepatic lymphadenopathy was evident. No overt structural evidence of inflammatory, infiltrative or regenerative pathology was evident.

Gastrointestinal

Examination of the **gastrointestinal tract** revealed a stomach and intestine free of stasis, of normal wall thickness, acceptable curvilinear mural detail, and peristaltic activity. Small and large intestine demonstrated normal luminal chyme and stool consistency respectively. No obstructive or overt infiltrative disease was noted. No associated abnormal lymphatic activity was noted.

Pancreas

The base and limbs of the **pancreas** were observed to be largely isoechoic to surrounding omental fat. Pancreatic duct and capsular contour were acceptably normal and parenchyma respected normal curvilinear patterns. No overt evidence of active inflammatory or neoplastic disease was noted.

ULTRASONOGRAPHIC FINDINGS

- Normal echocardiogram.
- Enlarged left adrenal gland – adenoma, adenocarcinoma, hyperplasia, pheochromocytoma all possible.
- Somewhat flattened right adrenal gland.



PATIENT

Maggie Valadez

SPECIES

Canine

BREED

Border Collie x

SEX

Spayed Female

AGE

8 Years 8 Months

WEIGHT

67.8 lbs

INTERPRETED BY

Eric Lindquist, DMV,
DABVP (CFM), Cert.
IVUSS

IMAGING PERFORMED BY

Dr. Julie Kang

HOSPITAL NAME

Sabino Veterinary
Clinic

REFERRING VET

Dr. Julie Kang

INVOICE

74406

DATE

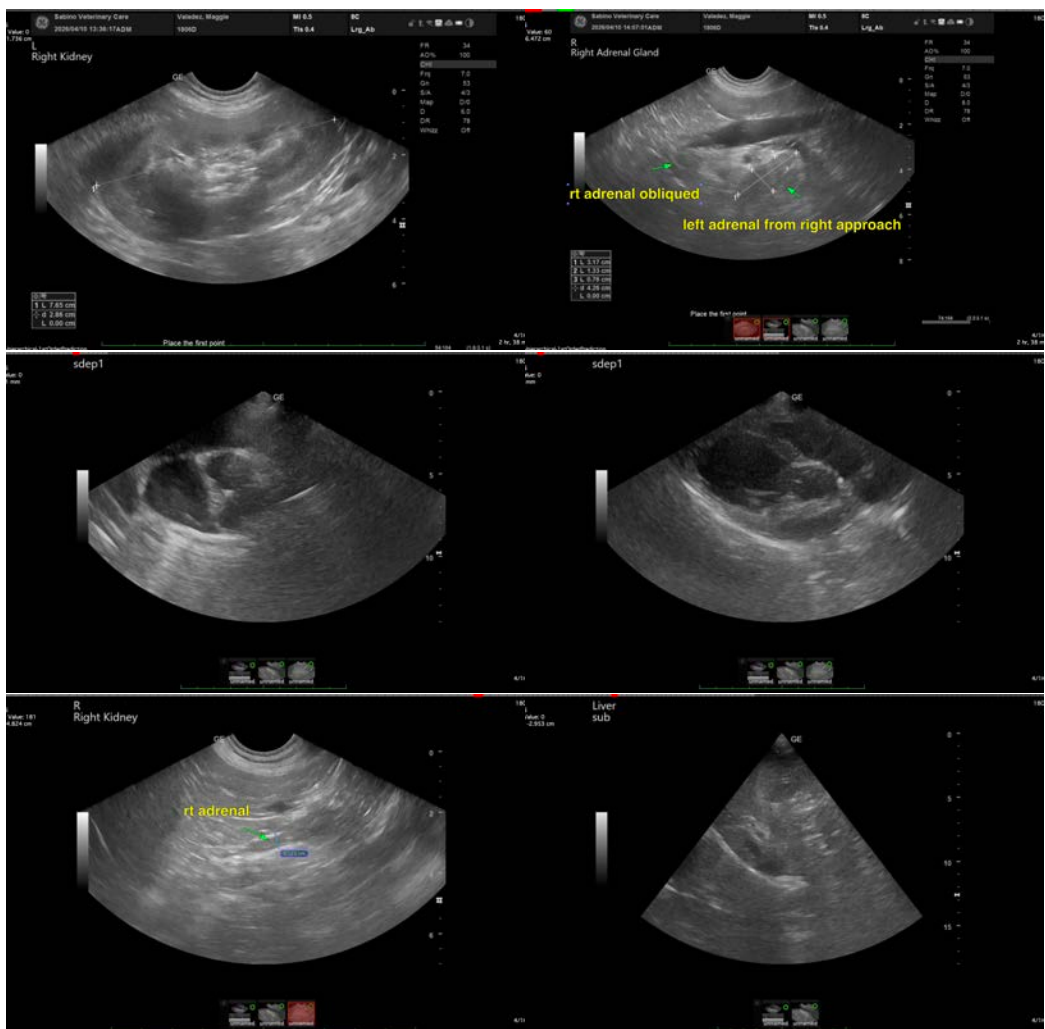
4/10/26

- Mildly enlarged, folded spleen.

INTERPRETATION OF THE FINDINGS & FURTHER RECOMMENDATIONS

No evidence of primary disease responsible for the polycythemia. Assessment for history of incontinence or recurrent UTIs indicated. CBC/path review and bone marrow aspirates indicated. Screening FNA of the spleen would also be indicated.

Serial blood pressure measurements are recommended in this patient. If hypertension is an issue metanephrine level is recommended. If the patient appears Cushingoid and urine specific gravity is less than 1.020 then work-up for adrenal dependent Cushing's is indicated. Recheck is recommended in 2-3 weeks to assess for any progression of the adrenal gland.





PATIENT

Maggie Valadez

SPECIES

Canine

BREED

Border Collie x

SEX

Spayed Female

AGE

8 Years 8 Months

WEIGHT

67.8 lbs

INTERPRETED BY

Eric Lindquist, DMV,
DABVP (CFM), Cert.
IVUSS

IMAGING PERFORMED BY

Dr. Julie Kang

HOSPITAL NAME

Sabino Veterinary
Clinic

REFERRING VET

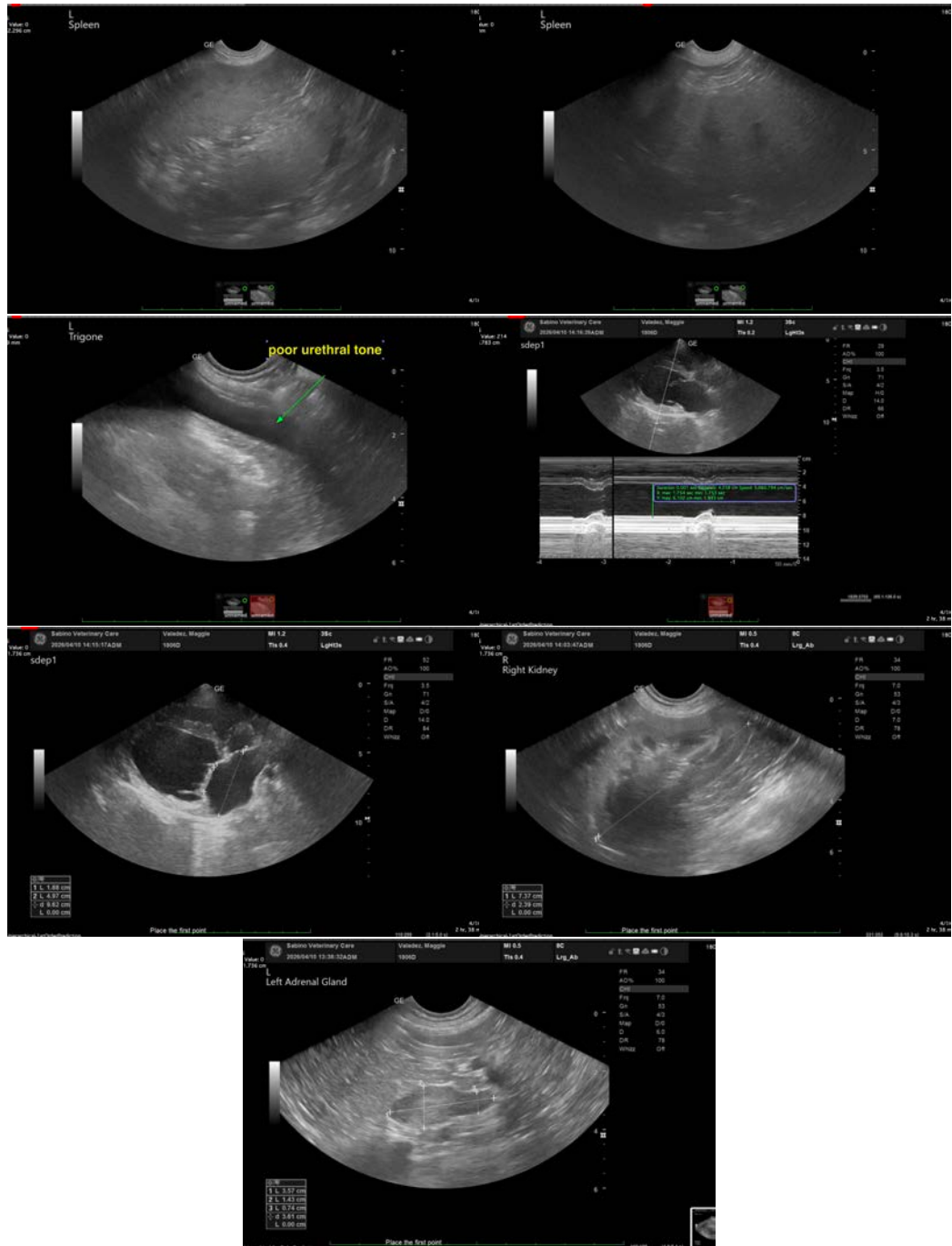
Dr. Julie Kang

INVOICE

74406

DATE

4/10/26





PATIENT

Maggie Valadez

SPECIES

Canine

BREED

Border Collie x

SEX

Spayed Female

AGE

8 Years 8 Months

WEIGHT

67.8 lbs

INTERPRETED BY

Eric Lindquist, DMV,
DABVP (CFM), Cert.
IVUSS

IMAGING PERFORMED BY

Dr. Julie Kang

HOSPITAL NAME

Sabino Veterinary
Clinic

REFERRING VET

Dr. Julie Kang

INVOICE

74406

DATE

4/10/26

The information and recommendations provided are based on the images presented by the referring veterinarian/sonographer. No evaluation can be communicated regarding pathology that was not visible in the image/video clips provided.

Thank you for this referral. If the clinical or image interpretation does not parallel your findings or if I can be of any further assistance please contact me.

Eric Lindquist, DMV, DABVP(CFM), Cert. IVUSS,
CEO, Owner, Founder -- SonoPath.com
info@SonoPath.com