



PATIENT

Junior Marte

SPECIES

Canine

BREED

Chihuahua

SEX

Male

AGE

8 Years 5 Months

WEIGHT

17.5 lbs

INTERPRETED BY

Eric Lindquist, DMV,
DABVP (CFM), Cert.
IVUSS

IMAGING PERFORMED BY

Carla

HOSPITAL NAME

Animal Care Clinic of
Flanders

REFERRING VET

Dr. Hargadon

INVOICE

74392

DATE

4/10/26

PRESENTING CLINICAL SIGNS

History of Stage B2 mitral disease. Echo completed on 10/2025. Symptoms worsening recently (cough). Grade III/VI systolic murmur. Harsh lung sounds. Distended abdomen

Meds: Trazodone 50mg - 1 tab po at 7:15am before scan, Lasix 12.5mg - 1 po bid, Enalapril 5mg 1 po bid, Spironolactone 25mg 1/2 po Sid, Vetmedin 5mg 1/2 po bid

Abnormal PE/Chem/CBC/UA Results: 4/3/26: Lat/VD abdomen - hepatomegaly, likely mild ascites present Lat/VD thorax - cardiomegaly, peri-hilar edema Radiographs attached 4/10/26: BP Average = 110 systolic

ULTRASONOGRAPHIC EXAMINATION OF THE HEART

CANINE CARDIAC PARAMETERS	MR VMAX (m/s)	TR VMAX (m/s)	LA/AO (M-Mode)	LA/AO (Heart Base; Swe)	FS (%)	EF (%)	EPSS (cm)
NORMAL PARAMETER	4.5-5.5	<2.7	1.3	Up to 1.6	28-40	40-100	<0.6
PATIENT	>5.0	2.0	NM	2.0	50	80	0.1
CANINE CARDIAC PARAMETERS	HR (BPM)	AV VMAX (m/s)	PV MAX (m/s)	BODY WEIGHT (lbs)	LAD LA MAX 4 Chamber	LVIDd Avg; 2D and m-mode short axis (cm)	LVIDs Avg; 2D and m-mode short axis (cm)
NORMAL PARAMETER	50-100	0.7-1.7	0.7-1.6				
PATIENT	140	1.2	0.9	17.5	3.4	3.1	--

Cardiac Presentation

The cardiac presentation presented mild volume overload of all four chambers, yet contractility was adequate. Mitral and tricuspid insufficiencies were persistent. No pericardial or pleural effusion.

ULTRASONOGRAPHIC FINDINGS

- Persistent volume overload, partially compensated valvular disease.

INTERPRETATION OF THE FINDINGS & FURTHER RECOMMENDATIONS

Recommend increasing Lasix by 1mg/kg BID and recheck echo in three months, earlier if clinical signs initiate and/or based on radiographic findings. Monitoring of BUN, blood pressure and creatinine all indicated.



PATIENT

Junior Marte

SPECIES

Canine

BREED

Chihuahua

SEX

Male

AGE

8 Years 5 Months

WEIGHT

17.5 lbs

INTERPRETED BY

Eric Lindquist, DMV,
DABVP (CFM), Cert.
IVUSS

IMAGING PERFORMED BY

Carla

HOSPITAL NAME

Animal Care Clinic of
Flanders

REFERRING VET

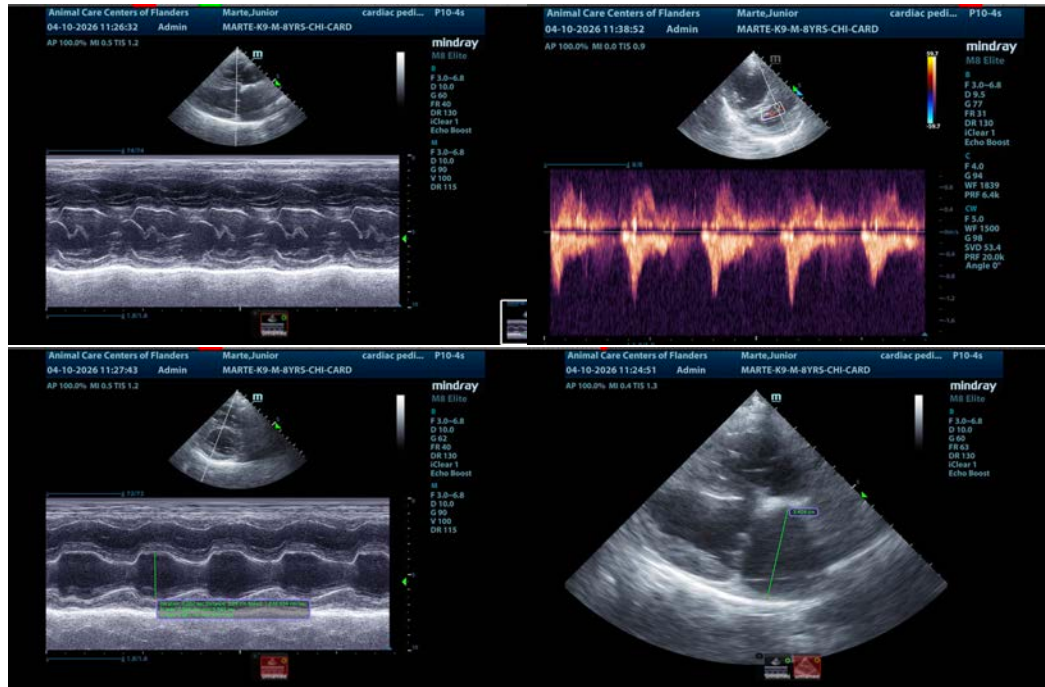
Dr. Hargadon

INVOICE

74392

DATE

4/10/26



The information and recommendations provided are based on the images presented by the referring veterinarian/sonographer. No evaluation can be communicated regarding pathology that was not visible in the image/video clips provided.

Thank you for this referral. If the clinical or image interpretation does not parallel your findings or if I can be of any further assistance please contact me.

Eric Lindquist, DMV, DABVP(CFM), Cert. IVUSS,
CEO, Owner, Founder -- SonoPath.com
info@SonoPath.com