



PATIENT

Hikari Jacobsen

SPECIES

Canine

BREED

Greyhound

SEX

Neutered Male

AGE

12 Years 2 Months

WEIGHT

59.6 Pounds

INTERPRETED BY

Eric Lindquist, DMV,
 DABVP (CFM), Cert.
 IVUSS

IMAGING PERFORMED BY

Chloe Lowe, CVT

HOSPITAL NAME

Black River VH

REFERRING VET

Dr. Gussman

INVOICE

36533

DATE

4/10/26

PRESENTING CLINICAL SIGNS

History: Last few weeks ADR. AFAST – multiple hyper echoic nodules on spleen (+/- myelolipomn?) Subjective potential splenomegaly. Tylosin, gabapentin, rimadyl, doxycycline. Abnormal PE/Chem/CBC/UA Results: UA Hematuria/ proteinuria USG 1.038

ULTRASONOGRAPHIC EXAMINATION OF THE ABDOMEN

Urinary System

The **urinary bladder**, trigone, and pelvic urethra presented normal thicknesses and normal tone. The ureters were not visible which is normal. No uroliths or sediment were visualized and anechoic urine was present. No evidence of inflammatory or neoplastic changes were noted. Ureteral papillae were normal. The pelvic urethra was imaged 2.0 cm beyond the cystourethral junction. The residual prostate measured 1.4 cm.

The **kidneys** revealed normal size and structure, corticomedullary definition and ratio for this age. The cortices presented largely uniform texture with normal echogenic relationship to liver and spleen. Medullary structure differed distinctly from the cortex, and no evidence of pelvic dilation was present. The capsules were acceptably uniform without significant irregularities. The left kidney measured 8.76 cm. The right kidney measured 8.2 cm.

Adrenal Glands

Both **adrenal glands** were visualized and recognized as having normal shape, size, position and echogenicity for this breed. The phrenic vasculature, glandular echogenicity and detail were unremarkable. Capsule, cortex, and medullary definition were normal for this age patient. The left adrenal gland measured 4.0 cm x 0.82 cm at the cranial pole and 0.82 cm at the caudal pole. The right adrenal gland measured 3.85 cm x 2.1 cm at the cranial pole and 0.58 cm at the caudal pole.

Spleen

The **spleen** revealed minor enlarged and was folded upon itself cranially. Hyperechoic lipid plaques were noted in the spleen, not pathological.

Liver

The **liver** images from right and left intercostal as well as subcostal views revealed subjectively normal liver size, contour, and structure. Some minor age-related parenchymal remodeling was noted but likely not clinically significant at this time. Vascular and biliary tracts were of normal volume, and no evidence of congestion was noted. The hepatic lymph nodes were unremarkable. Minor nonobstructive gallbladder calculus (2.7 cm) was also noted.

Gastrointestinal

Examination of the **gastrointestinal tract** revealed a stomach and intestine free of stasis, of normal wall thickness, acceptable curvilinear mural detail, and peristaltic activity. Small and large intestine demonstrated normal luminal chyme and stool consistency respectively. No obstructive or overt infiltrative disease was noted. No associated abnormal lymphatic activity was noted.

Pancreas



PATIENT

Hikari Jacobsen

SPECIES

Canine

BREED

Greyhound

SEX

Neutered Male

AGE

12 Years 2 Months

WEIGHT

59.6 Pounds

INTERPRETED BY

Eric Lindquist, DMV,
 DABVP (CFM), Cert.
 IVUSS

IMAGING PERFORMED BY

Chloe Lowe, CVT

HOSPITAL NAME

Black River VH

REFERRING VET

Dr. Gussman

INVOICE

36533

DATE

4/10/26

The base and limbs of the **pancreas** were observed to be largely isoechoic to surrounding omental fat. Pancreatic duct and capsular contour were acceptably normal and parenchyma respected normal curvilinear patterns. No overt evidence of active inflammatory or neoplastic disease was noted.

Other

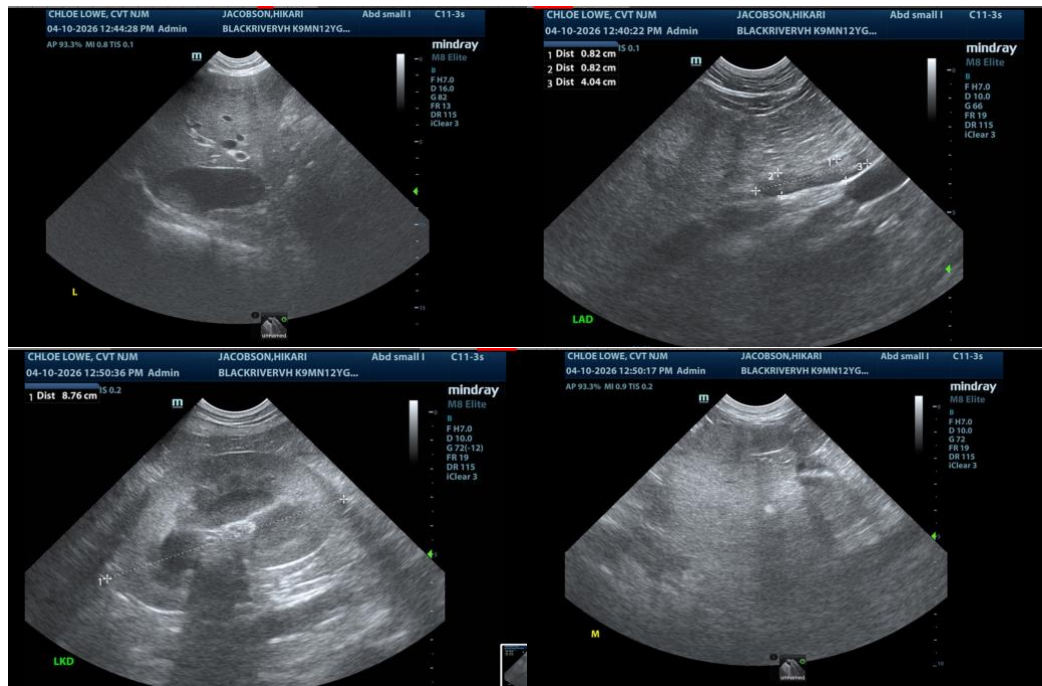
A rapid view of the **heart** revealed no evident pathology in the right auricle or pericardium.

ULTRASONOGRAPHIC FINDINGS

- Minor splenomegaly with lipid plaques, not overtly pathological
- Minor gallbladder calculus, nonobstructive.
- Age-related abdominal changes otherwise

INTERPRETATION OF THE FINDINGS & FURTHER RECOMMENDATIONS

Causes of immune stimulation should be investigated in this patient, such as tick-borne disease. Proactive ursodiol therapy could be considered in an attempt to dissolve the calculus. The spleen does not appear overtly pathological, yet FNA could be considered for further definition.





PATIENT

Hikari Jacobsen

SPECIES

Canine

BREED

Greyhound

SEX

Neutered Male

AGE

12 Years 2 Months

WEIGHT

59.6 Pounds

INTERPRETED BY

Eric Lindquist, DMV,
 DABVP (CFM), Cert.
 IVUSS

IMAGING PERFORMED BY

Chloe Lowe, CVT

HOSPITAL NAME

Black River VH

REFERRING VET

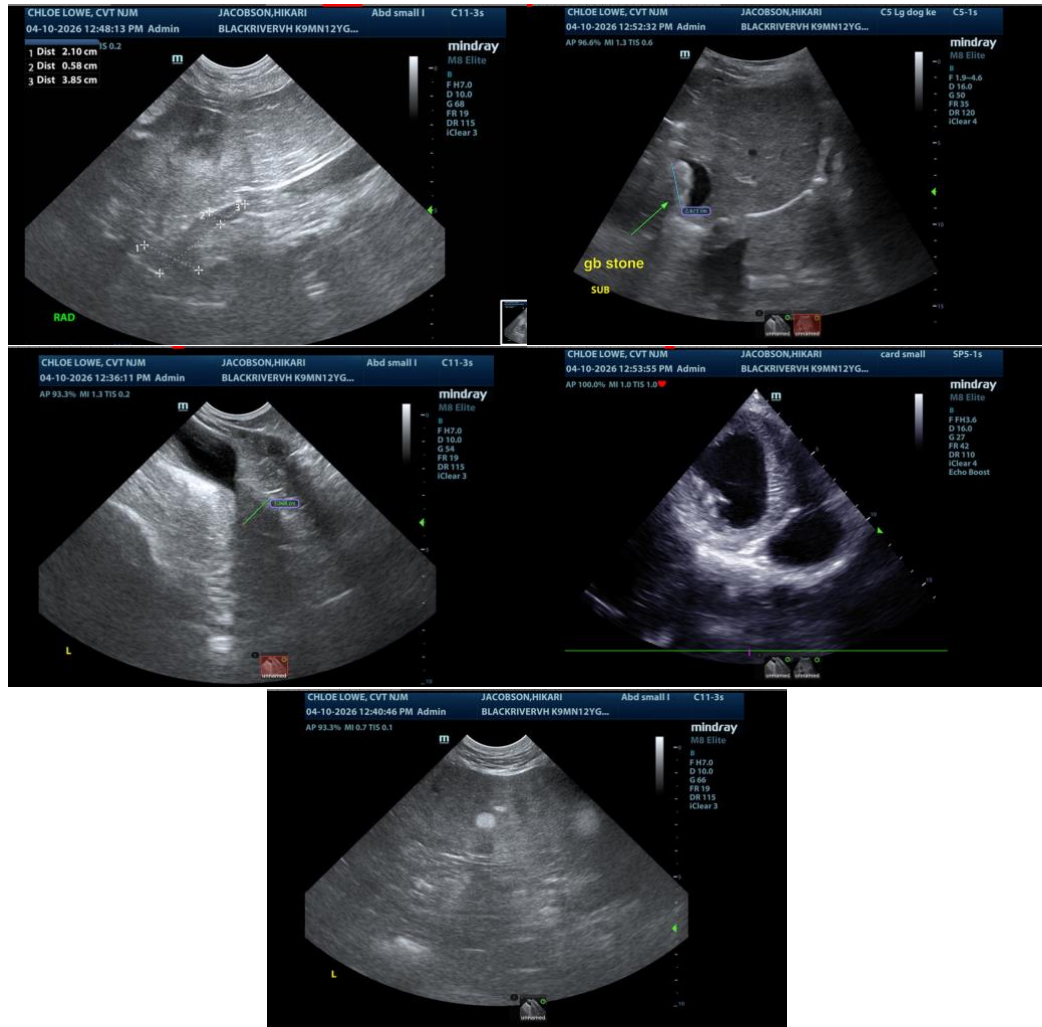Dr. Gussman

INVOICE

36533

DATE

4/10/26



The information and recommendations provided are based on the images presented by the referring veterinarian/sonographer. No evaluation can be communicated regarding pathology that was not visible in the image/video clips provided.

Thank you for this referral. If the clinical or image interpretation does not parallel your findings or if I can be of any further assistance please contact me.

Eric Lindquist, DMV, DABVP(CFM), Cert. IVUSS,
 CEO, Owner, Founder -- SonoPath.com
info@SonoPath.com