



PATIENT

Froot Loop Spencer

SPECIES

Canine

BREED

Rat Terrier

SEX

Neutered Male

AGE

14 Years 10 Months

WEIGHT

9 lbs

INTERPRETED BY

Eric Lindquist, DMV,
DABVP (CFM), Cert.
IVUS

IMAGING PERFORMED BY

Dr. Kitz

HOSPITAL NAME

Woodlands Animal
Hospital

REFERRING VET

Dr. Kitz

INVOICE

74408

DATE

4/10/26

PRESENTING CLINICAL SIGNS

History of mitral valve disease. Last fall started having some weird episodes of collapse. We have since determined these are likely neurological and not cardiac in origin and he has been started on Zonisamide. Did a Holter and work up back in Nov. Patient is doing very well. Currently takes Vetmedin.

Abnormal PE/Chem/CBC/UA Results: Grade IV left parasternal systolic murmur

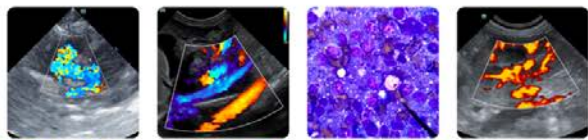
ULTRASONOGRAPHIC EXAMINATION OF THE HEART

CANINE CARDIAC PARAMETERS	MR VMAX (m/s)	TR VMAX (m/s)	LA/AO (M-Mode)	LA/AO (Heart Base; Swe)	FS (%)	EF (%)	EPSS (cm)
NORMAL PARAMETER	4.5-5.5	<2.7	1.3	Up to 1.6	28-40	40-100	<0.6
PATIENT	>5.0	2.92	1.7	1.8	47	80	NM
CANINE CARDIAC PARAMETERS	HR (BPM)	AV VMAX (m/s)	PV MAX (m/s)	BODY WEIGHT (lbs)	LAD LA MAX 4 Chamber	LVIDd Avg; 2D and m-mode short axis (cm)	LVIDs Avg; 2D and m-mode short axis (cm)
NORMAL PARAMETER	50-100	0.7-1.7	0.7-1.6				
PATIENT	--	1.2	1.0	9	3.5	2.34	--

E-wave velocity = 1.1

Cardiac Presentation

The echocardiogram for this patient presented excessive **left atrial size** expressed both in the LA/AO and LA max measurements Chamber volumes and echogenicity were normal. The cranial and caudal **mitral** valve leaflets presented vegetative thickening consistent with endocardiosis. Doppler indicated measurable insufficiency. Prolapse of the anterior mitral valve leaflet noted. The **left ventricle** presented thicknesses with linear contour and was not dilated nor restricted. The **myocardium** presented normal echogenicity without subjective evidence of significant fibrotic or ischemic disease. **Contractility** of the ventricular walls was adequate and in normal range for this patient evidenced by the fractional shortening measurement and subjective evaluation of the different regions of the myocardium. The **left ventricular outflow** tract demonstrated normal laminar flow and subjective structural integrity. The **right atrium** and auricle revealed normal size, structure and content. No evidence of masses was noted or chamber overload. **Tricuspid** insufficiency noted. The **right ventricle** was of normal size (1/3 diameter of LV), chordae structure, myocardial echogenicity and thickness. **Pulmonic** tract assessment revealed normal valve structure, laminar flow, and diameter (approx.1:1 pa/ao ratio). No visible **pericardial** or free pleura fluid was noted. No echographically detectable evidence of infiltrative disease was visible. The cranial **mediastinum and pericardial regions** were free of masses in the visible window.



PATIENT

Froot Loop Spencer

SPECIES

Canine

BREED

Rat Terrier

SEX

Neutered Male

AGE

14 Years 10 Months

WEIGHT

9 lbs

INTERPRETED BY

Eric Lindquist, DMV,
DABVP (CFM), Cert.
IVUSS

IMAGING PERFORMED BY

Dr. Kitz

HOSPITAL NAME

Woodlands Animal
Hospital

REFERRING VET

Dr. Kitz

INVOICE

74408

DATE

4/10/26

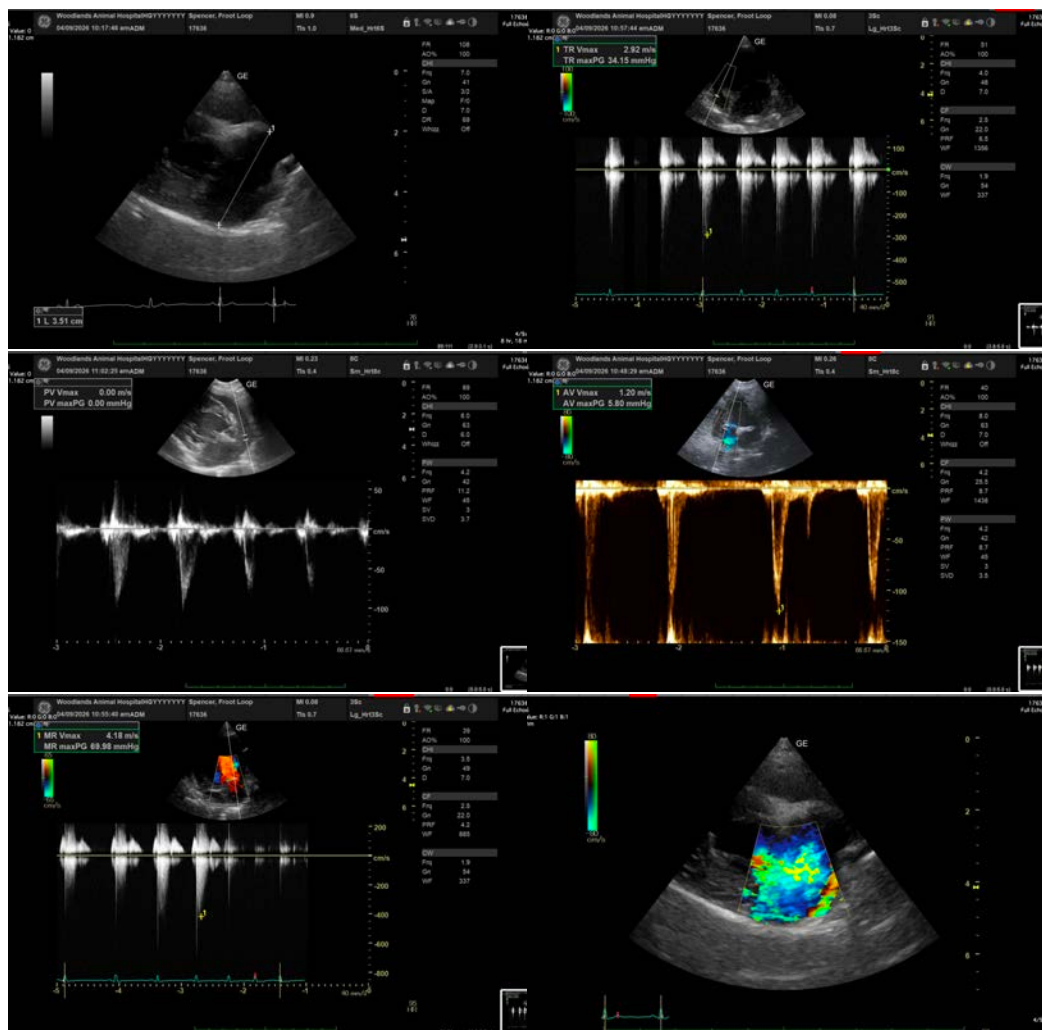
ULTRASONOGRAPHIC FINDINGS

- Early stage B2 valvular disease with mitral and tricuspid insufficiency and mild left atrial enlargement.

INTERPRETATION OF THE FINDINGS & FURTHER RECOMMENDATIONS

Recommend initiating Pimobendan at 0.3 mg/kg BID. If systolic blood pressure is >160, then adding ACE inhibitor would be indicated.

The heart has minor volume overload and is working to compensate for the valvular insufficiency. Target respiratory rate is < 20 resp/minute after therapy. After initiating or adjusting therapy, I recommend recheck on the clinical exam, BUN, Creatinine, USG, Chest radiographs & Blood pressure in 5-7 days. Recheck echo in 3-6 months, earlier if clinical decompensation is occurring. Minor anesthetic risk for a brief procedure at this time. Repeat preanesthetic echo is ideal if anesthesia is eventually necessary. A suggested anesthetic combination would involve torbutrol premed, propofol induction, isoflo maintenance or equivalent protocol.





PATIENT

Froot Loop Spencer

SPECIES

Canine

BREED

Rat Terrier

SEX

Neutered Male

AGE

14 Years 10 Months

WEIGHT

9 lbs

INTERPRETED BY

Eric Lindquist, DMV,
DABVP (CFM), Cert.
IVUSS

IMAGING PERFORMED BY

Dr. Kitz

HOSPITAL NAME

Woodlands Animal
Hospital

REFERRING VET

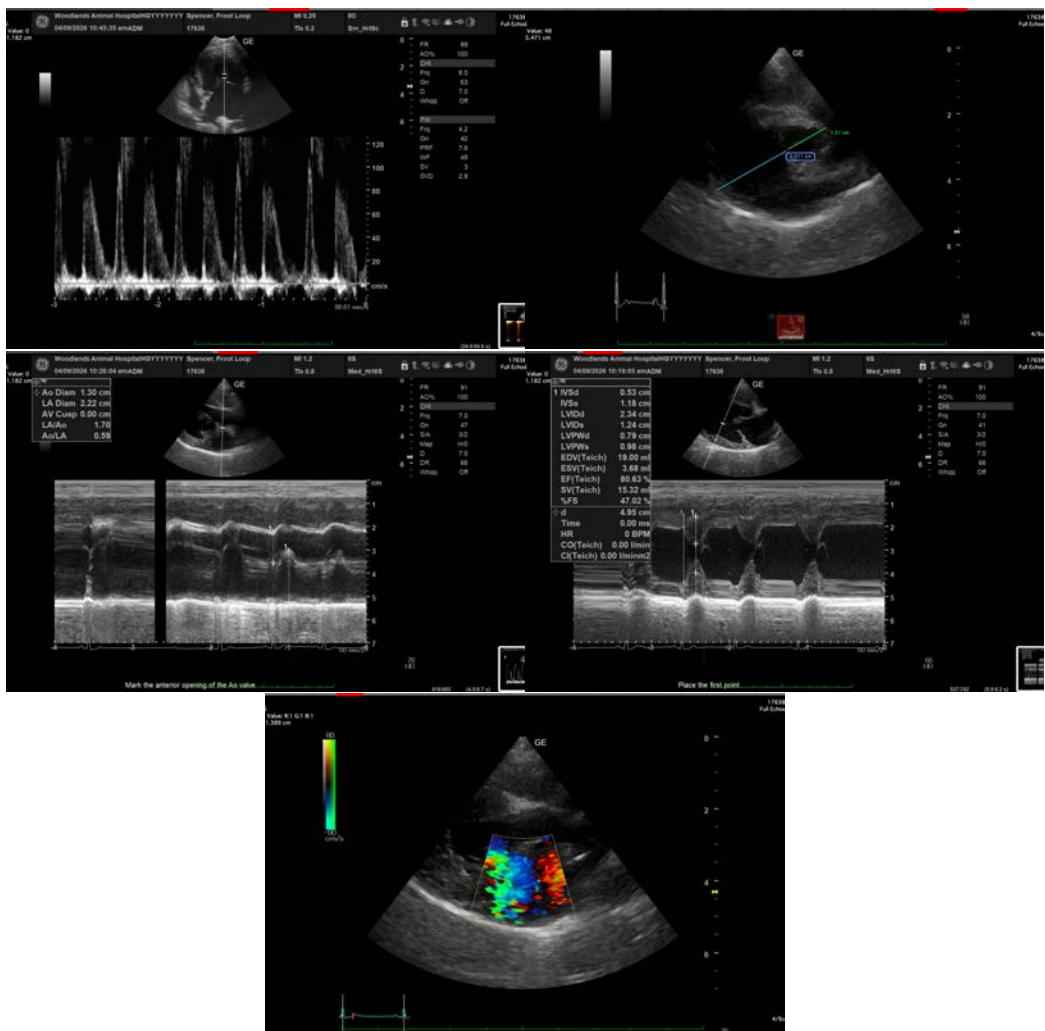
Dr. Kitz

INVOICE

74408

DATE

4/10/26



The information and recommendations provided are based on the images presented by the referring veterinarian/sonographer. No evaluation can be communicated regarding pathology that was not visible in the image/video clips provided.

Thank you for this referral. If the clinical or image interpretation does not parallel your findings or if I can be of any further assistance please contact me.

Eric Lindquist, DMV, DABVP(CFM), Cert. IVUSS,
CEO, Owner, Founder -- SonoPath.com
info@SonoPath.com