



PATIENT

Francesca Morales

SPECIES

Canine

BREED

Poodle mix

SEX

Spayed Female

AGE

7 Years

WEIGHT

26.1 Pounds

INTERPRETED BY

Eric Lindquist, DMV,
DABVP (CFM), Cert.
IVUSS

IMAGING PERFORMED BY

Meghan Morse, LVT,
CVT

HOSPITAL NAME

Newburgh VH

REFERRING VET

Dr. Harlec

INVOICE

36535

DATE

4/10/26

PRESENTING CLINICAL SIGNS

History: Chronic enteropathy, hx of pancreatitis, recent very elevated PSL and amylase, occasional v+, controlled w/ anti emetics.

Current meds: Cyclosporine 50mg SID, Famotidine 5mg BID, Denamarin, Fortiflora
Abnormal PE/Chem/CBC/UA Results: ALKP 775, Chol 327, Amylase 4951, PSL 6452

ULTRASONOGRAPHIC EXAMINATION OF THE ABDOMEN

Urinary System

The **urinary bladder**, trigone, and pelvic urethra presented normal thicknesses and normal tone. The ureters were not visible which is normal. No uroliths or sediment were visualized and anechoic urine was present. No evidence of inflammatory or neoplastic changes were noted. Ureteral papillae were normal. The pelvic urethra was imaged 2.0 cm beyond the cystourethral junction.

The **kidneys** revealed normal size and structure, corticomedullary definition and ratio for this age. The cortices presented largely uniform texture with normal echogenic relationship to liver and spleen. Medullary structure differed distinctly from the cortex, and no evidence of pelvic dilation was present. The capsules were acceptably uniform without significant irregularities. The left kidney measured 5.21 cm. The right kidney measured 5.34 cm.

Adrenal Glands

Both **adrenal glands** were visualized and recognized as having normal shape, size, position and echogenicity for this breed. The phrenic vasculature, glandular echogenicity and detail were unremarkable. Capsule, cortex, and medullary definition were normal for this age patient. The left adrenal gland measured 1.57 cm x 0.5 cm at the cranial pole and 0.54 cm at the caudal pole. The right adrenal gland measured 2.1 cm x 0.9 cm at the cranial pole and 0.51 cm at the caudal pole.

Spleen

The **spleen** presented a smooth homogeneous parenchyma hyperechoic to liver and renal cortical parenchyma. The capsule was smooth without noticeable expansion or deviation from within the spleen or adjacent pathology. The splenic vasculature demonstrated normal volume without signs of congestion or thrombosis. No sonographic evidence of acute or chronic inflammatory, neoplastic, or infarctual changes were noted.

Liver

The **liver** images submitted revealed subjectively normal liver size, contour, and structure. Parenchymal echogenicity was naturally coarse and hypoechoic to the spleen. Vascular and biliary tracts were of normal volume with no evidence of congestion. The gallbladder presented acceptably thin walls with primarily anechoic content. The cystic and common bile ducts were normal. No pathological hepatic lymphadenopathy was evident. No overt structural evidence of inflammatory, infiltrative or regenerative pathology was evident.

Gastrointestinal

Examination of the **gastrointestinal tract** revealed a stomach and intestine free of stasis, of normal wall thickness, acceptable curvilinear mural detail, and peristaltic activity. Small and large intestine



PATIENT

Francesca Morales

SPECIES

Canine

BREED

Poodle mix

SEX

Spayed Female

AGE

7 Years

WEIGHT

26.1 Pounds

INTERPRETED BY

Eric Lindquist, DMV,
DABVP (CFM), Cert.
IVUS

IMAGING PERFORMED BY

Meghan Morse, LVT,
CVT

HOSPITAL NAME

Newburgh VH

REFERRING VET

Dr. Harlec

INVOICE

36535

DATE

4/10/26

demonstrated normal luminal chyme and stool consistency respectively. No obstructive or overt infiltrative disease was noted. No associated abnormal lymphatic activity was noted.

Pancreas

The **pancreas** revealed mild prominent hypochoic parenchymal changes with slight irregular contour. Low grade inflammation is suspected.

ULTRASONOGRAPHIC FINDINGS

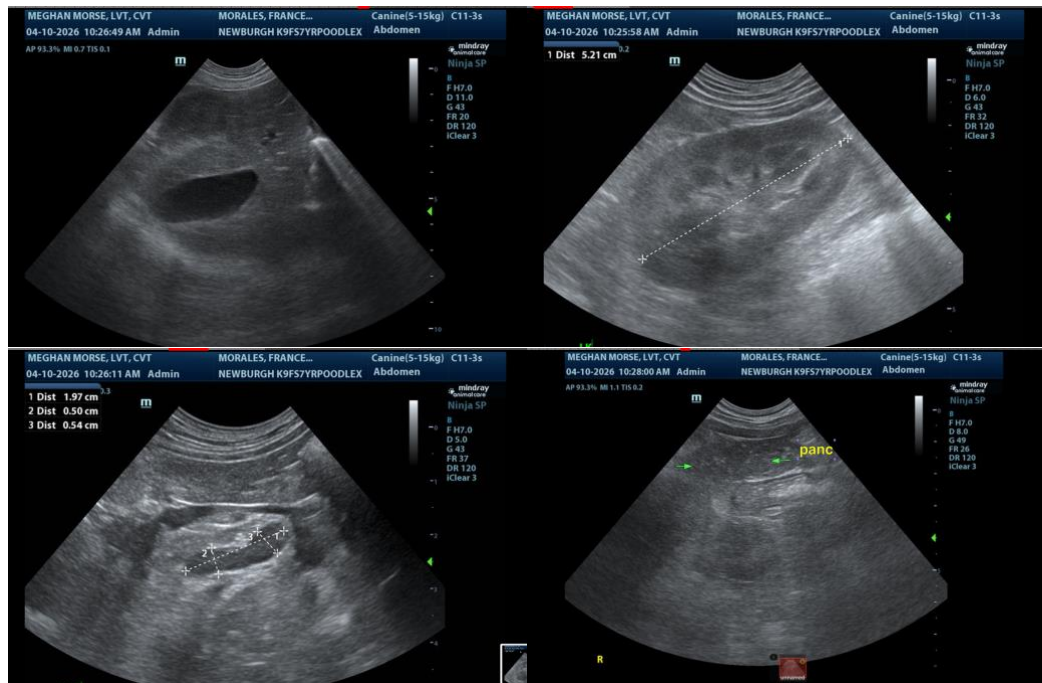
- Structurally normal GI tract
- Prominent pancreas – potential low-grade pancreatitis

INTERPRETATION OF THE FINDINGS & FURTHER RECOMMENDATIONS

Dietary intolerance, occult parasitism, structurally insignificant inflammatory bowel are all possible. Hydrolyzed diet is warranted if not already being utilized. No other evidence of structural disease.

For an additional charge, internal medicine consult can be utilized through Sonopath.com. You can select the internal medicine drop down at <http://spa.sonopath.com/>.

One of the world's top internists & SonoPath associate Dr. Remo Lobetti BVSc, MMedVet, PhD, DECVIM can evaluate your case through SonoPath. <https://sonopath.com/resources/sonopath-services/internal-medicine-teleconsultation-services>





PATIENT

Francesca Morales

SPECIES

Canine

BREED

Poodle mix

SEX

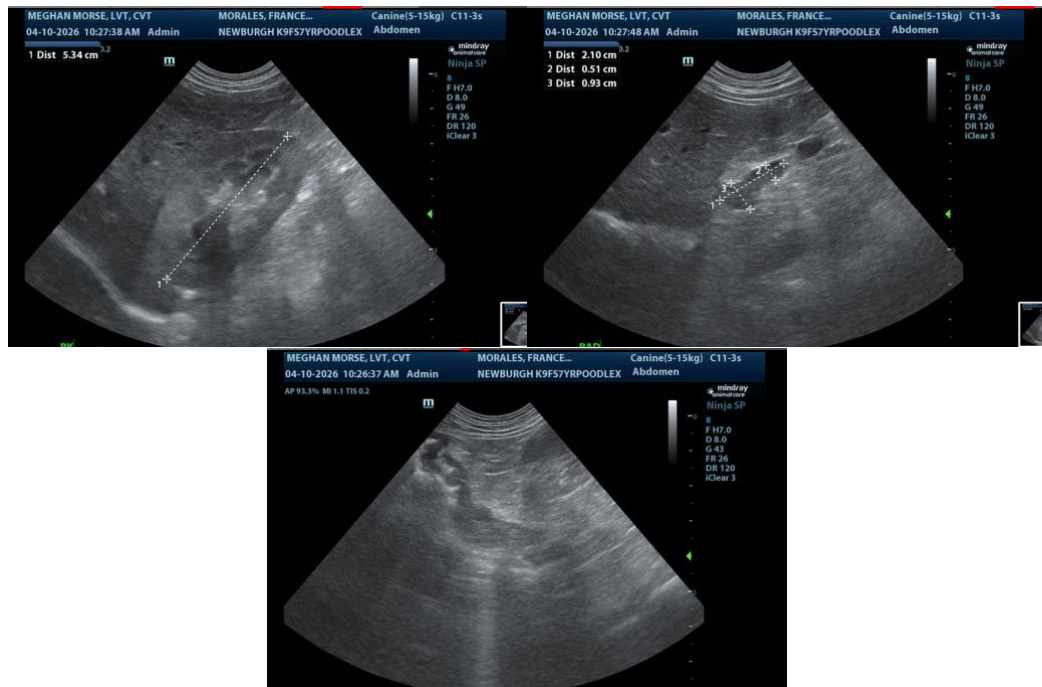
Spayed Female

AGE

7 Years

WEIGHT

26.1 Pounds



INTERPRETED BY

Eric Lindquist, DMV,
DABVP (CFM), Cert.
IVUSS

IMAGING PERFORMED BY

Meghan Morse, LVT,
CVT

HOSPITAL NAME

Newburgh VH

REFERRING VET

Dr. Harlec

INVOICE

36535

DATE

4/10/26

The information and recommendations provided are based on the images presented by the referring veterinarian/sonographer. No evaluation can be communicated regarding pathology that was not visible in the image/video clips provided.

Thank you for this referral. If the clinical or image interpretation does not parallel your findings or if I can be of any further assistance please contact me.

Eric Lindquist, DMV, DABVP(CFM), Cert. IVUSS,
CEO, Owner, Founder -- SonoPath.com
info@SonoPath.com