



PATIENT

Smoke Adkins

SPECIES

Canine

BREED

English Bulldog

SEX

Neutered male

AGE

9 years

WEIGHT

35.6 kg

INTERPRETED BY

Eric Lindquist, DMV
DABVP, Cert. IVUSS

IMAGING PERFORMED BY

Dr. White

HOSPITAL NAME

Lone Mountain AH

REFERRING VET

Dr. White

INVOICE

43768

DATE

4/10/23

PRESENTING CLINICAL SIGNS

History: 1 month history of decreased appetite. no vomiting/diarrhea/coughing. increasing abdomen size, losing weight/muscle tone. diet- grain free rachel ray PE: muffled heart sounds, no murmur appreciated. weak peripheral pulses. pale pink mm's abdominocentesis performed prior to US - 3000 ml of slight bloody watery fluid removed. cytology pending
Abnormal PE/Chem/CBC/UA Results: cbc/chem: normal cbc. hct-51%, tp 5.8, slight increase glucose 128 chest/abdomen xray report: multifocal moderate unstructured interstitial pulmonary pattern in R cranial, R middle and L cranial lobes. excessive sternal/pericardial fat deposition hinders cardiac silhouette evaluation. mild left sided cardiomegaly. severe volume peritoneal effusion

ULTRASONOGRAPHIC EXAMINATION OF THE ABDOMEN

Urinary System

The **urinary bladder** presented a relatively uniform thickening of the cranioventral and craniodorsal mucosae with micropolypoid mucosal changes without involvement of the submucosae. The urine presented some echogenicity consistent with suspended debris. No evidence of urethral pathology was present. This presentation is most consistent with chronic cystitis. Technically transitional cell carcinoma cannot be ruled out without histopathological review but is not overtly suspected based on this pattern. Cystocentesis and urine culture +/- pathological review of urine cytology would be warranted. No overt calculi were present at this time.

The **kidneys** revealed largely normal size and structure, corticomedullary definition and ratio (cortex 1/3 of medulla) were essentially maintained with some age-related loss of curvilinear patterns regarding the capsule and C/M junction. The cortices presented largely uniform texture with some increased echogenicity expected for his age patient. Medullary structure differed distinctly from that of the cortex and no evidence of pelvic dilation was present. The left kidney measured 6.0 cm.

Adrenal Glands

The **adrenal glands** were not visualized.

Spleen

The **spleen** in this patient was mildly enlarged with uniform parenchyma and was folded upon itself. This is a positional variant and is not pathological. There was no evidence of significant disease.

Liver

The **liver** revealed increased portal markings. Passive congestion liver pattern with dilated hepatic veins. The vena cava was dilated with a mild amount of ascites in the abdomen. The gallbladder and common bile duct were unremarkable.



PATIENT

Gastrointestinal

Smoke Adkins

The **gastrointestinal tract** revealed hyperperistalsis, yet was structurally unremarkable. Curvilinear patterns were noted.

SPECIES

Canine

Pancreas

The base and limbs of the **pancreas** were observed to be largely isoechoic to surrounding omental fat. Pancreatic duct and capsular contour were acceptably normal and parenchyma respected normal curvilinear patterns. No overt evidence of active inflammatory or neoplastic disease was noted.

BREED

English Bulldog

SEX

Neutered male

Free Abdomen

Free fluid was noted between the spleen and liver.

AGE

9 years

ULTRASONOGRAPHIC FINDINGS

Chronic cystitis bladder pattern with debris.

WEIGHT

35.6 kg

Ascites and passive congestion liver pattern. Suspect right sided heart failure or other causes of passive congestion.

Minor, heterogenous splenic changes.

INTERPRETED BY

Eric Lindquist, DMV
DABVP, Cert. IVUS

INTERPRETATION OF THE FINDINGS & FURTHER RECOMMENDATIONS

Full urinary work-up is warranted if not already performed. An echocardiogram and chest radiographs are warranted. Splenic and hepatic FNA can be justified, but subjectively appeared benign. The prognosis is guarded.

IMAGING PERFORMED BY

Dr. White

HOSPITAL NAME

Lone Mountain AH

REFERRING VET

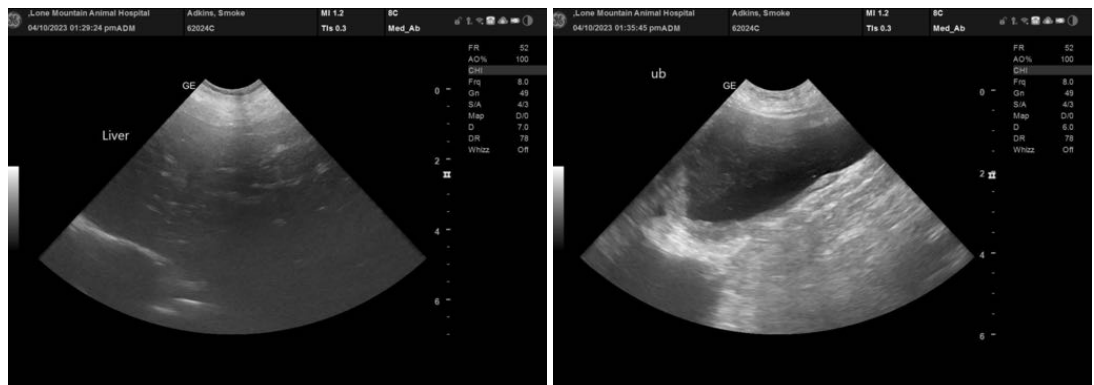
Dr. White

INVOICE

43768

DATE

4/10/23





PATIENT

Smoke Adkins

SPECIES

Canine

BREED

English Bulldog

SEX

Neutered male

AGE

9 years

WEIGHT

35.6 kg

INTERPRETED BY

Eric Lindquist, DMV
DABVP, Cert. IVUSS

IMAGING PERFORMED BY

Dr. White

HOSPITAL NAME

Lone Mountain AH

REFERRING VET

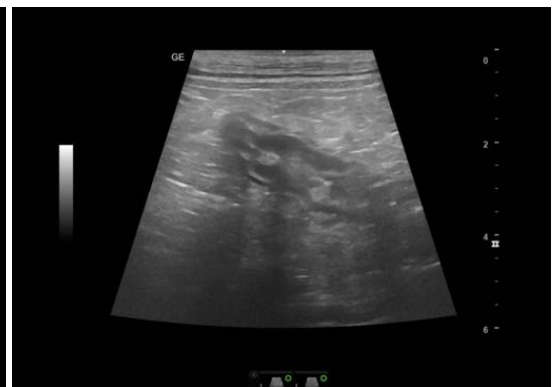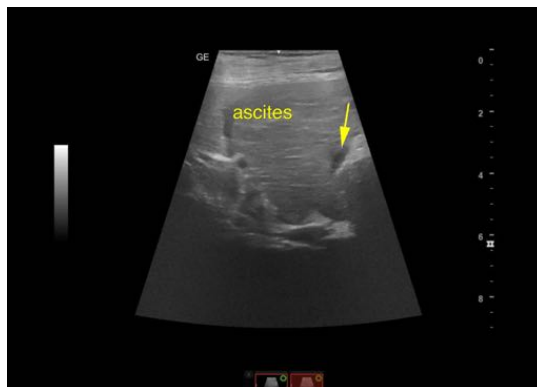
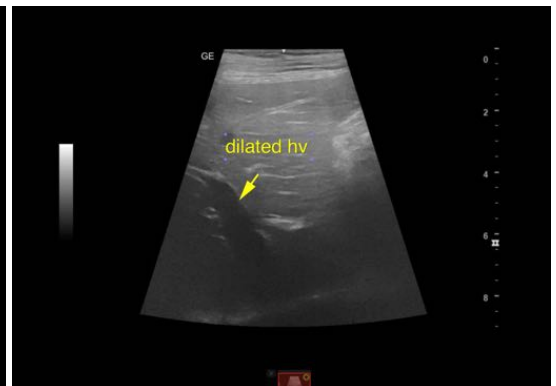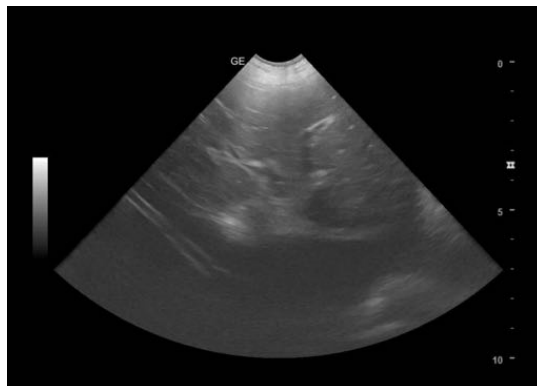
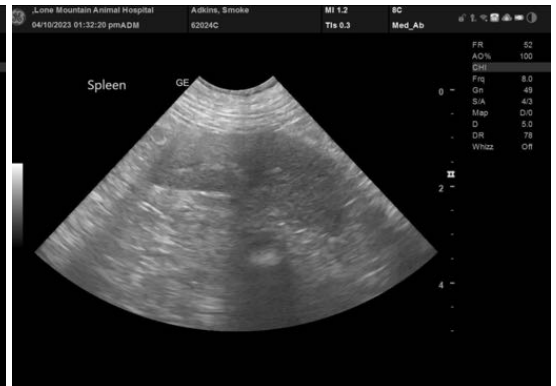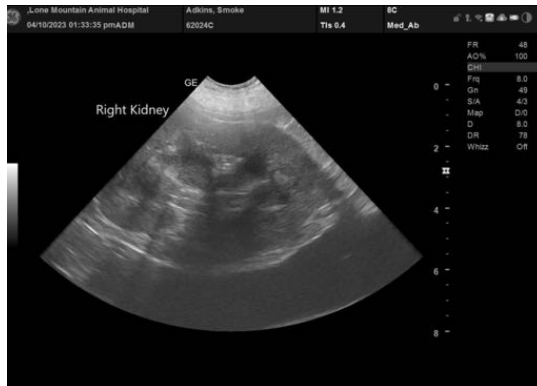Dr. White

INVOICE

43768

DATE

4/10/23



The information and recommendations provided are based on the images presented by the referring veterinarian/sonographer. No evaluation can be communicated regarding pathology that was not visible in the image/video clips provided.

Thank you for this referral. If the clinical or image interpretation does not parallel your findings or if I can be of any further assistance please contact me.

Eric Lindquist, DMV, DABVP, Cert. IVUSS, CEO of SonoPath.com
info@SonoPath.com