



**PATIENT**

Guinness Carlee

**SPECIES**

Canine

**BREED**

German Shepherd x

**SEX**

Spayed Female

**AGE**

14 Years 7 Months

**WEIGHT**

37 lbs

**INTERPRETED BY**

Eric Lindquist, DMV,  
DABVP (CFM), Cert.  
IVUSS

**IMAGING PERFORMED BY**

Vincent Ravancho, CVT

**HOSPITAL NAME**

Animal Paradise  
Hospital

**REFERRING VET**

Dr. Jacob

**INVOICE**

74125

**DATE**

4/1/26

**PRESENTING CLINICAL SIGNS**

Characterize the urinary bladder finding and guide prognosis. Blood in urine - intraluminal blood clot vs TCC

Abnormal PE/Chem/CBC/UA Results: From 3/30 - Diag - Cre 2.5, BUN 39, K 2.6, Glob 4.6

**ULTRASONOGRAPHIC EXAMINATION OF THE ABDOMEN**

**Urinary System**

The **urinary bladder** revealed an apical ventral mass with polypoid changes. Apical wall measured 1.17 cm. A polyp measured 1.5 cm. The pelvic urethra was imaged 2.0 cm beyond the cystourethral junction. The cystourethral junction and ureteral papilla were unremarkable. However, the aorta revealed a thrombus occupying approximately half of the aortic lumen in the aortic trifurcation. The thrombus measured at least 6.5 cm.

The **kidneys** revealed largely normal size and structure, corticomedullary definition and ratio (cortex 1/3 of medulla) were essentially maintained with some age-related loss of curvilinear patterns regarding the capsule and C/M junction. The cortices presented largely uniform texture with some increased echogenicity expected for his age patient. Medullary structure differed distinctly from that of the cortex. Left kidney measured 3.7 cm. Right kidney measured 5.51 cm with slight pyelectasia noted.

**Adrenal Glands**

The **left adrenal gland** was enlarged, uniform, measuring 1.16 cm at the cranial pole and 1.16 cm at the caudal pole.

The **right adrenal gland** was enlarged, irregular and nodular, measuring 1.8 cm x 1.68 cm.

**Spleen**

The **spleen** presented a smooth homogeneous parenchyma hyperechoic to liver and renal cortical parenchyma. The capsule was smooth without noticeable expansion or deviation from within the spleen or adjacent pathology. The splenic vasculature demonstrated normal volume without signs of congestion or thrombosis. No sonographic evidence of acute or chronic inflammatory, neoplastic, or infarctual changes were noted.

**Liver**

The **liver** images submitted revealed subjectively normal liver size, contour, and structure. Parenchymal echogenicity was naturally coarse and hypoechoic to the spleen. Vascular and biliary tracts were of normal volume with no evidence of congestion. The gallbladder presented acceptably thin walls with primarily anechoic content. The cystic and common bile ducts were normal. No pathological hepatic lymphadenopathy was evident. No overt structural evidence of inflammatory, infiltrative or regenerative pathology was evident.

**Gastrointestinal**

Examination of the **gastrointestinal tract** revealed a stomach and intestine free of stasis, of normal wall thickness, acceptable curvilinear mural detail, and peristaltic activity. Small and large intestine demonstrated normal luminal chyme and stool consistency respectively. No obstructive or overt infiltrative disease was noted. No associated abnormal lymphatic activity was noted.



**PATIENT**

Guinness Carlee

**SPECIES**

Canine

**BREED**

German Shepherd x

**SEX**

Spayed Female

**AGE**

14 Years 7 Months

**WEIGHT**

37 lbs

**INTERPRETED BY**

Eric Lindquist, DMV,  
DABVP (CFM), Cert.  
IVUSS

**IMAGING PERFORMED BY**

Vincent Ravancho, CVT

**HOSPITAL NAME**

Animal Paradise  
Hospital

**REFERRING VET**

Dr. Jacob

**INVOICE**

74125

**DATE**

4/1/26

**Pancreas**

The base and limbs of the **pancreas** were observed to be largely isoechoic to surrounding omental fat. Pancreatic duct and capsular contour were acceptably normal and parenchyma respected normal curvilinear patterns. No overt evidence of active inflammatory or neoplastic disease was noted.

**ULTRASONOGRAPHIC FINDINGS**

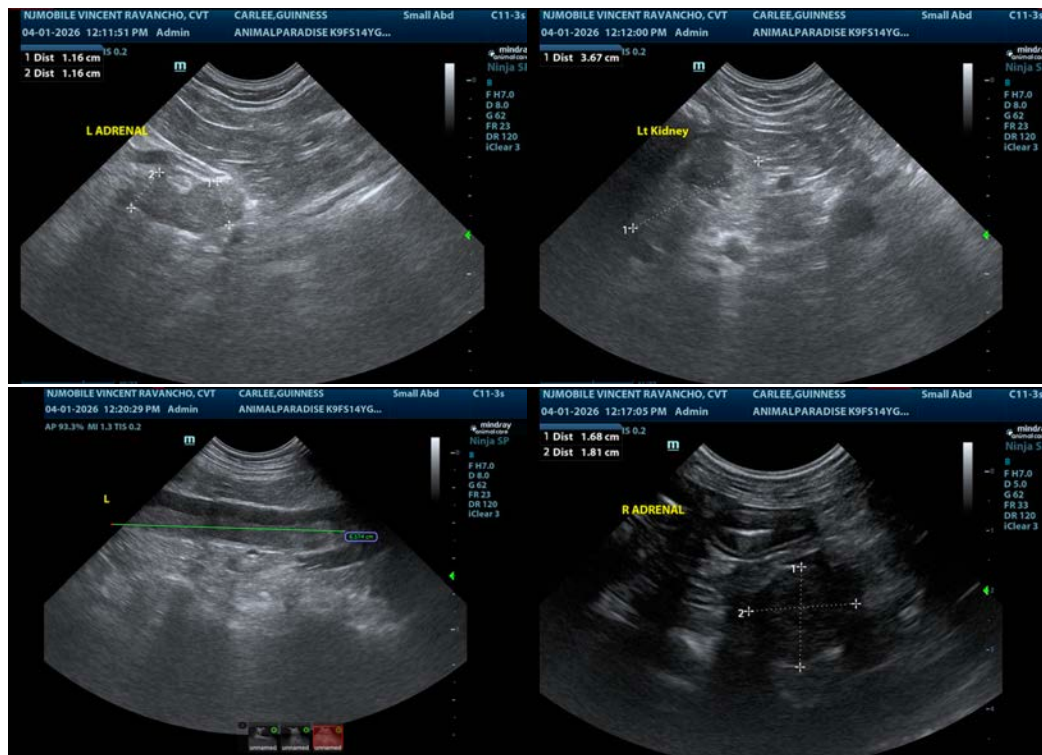
- Bladder mass and polyps, appear resectable – Polypoid changes most consistent with carcinoma.
- Aortic thrombus.
- Chronic renal changes – Consistent with near end stage renal disease.
- Enlarged adrenal glands with nodular changes on the right – Either adrenal may represent a pheochromocytoma, carcinoma, adenoma, or hyperplasia.

**INTERPRETATION OF THE FINDINGS & FURTHER RECOMMENDATIONS**

The urinary bladder lesions do appear resectable with apical partial cystectomy. Full adrenal workup indicated. Full coagulation panel indicated. I'm concerned about long-term viability of the kidneys and the thrombotic presentation. Eventual CT of the adrenals would be ideal in this patient.

For an additional charge an internal medicine consult can be utilized through [Sonopath.com](http://sonopath.com). You can select the internal medicine drop down at <http://spa.sonopath.com/>.

One of the world's top internists & SonoPath associate Dr. Remo Lobetti BVSc, MMedVet, PhD, DECVIM can evaluate your case through SonoPath. <https://sonopath.com/resources/sonopath-services/internal-medicine-teleconsultation-services>





**PATIENT**

Guinness Carlee

**SPECIES**

Canine

**BREED**

German Shepherd x

**SEX**

Spayed Female

**AGE**

14 Years 7 Months

**WEIGHT**

37 lbs

**INTERPRETED BY**

Eric Lindquist, DMV,  
DABVP (CFM), Cert.  
IVUSS

**IMAGING PERFORMED BY**

Vincent Ravancho, CVT

**HOSPITAL NAME**

Animal Paradise  
Hospital

**REFERRING VET**

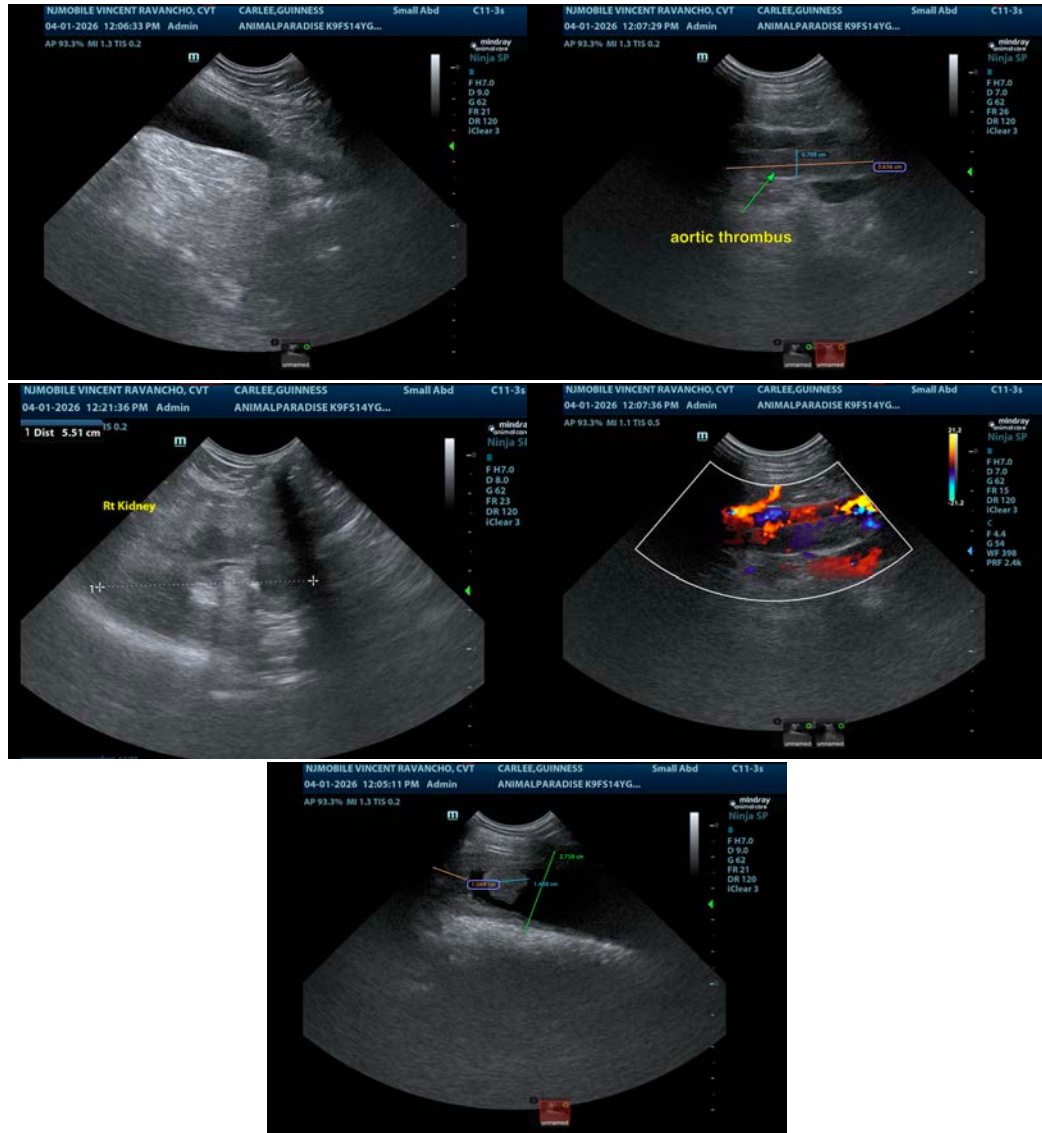
Dr. Jacob

**INVOICE**

74125

**DATE**

4/1/26



The information and recommendations provided are based on the images presented by the referring veterinarian/sonographer. No evaluation can be communicated regarding pathology that was not visible in the image/video clips provided.

Thank you for this referral. If the clinical or image interpretation does not parallel your findings or if I can be of any further assistance please contact me.

**Eric Lindquist**, DMV, DABVP(CFM), Cert. IVUSS,  
CEO, Owner, Founder -- SonoPath.com  
[info@SonoPath.com](mailto:info@SonoPath.com)



**PATIENT**

Guinness Carlee

**SPECIES**

Canine

**BREED**

German Shepherd x

**SEX**

Spayed Female

**AGE**

14 Years 7 Months

**WEIGHT**

37 lbs

**INTERPRETED BY**

Eric Lindquist, DMV,  
DABVP (CFM), Cert.  
IUUSS

**IMAGING PERFORMED BY**

Vincent Ravancho, CVT

**HOSPITAL NAME**

Animal Paradise  
Hospital

**REFERRING VET**

Dr. Jacob

**INVOICE**

74125

**DATE**

4/1/26

## Systemic Thromboembolic Disease

<http://www.sonopath.com/SystemicThrombo>

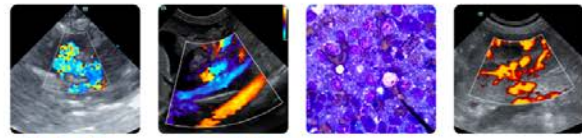
**Description:** Thrombosis is a clot formation within a blood vessel or cardiac lumen, while embolization occurs when a foreign body or clot fragment lodges within a lumen. Thromboembolic disease (TED) can be arterial or venous (i.e., in the vena cava or portal vein). The most prominent site of arterial embolization is the distal aortic trifurcation; it is referred to as a saddle thrombus and causes ischemia, myalgia, cold extremities, and cyanotic nail beds of the hind limbs. Other frequent embolization sites include the following:

- The renal parenchyma, leading to azotemia and hematuria as a result of infarction.
- The coronary arteries, inducing myocardial ischemia and arrhythmias.
- The mesenteric arteries, causing gastrointestinal symptoms and bacterial translocation.
- The cerebral vessels, inducing neurological signs and possibly sudden death.

Caval syndrome may also occur, resulting in edema in the front parts of the body. Portal vein thrombosis can also occur due to pancreatitis, hepatitis, neoplasia, or peritonitis. Microcirculation thrombosis and reperfusion injury are additional complicating factors in cases of TED.

Arterial thromboembolism (ATE) occurs when a thrombus develops in the left atrium and then moves to a distant site. In cases where pulmonary neoplastic cells have been found in the thrombus, those particular emboli may have originated in the lungs. Traditionally, this disease has been considered to carry a grave prognosis in all instances; approximately 35% of all feline patients are euthanized without attempted treatment. Yet, recent studies report a survival rate of approximately 40% with treatment. If cats survive the initial embolic event, re-embolization represents a likely cause of future morbidity and mortality (i.e., approximately 25% of patients will have recurrent thromboembolic episodes). Yet, mortality due to complications caused by underlying heart disease is three times more likely to result in morbidity than is recurrent ATE. Prognosis is determined by assessing the underlying cardiac disease, degree of vascular obstruction, and any underlying conditions of comorbidity. Paralysis of one limb carries a much better prognosis than if two limbs are affected.

Body temperature and congestive heart failure (CHF) are two key indicators of both short- and long-term survivability. In general, less than 50% of cats will survive to discharge, despite aggressive therapy. A correlation between body temperature and prognosis has been demonstrated: a body temperature of 100°F indicates a 73% survival rate; a core temperature of 99°F suggests a 50% survival rate; and at 97°F it is reasonable to expect 25% survival. The presence of CHF upon initial presentation does not affect survival to discharge but does make a significant difference in the long-term prognosis.



**PATIENT**

Guinness Carlee

**SPECIES**

Canine

**BREED**

German Shepherd x

**SEX**

Spayed Female

**AGE**

14 Years 7 Months

**WEIGHT**

37 lbs

**INTERPRETED BY**

Eric Lindquist, DMV,  
DABVP (CFM), Cert.  
IVUSS

**IMAGING PERFORMED BY**

Vincent Ravancho, CVT

**HOSPITAL NAME**

Animal Paradise  
Hospital

**REFERRING VET**

Dr. Jacob

**INVOICE**

74125

**DATE**

4/1/26

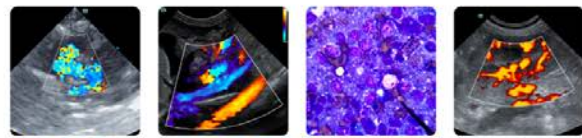
Causes of TED from an arterial standpoint include the following: CHF subsequent to endocardial damage and blood stasis (frequent in cats, occasional in dogs); protein-losing diseases (i.e., nephropathy, enteropathy); hypertension; neoplasia; hyperadrenocorticism; systemic inflammatory response syndrome (SIRS); and atherosclerosis due to hypothyroidism.

Pulmonary thromboembolism occurs as a complication to immune-mediated hemolytic anemia (IMHA), disseminated intravascular coagulation (DIC), renal disease, pancreatitis, neoplasia, sepsis, heartworm, hyperadrenocorticism, and hypothyroidism. The pathophysiology of TED is complex; however, it is essential to diagnose and treat it as adequately as possible.

The following is a schematic outline of the phenomenon:

- A) Vessel endothelial lesion → vWF(8) + fibrinogen → platelet activation/aggregation
- B) Fibrinogen formation depends on:
  - 1) Intrinsic pathway (aPTT): factors IX, XI, and XII
  - 2) Extrinsic pathway (PT): factor VII
  - 3) Common pathway (TT): factors I, II, and X with the following end result: thrombin → fibrinogen → insoluble fibrin
- C) Anticoagulation team (SAC-3T): S protein, antithrombin III (responsible for 80% of activity), C protein, TFPI-1, thrombomodulin, t-PA (from endothelium) → plasminogen → plasmin → fibrinolysis
- D) Clot/thrombus breakdown markers: fibrinogen → FDPs, D-Dimers
- E) Virchow's triad (i.e., the prothrombotic state):
  - 1) Altered endothelial structure/function: endothelin → activation of coagulation cascade; activation of platelet aggregation by ADP, fibrinogen, thromboxane A<sub>2</sub>
  - 2) Blood stasis
  - 3) Hypercoagulable state: ↓ ATIII (i.e., PLN, PLE, liver dysfunction), ↓ t-PA, ↓ urokinase, ↓ plasminogen, ↓ protein C, ↓ S, ↑ PAI-1, ↑ platelet aggregation
- F) Thrombus → ischemia/inflammation; the effect is size dependent. Clots are firmly attached to vessel walls, whereas postmortem clots are not attached.  
Thrombus progression:
  - 1) Fibrinolysis and dissolution
  - 2) Organization and recanalization
  - 3) Clot propagation
  - 4) Dislodgement and embolization

The core marker of a hypercoagulable state is a loss or lack of ATIII production. In cases of glomerular disease and protein-losing nephropathy (PLN), ATIII moves into the urine due to its small size (65,000 Daltons). This also occurs in protein-losing enteropathy (PLE); however, in cases of PLN, other coagulation factors are additionally lost, as are larger proteins (the latter are not typically lost in the case of PLE lesions). Moreover, diseases that cause PLN also lead to



**PATIENT**

Guinness Carlee

**SPECIES**

Canine

**BREED**

German Shepherd x

**SEX**

Spayed Female

**AGE**

14 Years 7 Months

**WEIGHT**

37 lbs

**INTERPRETED BY**

Eric Lindquist, DMV,  
DABVP (CFM), Cert.  
IVUSS

**IMAGING  
PERFORMED BY**

Vincent Ravancho, CVT

**HOSPITAL NAME**

Animal Paradise  
Hospital

**REFERRING VET**

Dr. Jacob

**INVOICE**

74125

**DATE**

4/1/26

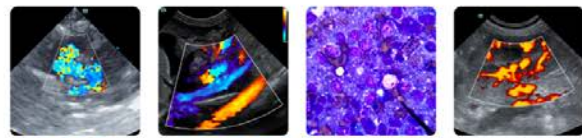
increases in fibrinogen and thromboxane levels (i.e., why aspirin is recommended in PLN), further predisposing the patient to TED. Determining the ATIII levels is essential when evaluating a hypercoagulable state. When ATIII levels are 50-75% decreased, there is a moderate TED risk; when they are 75% decreased, the risk is severe.

**Clinical Signs:** Loss of limb function is common. Cats most often display hind limb paresis or paralysis, which indicates a thrombus located at the aortic trifurcation. The classic clinical sign is the absence of a pulse; however, there can be other reasons why one may not detect a pulse: it can be difficult to palpate in an overweight cat; the patient may be hypotensive, which can result in poor peripheral pulses; or the cat may have a partially obstructed artery, which can result in the loss of a pulse. The presence of a heart murmur potentially supports a diagnosis, but the lack of one does not rule out either ATE or CHF. Other presentations may include: tachypnea; hypothermia; loss of function in a forelimb; neurologic signs attributable to the occlusion of a local artery; and abdominal pain and/or vomiting due to a mesenteric arterial thrombus and intestinal necrosis. Firm, stiff muscles may be seen acutely. Acute renal failure can also occur with renal artery thrombosis.

When portal vein thrombosis occurs, prehepatic portal hypertension develops, causing transudate fluid accumulation in the abdomen, which results in abdominal swelling and a palpable fluid wave on clinical examination. Portal vein thrombosis occasionally occurs when patients are experiencing hypercoagulable states, such as autoimmune hemolytic anemia and immune-mediated thrombocytopenia, as well as paraneoplastic events. Organ infarcts develop when local thromboembolic episodes occur in organs like the kidneys and spleen. The latter can be identified sonographically, as can localized thrombosis in vessels such as the portal vein, splenic vein, aorta, vena cava, or phrenic veins. Invasive adrenal tumors often have attached thrombi that can resemble the mass sonographically, but may dissolve partially with therapy due to improved local vascular flow. High-resolution sonography with color flow and power Doppler can identify a vascular thrombosis that may have been missed on routine sonograms.

**Diagnostics:** The increased collection of data from thromboelastography (TEG) in human studies may provide further insight into feline cases and allow for earlier detection of hypercoagulable states; however, TEG is not widely available as of yet. Currently, clinical signs and traditional coagulation panel alterations are used to arrive at the presumptive diagnosis. If serum muscle enzymes, such as AST and creatine kinase, are within normal limits, ATE is not likely to be the cause of clinical signs. Common biochemical abnormalities include hyperglycemia, azotemia, and acid-base disturbances.

It is important to note that in the overwhelming majority of cases, cardiac disease or neoplasia is an underlying disorder. Commonly associated neoplasias include, but are not limited to: pulmonary carcinoma, hepatocellular carcinoma, vaccine-associated fibrosarcoma, and squamous cell carcinoma. (Very few patients do not exhibit underlying abnormalities that fall into these categories.) Therefore, routine diagnostics should include radiographs, serum chemistry, urinalysis, CBC, total T4, ECG, and echocardiogram. Concurrent underlying pathologies affect long-term survival rates, so the early identification of such disorders



**PATIENT**

can help provide a more accurate prognosis.

Guinness Carlee

**SPECIES**

Canine

**BREED**

German Shepherd x

**SEX**

Spayed Female

**AGE**

14 Years 7 Months

**WEIGHT**

37 lbs

**INTERPRETED BY**

Eric Lindquist, DMV,  
 DABVP (CFM), Cert.  
 IUUSS

**IMAGING PERFORMED BY**

Vincent Ravancho, CVT

**HOSPITAL NAME**

Animal Paradise  
 Hospital

**REFERRING VET**

Dr. Jacob

**INVOICE**

74125

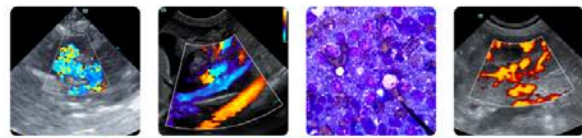
**DATE**

4/1/26

**Treatment:** The goals of acute ATE management are to: 1) manage pain appropriately; 2) treat CHF, if present; 3) minimize ongoing clot formation; 4) improve blood flow; and 5) provide optimal supportive care. Nearly all ATE patients will demonstrate dyspnea and tachypnea, but only 50% of patients will present with CHF. Therefore, the respiratory rate or pattern is not a reliable indicator of CHF and should not be the only factor one considers when determining a diagnosis. One should not administer diuretics without confirming CHF. At minimum, radiographs should be obtained prior to the use of diuretics. Analgesia is of primary therapeutic importance, as the negative effects of inadequate analgesia on recovery are well documented. Initial stabilization and supportive care for at least 48-72 hours is key before electing euthanasia.

Treatment for feline ATE:

- Analgesia: Buprenorphine (0.01-0.03 mg/kg given orally or IV BID) may be effective, but is often inadequate. Other opiates, such as methadone (0.6 mg/kg slow IV Q4-6hr) or CRI fentanyl (3-5 mcg/kg slow IV, followed by 2-5 mcg/kg/hr as a CRI), are likely to be more effective.
- If there is radiographic or other evidence of CHF, then furosemide may be administered at 1-2 mg/kg IV.
- Unfractionated heparin (UH) (250-300 IU/kg given IV initially, followed by 150-250 IU/kg SQ every 8 hours) should be administered as an anticoagulant therapy to reduce the formation of additional clots. Low molecular weight (LMW) heparin offers no advantage over UH in short-term management; however, there is no conclusive evidence-based medicine that indicates whether UH or LMW heparin has any therapeutic value in cats. LMW heparins, such as enoxaparin and dalteparin, are expensive, and dosing ranges have not been established. Warfarin should not be used in cats.
- Aspirin (5mg/kg orally every 48-72 hours) should be given once the patient has resumed eating. Discontinue heparin after the patient is stable and receiving aspirin by decreasing the dose gradually over several days.
- Clopidogrel (Plavix), an antiplatelet drug, can be administered (18.75 mg/cat) in conjunction with aspirin and should be initiated as soon as possible; however, it should not be given concurrently with UH. A recent study showed a significant improvement in cats receiving clopidogrel. These cats survived 8 months longer than those receiving aspirin.
- One should administer IV fluids for those patients not experiencing CHF. Ongoing nursing care should include attending to patient comfort and warmth, as well as monitoring for signs of improvement, such as pulse quality, limb temperature, and motor function. Patients should also be monitored for signs of reperfusion injury, such as depression, cardiac arrhythmias, conduction disturbances, hyperkalemia, and acid-base disturbances.
- Treatment of hypothermia should not be a priority until shock and systemic perfusion are adequately addressed.



**PATIENT**

Guinness Carlee

**SPECIES**

Canine

**BREED**

German Shepherd x

**SEX**

Spayed Female

**AGE**

14 Years 7 Months

**WEIGHT**

37 lbs

**INTERPRETED BY**

Eric Lindquist, DMV,  
DABVP (CFM), Cert.  
IVUSS

**IMAGING PERFORMED BY**

Vincent Ravancho, CVT

**HOSPITAL NAME**

Animal Paradise  
Hospital

**REFERRING VET**

Dr. Jacob

**INVOICE**

74125

**DATE**

4/1/26

- Follow-up diagnostics should include the following: echocardiogram; ECG; serum chemistries that include electrolytes, acid-base status, and thyroid levels; and urinalysis. Additional testing for neoplasia, such as three-view thoracic radiographs and abdominal ultrasound, should be conducted if primary cardiac disease is not confirmed.

Treatment for canine TED:

Anticoagulant therapy (heparin 100-300 IU/kg IV or SQ every 8 hours; dalteparin 100-150 IU/kg SQ BID-TID; or enoxaparin 1 mg/kg SQ BID) can be used to prevent further thrombus formation. Antiplatelet therapy should include aspirin (0.5 mg/kg PO Q12-24hr) or clopidogrel (1-2 mg/kg PO Q24h). In early cases, thrombolytic therapy, such as streptokinase or a tissue plasminogen activator, can be used; however, there is limited experience with this type of therapy in veterinary medicine and dosing regimens vary considerably. Surgical embolectomy is feasible, but often associated with significant mortality.

References:

Hogan DF. Feline cardiogenic embolism: what do we know and where are we going? Proceedings from the American College of Veterinary Internal Medicine Forum, Louisville, KY, May 31-June 3, 2006.

Hogan D, Fox P, Jacob K, Keene B, Laste N, Rosenthal S. Analysis of the feline arterial thromboembolism: clopidogrel vs aspirin trial (fat cat). Proceedings from the American College of Veterinary Internal Medicine Forum, Seattle, WA, June 12-15, 2013.

Luis Fuentes V. Arterial thromboembolism: risks, realities and a rational first-line approach. *J Feline Med Surg* 2012;14(7):459-70.

Respass M, O'Toole TE, Taeymans O, Rogers CL, Johnston A, Webster CR. Portal vein thrombosis in 33 dogs: 1998-2011. *J Vet Intern Med* 2012;26:230-37.

Smith SA, Tobias AH. Feline arterial thromboembolism: an update. *Vet Clin North Am Small Anim Pract* 2004;34(5):1245-71.

Smith SA, Tobias AH, Jacob KA, Fine DM, Grumbles PL. Arterial thromboembolism in cats: acute crisis in 127 cases (1992-2001) and long-term management with low-dose aspirin in 24 cases. *J Vet Intern Med* 2003;17(1):73-83.