



## PATIENT

Blackjack Conrad

## SPECIES

Feline

## BREED

DSH

## SEX

Neutered Male

## AGE

10 Years

## WEIGHT

17.02 pounds

## INTERPRETED BY

Eric Lindquist, DMV,  
DABVP(CFM), Cert.  
IVUSS

## IMAGING PERFORMED BY

Dr. Renee Ziegler-Post

## HOSPITAL NAME

For Cats Only  
Veterinary Clinic

## REFERRING VET

Dr. Renee Ziegler-Post

## INVOICE

14777

## DATE

04/01/26

## PRESENTING CLINICAL SIGNS

Small cell lymphoma. Currently taking Chlorambucil and Prednisolone. Prednisolone recently tapered from 10mg to 5mg.

Abnormal PE/Chem/CBC/UA Results: proBNP 891 March 30th 2026

## ULTRASONOGRAPHIC EXAMINATION OF THE HEART

FELINE CARDIAC PARAMETERS	BODY WEIGHT (lbs)	HR (BPM)	IVSd (cm)	LVIDd (cm)	LVWd (cm)	FS (%)	EF (%)
NORMAL PARAMETER	-----	150-240	0.3-0.6	1.0-2.1	0.25-0.6	35-67	80-100
PATIENT	17.02	190	0.68	1.49	0.8	45	80
FELINE CARDIAC PARAMETERS	LA/AO (M-mode)	LA/AO HEART BASE (Sisson)	LAD LA MAX 4 Chamber		LVOT VEL. (m/s)	RVOT VEL. (m/s)	IVRT (m/)
NORMAL PARAMETER	<1.5	1.6	0.7-1.7		<1.6	<1.3	40-60
PATIENT	1.5	1.4	1.4		--	--	NM
Adapted from June Boon, Veterinary Echocardiography, 1998 Sisson D et al. JVIM 1991; 5: 232, Jacobs et al. Am J Vet Res 1985; 46:1705							

## Cardiac Presentation

The echocardiogram in this patient demonstrated normal **left atrial** size based on 3 separate LA measurements. The cranial and caudal **mitral** valve leaflets presented normal linear structure and kinetics. Minor **left ventricle** hypertrophy was noted in this patient. The **myocardium** presented normal echogenicity without subjective evidence of significant fibrotic or ischemic disease. **Contractility** of the ventricular walls was adequate and in normal range for this patient evidenced by the fractional shortening measurement and subjective evaluation of the different regions and angles of the myocardium. The **left ventricular outflow** tract demonstrated normal laminar flow and subjective structural integrity. The **right atrium** and auricle revealed normal size, structure and content. No evidence of masses was noted or chamber overload. **Tricuspid** valvular assessment demonstrated adequate linear morphology and kinetics. The **right ventricle** was of normal size (1/3 diameter of LV), chordae structure, myocardial echogenicity and thickness. **Pulmonic** tract assessment revealed normal valve structure, laminar flow, and diameter (approx. 1:1 pa/ao ratio). No visible **pericardial** or free pleura fluid was noted or extra cardiac pathology in the visible planes. The cranial **mediastinum and pericardial regions** were free of masses in the visible window.

## ULTRASONOGRAPHIC FINDINGS

- Normal cardiac structure/function.



**PATIENT**

Blackjack Conrad

**SPECIES**

Feline

**BREED**

DSH

**SEX**

Neutered Male

**AGE**

10 Years

**WEIGHT**

17.02 pounds

**INTERPRETED BY**

Eric Lindquist, DMV,  
DABVP(CFM), Cert.  
IVUSS

**IMAGING PERFORMED BY**

Dr. Renee Ziegler-Post

**HOSPITAL NAME**

For Cats Only  
Veterinary Clinic

**REFERRING VET**

Dr. Renee Ziegler-Post

**INVOICE**

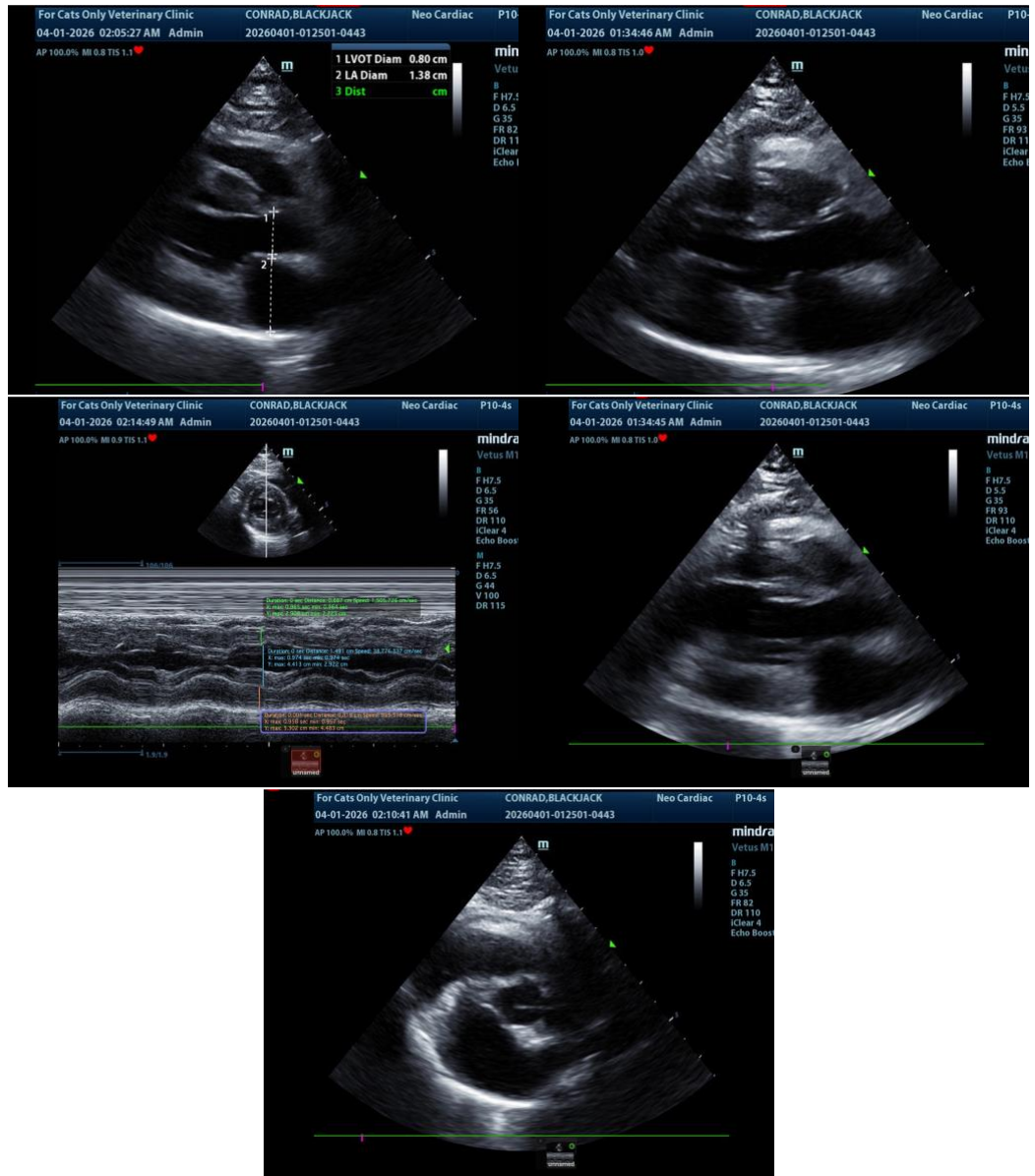
14777

**DATE**

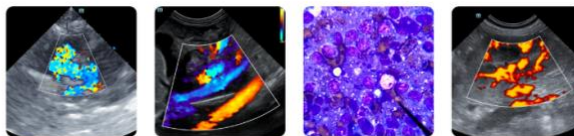
04/01/26

**INTERPRETATION OF THE FINDINGS & FURTHER RECOMMENDATIONS**

Hypertension and hyperthyroidism should be ruled out as the left ventricle hypertrophy may be consistent with minor clinically insignificant form of hypertrophic cardiomyopathy or temporary myocardial thickening/TMT. No evidence of volume overload. I do recommend ensuring that minimal effective Prednisolone dose is utilized to avoid potential Cortisone induced heart failure, though there is no evidence of such at this time. No cardiac medications are recommended. No structural evidence of myocardial lymphoma was present.



The information and recommendations provided are based on the images presented by the referring veterinarian/sonographer. No evaluation can be communicated regarding pathology that was not



## PATIENT

Blackjack Conrad

## SPECIES

Feline

## BREED

DSH

## SEX

Neutered Male

## AGE

10 Years

## WEIGHT

17.02 pounds

## INTERPRETED BY

Eric Lindquist, DMV,  
DABVP(CFM), Cert.  
IVUSS

## IMAGING PERFORMED BY

Dr. Renee Ziegler-Post

## HOSPITAL NAME

For Cats Only  
Veterinary Clinic

## REFERRING VET

Dr. Renee Ziegler-Post

## INVOICE

14777

## DATE

04/01/26

visible in the image/video clips provided.

Thank you for this referral. If the clinical or image interpretation does not parallel your findings or if I can be of any further assistance, please contact me.

Eric Lindquist, DMV, DABVP(CFM), Cert. IVUSS,

CEO, Owner, Founder -- SonoPath.com

[info@SonoPath.com](mailto:info@SonoPath.com)