



PATIENT PRESENTING CLINICAL SIGNS

Jack Flores Heart murmur grade 4/6. R/O cardiac disease. Echo today to assess anesthetic risk.

SPECIES ULTRASONOGRAPHIC EXAMINATION OF THE HEART

Canine

BREED

Chihuahua

SEX

Neutered Male

AGE

13 Years

WEIGHT

13 Pounds

CANINE CARDIAC PARAMETERS	MR VMAX (m/s)	TR VMAX (m/s)	LA/AO (Boon method)	LA/AO (Heart Base; Swe)	FS (%)	EF (%)	EPSS (cm)
NORMAL PARAMETER	4.5-5.5	<2.7	1.3	<1.6	28-40	40-100	<0.6
PATIENT	6.0		1.5	1.8	37	68	0.18
CANINE CARDIAC PARAMETERS	HR (BPM)	AV VMAX (m/s)	PV MAX (m/s)	BODY WEIGHT (kg)	LA 2D short axis Base view (cm)	LVIDd Avg; 2D and m-mode short axis (cm)	LVIDs Avg; 2D and m-mode short axis (cm)
NORMAL PARAMETER	50-100	0.7-1.7	0.7-1.6	BELOW	BELOW	BELOW	BELOW
PATIENT		1.21	0.71		3.5	2.89	

Cardiac Presentation

The echocardiogram for this patient presented excessive **left atrial size** expressed both in the LA/AO and LA max measurements. Complete filling of the left atrium noted on color flow assessment. The cranial and caudal **mitral** valve leaflets presented vegetative thickening consistent with endocardiosis. Doppler indicated measurable insufficiency. Prolapse of the anterior mitral valve leaflet noted. The **left ventricle** presented thicknesses with linear contour and was not dilated nor restricted. The **myocardium** presented normal echogenicity without subjective evidence of significant fibrotic or ischemic disease. **Contractility** of the ventricular walls was adequate and in normal range for this patient evidenced by the fractional shortening measurement and subjective evaluation of the different regions of the myocardium. The **left ventricular outflow** tract demonstrated normal laminar flow and subjective structural integrity. The **right atrium** and auricle revealed normal size, structure and content. No evidence of masses was noted or chamber overload. **Tricuspid** valvular assessment demonstrated adequate linear morphology. The **right ventricle** was of normal size (1/3 diameter of LV), chordae structure, myocardial echogenicity and thickness. **Pulmonic** tract assessment revealed normal valve structure, laminar flow, and diameter (approx. 1:1 pa/ao ratio). No visible **pericardial** or free pleura fluid was noted. No echographically detectable evidence of infiltrative disease was visible. The cranial **mediastinum and pericardial regions** were free of masses in the visible window.

ULTRASONOGRAPHIC FINDINGS

- Mid Stage B2 valvular disease

INTERPRETATION OF THE FINDINGS & FURTHER RECOMMENDATIONS

There is some anesthetic risk in this patient. Recommend initiating Pimobendan at 0.3 mg/kg BID. If systolic blood pressure is >160, then ACE inhibitor would be indicated. Ideally, recheck echo after 10-14 days of therapy. If tachypnea is present (i.e., basal respiratory rate >20/min), then low dose Lasix can also be considered.

INTERPRETED BY

Eric Lindquist, DMV

DABVP, Cert. IVUSS

IMAGING PERFORMED BY

Kelly Vazquez

HOSPITAL NAME

Animal Paradise Hospital

REFERRING VET

Dr. ElShafie

INVOICE

36302

DATE

3/18/22



PATIENT

Jack Flores

The heart has some volume overload and is working to compensate for the valvular insufficiency. Target respiratory rate is < 20 resp/minute after therapy. After initiating therapy, I recommend recheck on the clinical exam, BUN, Creatinine, USG, Chest radiographs & Blood pressure in 5-7 days. Recheck echo in 1 month. Earlier if clinical decompensation is occurring. I do not recommend anesthesia at this time until stabilization has occurred on the recommended medications. Repeat preanesthetic echo is ideal if anesthesia is eventually necessary.

SPECIES

Canine

BREED

Chihuahua

SEX

Neutered Male

AGE

13 Years

WEIGHT

13 Pounds

INTERPRETED BY

Eric Lindquist, DMV

DABVP, Cert. IVUSS

IMAGING PERFORMED BY

Kelly Vazquez

HOSPITAL NAME

Animal Paradise Hospital

REFERRING VET

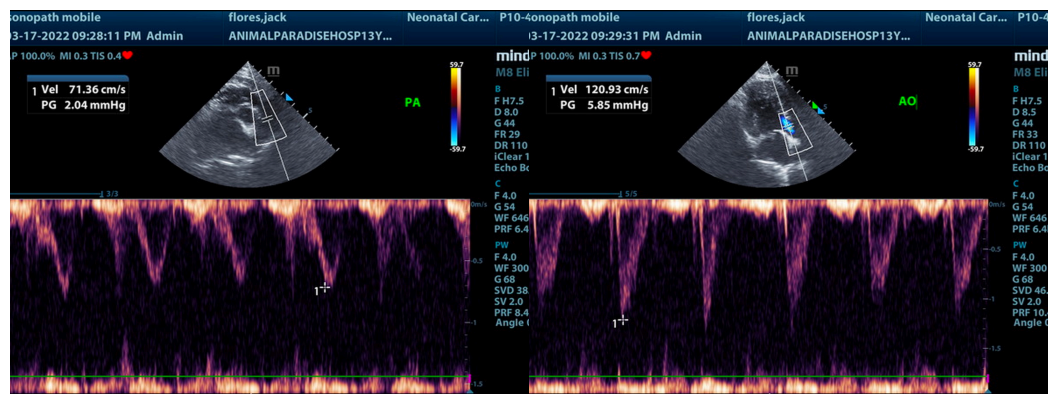
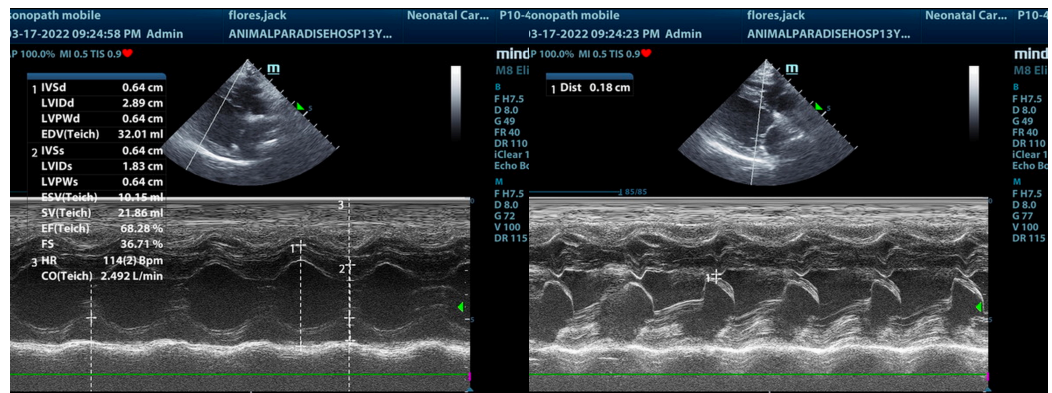
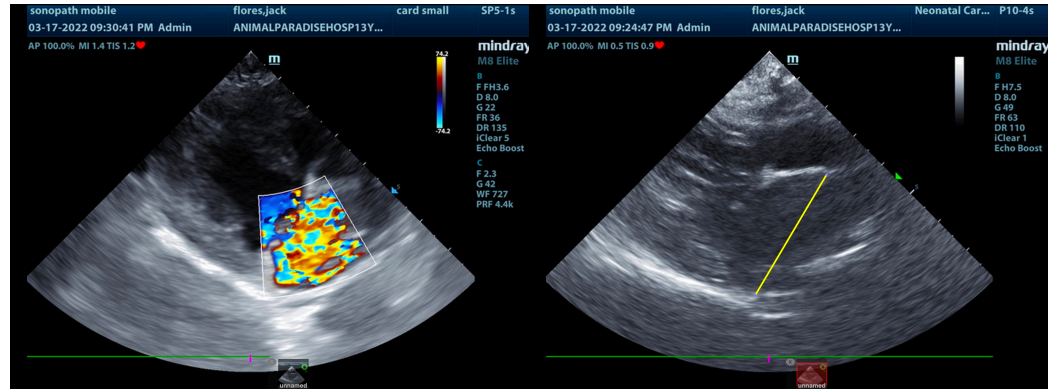
Dr. ElShafie

INVOICE

36302

DATE

3/18/22





PATIENT

Jack Flores

SPECIES

Canine

BREED

Chihuahua

SEX

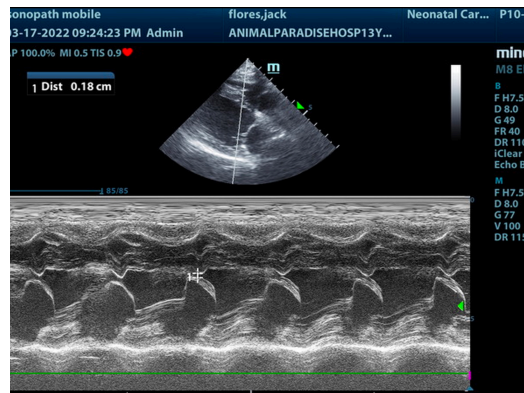
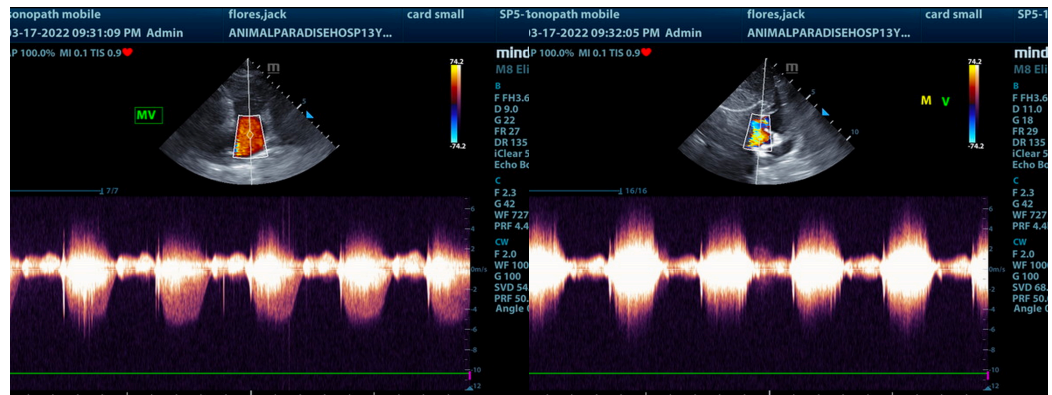
Neutered Male

AGE

13 Years

WEIGHT

13 Pounds



INTERPRETED BY

Eric Lindquist, DMV

DABVP, Cert. IVUSS

IMAGING PERFORMED BY

Kelly Vazquez

HOSPITAL NAME

Animal Paradise
Hospital

REFERRING VET

Dr. ElShafie

INVOICE

36302

DATE

3/18/22

The information and recommendations provided are based on the images presented by the referring veterinarian/sonographer. No evaluation can be communicated regarding pathology that was not visible in the image/video clips provided.

Thank you for this referral. If the clinical or image interpretation does not parallel your findings or if I can be of any further assistance please contact me.

Eric Lindquist, DMV, DABVP, Cert. IVUSS, CEO of SonoPath.com

info@SonoPath.com