



PATIENT

Toto Gannon

SPECIES

Canine

BREED

Maltese Mix

SEX

Spayed Female

AGE

10

WEIGHT

27

INTERPRETED BY

Eric Lindquist, DMV,
DABVP(CFM), Cert.
IVUSS

IMAGING PERFORMED BY

Jenn

HOSPITAL NAME

Rockaway Animal
Hospital

REFERRING VET

Dr. Maniar

INVOICE

14151

DATE

03/09/26

PRESENTING CLINICAL SIGNS

- not herself, tried to bite, lethargy

ULTRASONOGRAPHIC EXAMINATION OF THE ABDOMEN

Urinary System

The **urinary bladder**, trigone, and pelvic urethra to a depth of 2.0 cm presented normal thicknesses and normal tone. The ureters were not visible which is normal. No uroliths or sediment were visualized, and anechoic urine was present. No evidence of inflammatory or neoplastic changes were noted. Ureteral papillae were normal.

The **kidneys** revealed normal size and structure, corticomedullary definition and ratio for this age. The cortices presented largely uniform texture with normal echogenic relationship to liver and spleen. Medullary structure differed distinctly from the cortex and no evidence of pelvic dilation was present. The capsules were acceptably uniform without significant irregularities. The left kidney measured 4.18 cm in length. The right kidney measured 4.2 cm in length.

Adrenal Glands

Both **adrenal glands** were visualized and recognized as having normal shape, size, position and echogenicity for this breed. The phrenic vasculature, glandular echogenicity and detail were unremarkable. Capsule, cortex, and medullary definition were normal for this age patient. The left adrenal gland measured 4.2 cm width. The right adrenal gland measured 0.60 cm width.

Spleen

The **spleen** presented a smooth homogeneous parenchyma hyperechoic to liver and renal cortical parenchyma. The capsule was smooth without noticeable expansion or deviation from within the spleen or adjacent pathology. The splenic vasculature demonstrated normal volume without signs of congestion or thrombosis. No sonographic evidence of acute or chronic inflammatory, neoplastic, or infarctual changes were noted.

Liver

The **liver** images from right and left intercostal as well as subcostal views revealed generalized hepatic enlargement. Some minor age-related parenchymal remodeling was noted but likely not clinically significant at this time. Vascular and biliary tracts were of normal volume and no evidence of congestion was noted. The gallbladder was slightly edematous and presented some dependent debris with essentially normal contour. The cystic and common bile ducts were normal. No overt evidence of active inflammatory, infiltrative or regenerative pathology was noted but should be paired with current or past LE elevations regarding any clinical significance to this presentation. The hepatic lymph nodes were unremarkable.

Gastrointestinal

The **stomach** was slightly thickened with residual ingesta, potential bone material. The small intestine and colon were unremarkable.

Pancreas



PATIENT

Toto Gannon

SPECIES

Canine

BREED

Maltese Mix

SEX

Spayed Female

AGE

10

WEIGHT

27

INTERPRETED BY

Eric Lindquist, DMV,
DABVP(CFM), Cert.
IVUSS

IMAGING PERFORMED BY

Jenn

HOSPITAL NAME

Rockaway Animal
Hospital

REFERRING VET

Dr. Maniar

INVOICE

14151

DATE

03/09/26

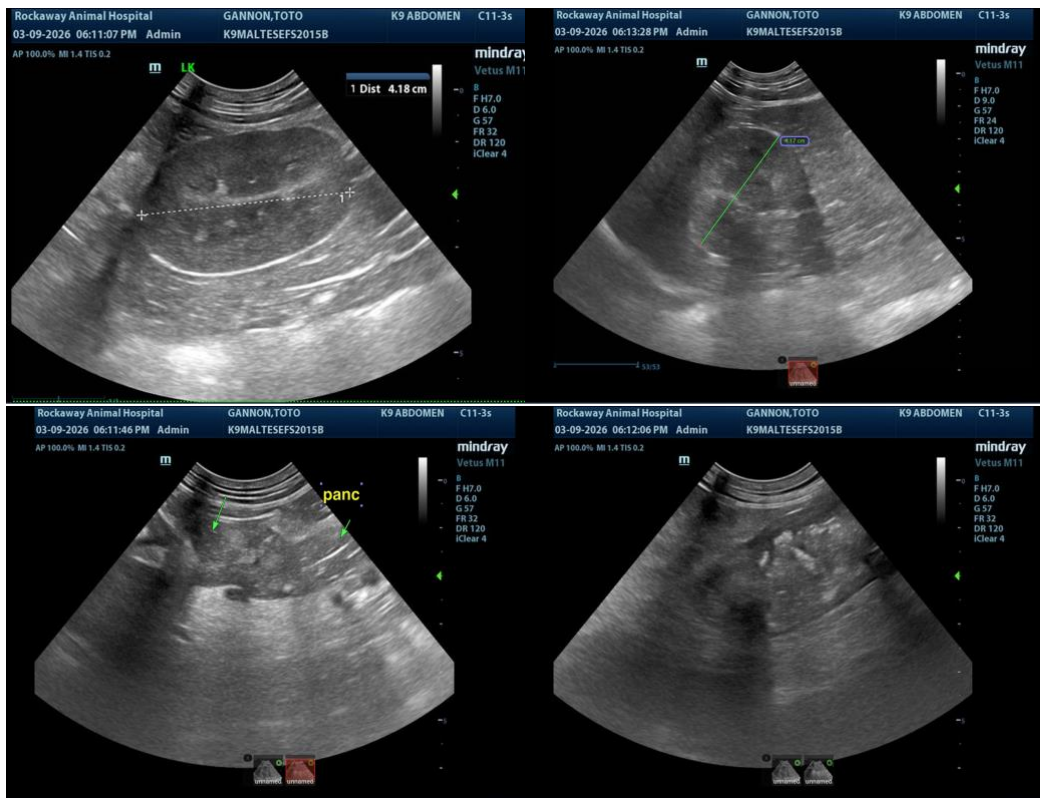
The **pancreas** in this patient was enlarged and irregular. Hypoechoic surrounding fat with hyperechoic surrounding mesentery.

ULTRASONOGRAPHIC FINDINGS

- Extensive pancreatitis.
- Minor gastric stasis with bone type material.

INTERPRETATION OF THE FINDINGS & FURTHER RECOMMENDATIONS

IV fluid support, pain management and broad-spectrum antibiotics are warranted over the next 48-72 hours. The clinical signs can be justified by the pancreatitis. Pancreatic pathology appeared to be localized to the left limb and left base. Left subxiphoid palpation is warranted to assess for discomfort. Recheck sonogram after 3-5 days of therapy. No evidence or suspicion of neoplasia.





PATIENT

Toto Gannon

SPECIES

Canine

BREED

Maltese Mix

SEX

Spayed Female

AGE

10

WEIGHT

27

INTERPRETED BY

Eric Lindquist, DMV,
DABVP(CFM), Cert.
IVUSS

IMAGING PERFORMED BY

Jenn

HOSPITAL NAME

Rockaway Animal
Hospital

REFERRING VET

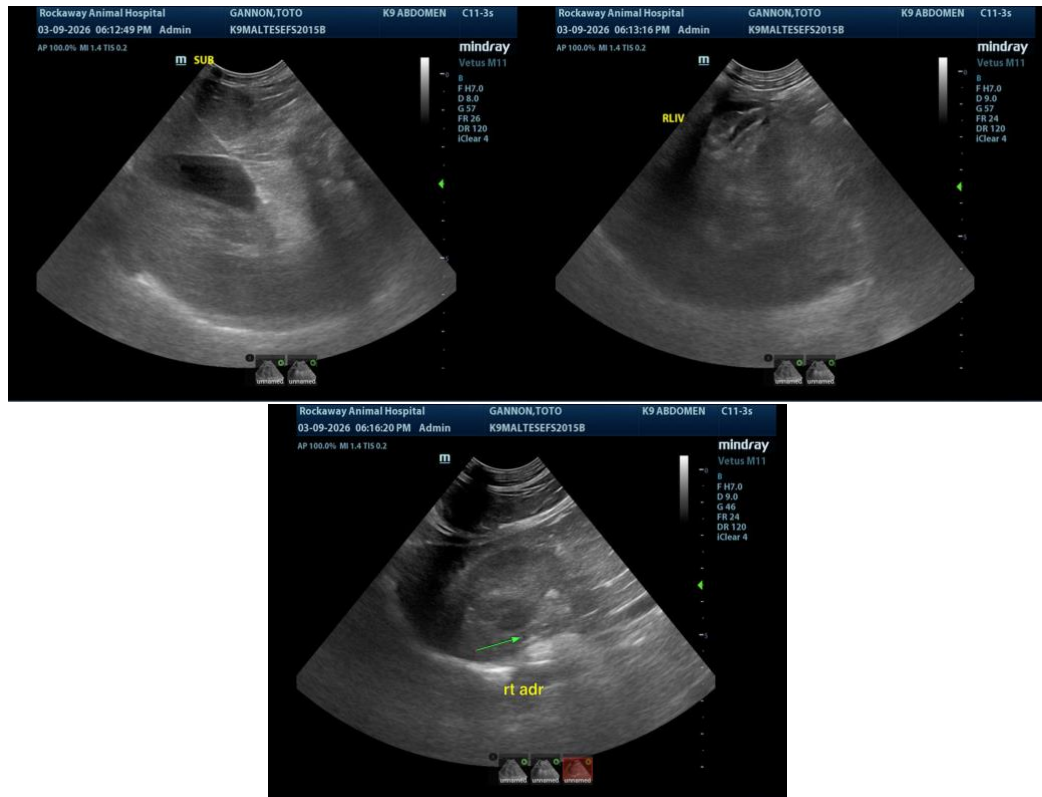
Dr. Maniar

INVOICE

14151

DATE

03/09/26



The information and recommendations provided are based on the images presented by the referring veterinarian/sonographer. No evaluation can be communicated regarding pathology that was not visible in the image/video clips provided.

Thank you for this referral. If the clinical or image interpretation does not parallel your findings or if I can be of any further assistance, please contact me.

Eric Lindquist, DMV, DABVP(CFM), Cert. IVUSS,

CEO, Owner, Founder -- SonoPath.com

info@SonoPath.com