



PATIENT

Sinclair PHVA

SPECIES

Feline

BREED

DSH

SEX

Neutered Male

AGE

12 Years

WEIGHT

6.5 pounds

INTERPRETED BY

Eric Lindquist, DMV,
DABVP(CFM), Cert.
IVUS

IMAGING PERFORMED BY

Dr. Ryan Leal

HOSPITAL NAME

Wellesley Animal
Hospital

REFERRING VET

Dr. Cecelia Dean

INVOICE

14160

DATE

03/09/26

PRESENTING CLINICAL SIGNS

- Pre-anesthetic echo for possible COHAT. Pt is rescue, found in feral colony, has significant URI signs, and a 3/6 parasternal murmur. Recheck labwork submitted today
- Problem List: Heart murmur, dental disease, anemia (significant), URI, Conjunctivitis, CKD

PE: BCS 3/9, unkempt coat, significant nasal discharge with 1+ RE, OD blepharospasm, 3/6 parasternal murmur, significant dental disease, 5% dehydrated, diffuse moderate sarcopenia, Labork 1/20/26 CBC: HCT 13%, Neutrophilia 18k Chem: Creat 2.7, BUN 130, Phos 13.9, Alb 2.5 UA: USG: 1.014, quiet sediment T4 1.4 FeLV/FIV negative

PRE-ANESTHETIC ECHOCARDIOGRAM

8 efficiency video clips from SDEP protocol provided.

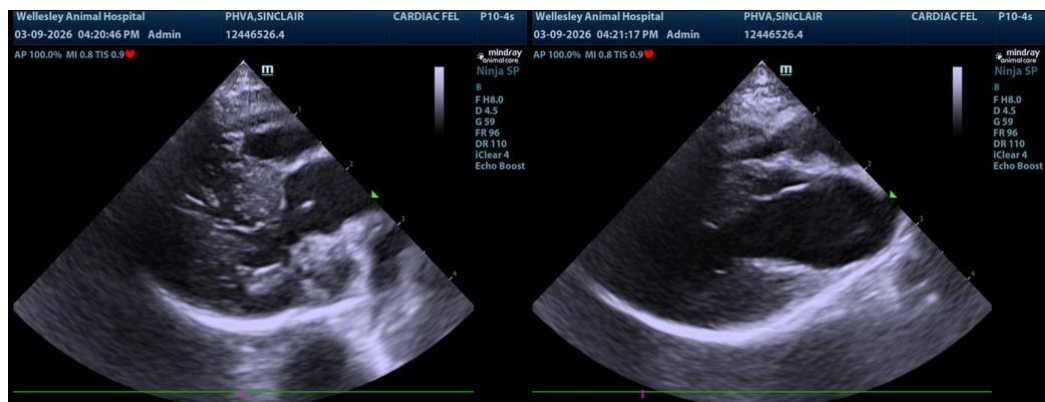
All four chambers revealed normal volumes and contractility. No pericardial or pleural effusion noted. No gross abnormalities that would preclude anesthesia.

INTERPRETATION OF THE FINDINGS & FURTHER RECOMMENDATIONS

Category 1: Anesthetic risk is considered normal to mild. No gross abnormalities noted on SDEP. Screening Echo to contraindicate anesthesia. Minimal to no left atrial enlargement noted on images presented.

a. However, judicious fluid administration is advised with careful RR/RE monitoring to screen for fluid overload.

b. Monitoring of blood pressure, SpO₂, CO₂, and auscultation of heart and lungs during anesthesia should be done during every procedure.





PATIENT

Sinclair PHVA

SPECIES

Feline

BREED

DSH

SEX

Neutered Male

AGE

12 Years

WEIGHT

6.5 pounds

INTERPRETED BY

Eric Lindquist, DMV,
DABVP(CFM), Cert.
IVUSS

IMAGING PERFORMED BY

Dr. Ryan Leal

HOSPITAL NAME

Wellesley Animal
Hospital

REFERRING VET

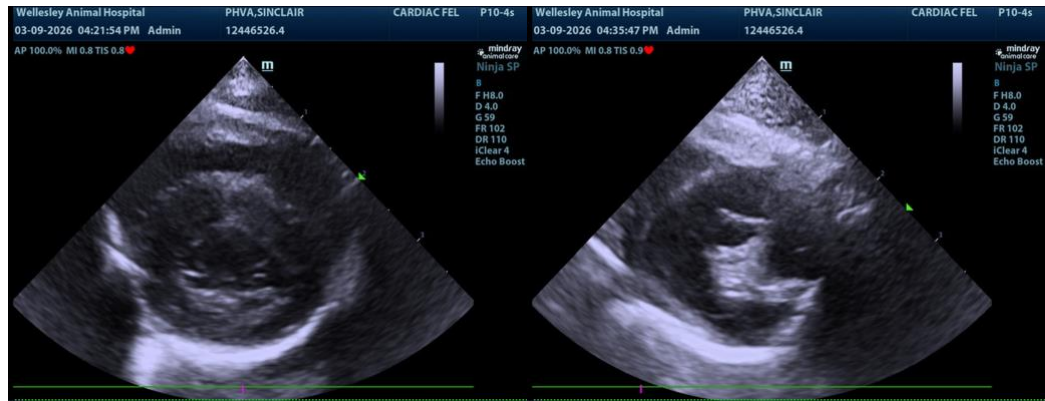
Dr. Cecelia Dean

INVOICE

14160

DATE

03/09/26



The information and recommendations provided are based on the images presented by the referring veterinarian/sonographer. No evaluation can be communicated regarding pathology that was not visible in the image/video clips provided.

Thank you for this referral. If the clinical or image interpretation does not parallel your findings or if I can be of any further assistance, please contact me.

Eric Lindquist, DMV, DABVP(CFM), Cert. IVUSS,

CEO, Owner, Founder -- SonoPath.com

info@SonoPath.com