



## PATIENT

Potat Robertson

## SPECIES

Canine

## BREED

Yorkshire Terrier x

## SEX

Neutered Male

## AGE

5 Years

## WEIGHT

18.8 lbs

## INTERPRETED BY

Eric Lindquist, DMV,  
DABVP (CFM), Cert.  
IVUSS

## IMAGING PERFORMED BY

Dr. Hurley

## HOSPITAL NAME

Bayshore Veterinary  
Hospital

## REFERRING VET

Dr. Hurley

## INVOICE

73598

## DATE

3/9/26

## PRESENTING CLINICAL SIGNS

PU/PU, Weight gain, Reduced appetite

Abnormal PE/Chem/CBC/UA Results: CBC/Chem15/lytes: WNL 4DX: Negative UA: USG 1023, Few RBCs, all else normal

## ULTRASONOGRAPHIC EXAMINATION OF THE ABDOMEN

**\*\*Note the images were not labeled with patient name and therefore were unable to be interpreted until confirmed.**

### Urinary System

The **urinary bladder**, trigone, and pelvic urethra presented normal thicknesses and normal tone. The ureters were not visible which is normal. No uroliths or sediment were visualized and anechoic urine was present. No evidence of inflammatory or neoplastic changes were noted. Ureteral papillae were normal. The pelvic urethra was imaged 2.0 cm beyond the cystourethral junction.

The **kidneys** revealed normal size and structure, corticomedullary definition and ratio for this age. The cortices presented largely uniform texture with normal echogenic relationship to liver and spleen. Medullary structure differed distinctly from the cortex and no evidence of pelvic dilation was present. The capsules were acceptably uniform without significant irregularities. Left kidney measured 4.5 cm. Right kidney measured 4.2 cm.

### Adrenal Glands

Both **adrenal glands** were visualized and recognized as having normal shape, size, position and echogenicity for this breed. The phrenic vasculature, glandular echogenicity and detail were unremarkable. Capsule, cortex, and medullary definition were normal for this age patient. Left measured 0.50 cm. Right measured 0.50 cm.

### Spleen

The **spleen** presented a smooth homogeneous parenchyma hyperechoic to liver and renal cortical parenchyma. The capsule was smooth without noticeable expansion or deviation from within the spleen or adjacent pathology. The splenic vasculature demonstrated normal volume without signs of congestion or thrombosis. No sonographic evidence of acute or chronic inflammatory, neoplastic, or infarctual changes were noted.

### Liver

Exam of the cranial abdomen demonstrated excessive **liver** size, swollen contour, with conserved uniform architecture. Parenchymal echogenicity was diffusely isoechoic to the spleen and falciform fat. The gallbladder was largely unremarkable with a minor amount of dependent debris. This is expected for this type of presentation. There was no overt pathology.

### Gastrointestinal

Examination of the **gastrointestinal tract** revealed a stomach and intestine free of stasis, of normal wall thickness, acceptable curvilinear mural detail, and peristaltic activity. Small and large intestine demonstrated normal luminal chyme and stool consistency respectively. No obstructive or overt infiltrative disease was noted. No associated abnormal lymphatic activity was noted.



## PATIENT

Potat Robertson

## SPECIES

Canine

## BREED

Yorkshire Terrier x

## SEX

Neutered Male

## AGE

5 Years

## WEIGHT

18.8 lbs

## INTERPRETED BY

Eric Lindquist, DMV,  
DABVP (CFM), Cert.  
IVUSS

## IMAGING PERFORMED BY

Dr. Hurley

## HOSPITAL NAME

Bayshore Veterinary  
Hospital

## REFERRING VET

Dr. Hurley

## INVOICE

73598

## DATE

3/9/26

## Pancreas

The base and limbs of the **pancreas** were observed to be largely isoechoic to surrounding omental fat. Pancreatic duct and capsular contour were acceptably normal and parenchyma respected normal curvilinear patterns. No overt evidence of active inflammatory or neoplastic disease was noted.

## ULTRASONOGRAPHIC FINDINGS

- Mild benign vacuolar hepatopathy, no other evidence of pathology.

## INTERPRETATION OF THE FINDINGS & FURTHER RECOMMENDATIONS

I cannot rule out PDH in this patient, as approximately 10-15% of PDH patients may have measurably normal adrenals. However, if the patient is to be managed for Cushing's disease, I strongly recommend that all clinical parameters are definitively present for Cushing's, since the adrenals measure normal with normal contour.

## Efficient & Accurate Cushing's Work up-Lindquist

### Notes regarding Cushing's Clinical Presentations:

*Nearly all Cushing's dogs have SAP elevations and true PU/PD (USG < 1.025) and most are polyphagic. Cushing's dogs are > 6 years and usually > 9 years old, usually have poor skin coats, body scores > 3/5, and are usually sedentary animals.*

*Its important to remember that Cushing's dogs usually look and play the part and other diseases cause false + stress related cortisol spikes. On rare occasion a Cushing's dog will not follow the rules but this is truly an exception.*

*Potential Cushing's patient workups can be costly and frustrating if not definitive and, in my experience, the non-definitive patient usually has something else going on that may be contributing to some of the clinical signs a Cushing's dog will have, especially SAP elevations or PU/PD. Based on this prelude of information I came up with the following algorithm in the spirit of diagnostic efficiency.*

*The following suggested protocol is based on current available literature on Cushing's disease and extensive clinical-sonographic experience evaluation + Cushing's and False + LDDST & ACTH stim. cases in order to maximize the efficiency of a Cushing's workup in practice.*

### Screen first, workup second

1) **UA:** Repeatable (2-3 urine samples) Urine specific gravity & urine cortisol/creatinine ratio (UCCR): If **repeatable USG < 10.20 and + UCCR** move to next step 2.

*Note: UA is inexpensive and easy to obtain and if UA criteria is not met for Cushing's then resources can be spent into other more pertinent diagnostics or left on hold until the UA criteria is met in emerging Cushing's cases.*

2) **Sonogram:** Does the patient **have concurrent disease** clinically or sonographically as non-Cushing's illness will influence the potential false + LDDST or even ACTH stim. The sonogram gives a global perspective of the internal health of the patient to be considered in the Cushing's workup as an assessment of concurrent disease. Is there a concurrent neoplastic process, UTI pancreatitis, mucocele....? Are the adrenals enlarged (Cushing's-PDH, stress, age related or breed variant), or atrophied (Iatrogenic Cushing's or adrenal burnout), have asymmetric enlargement (Adrenal tumor, hyperplasia, adenoma, age related variant), or is there vascular invasion (Invasive pheo with false + UA criteria or adenocarcinoma or phrenic thrombosis)? The sonogram answers these questions proactively.



## PATIENT

Potat Robertson

## SPECIES

Canine

## BREED

Yorkshire Terrier x

## SEX

Neutered Male

## AGE

5 Years

## WEIGHT

18.8 lbs

## INTERPRETED BY

Eric Lindquist, DMV,  
DABVP (CFM), Cert.  
IVUSS

## IMAGING PERFORMED BY

Dr. Hurley

## HOSPITAL NAME

Bayshore Veterinary  
Hospital

## REFERRING VET

Dr. Hurley

## INVOICE

73598

## DATE

3/9/26

3) **LDDST** (0.01 D-Sodium phosphate mg/kg IV) (Better screening test but plagued with false +) Use if there is potential early Cushing's or if adrenal asymmetry present on sonogram suspecting tumor. Use LDDST in cats at a higher dose (0.1 mg/kg IV).

OR

4) **ACTH stim.** (Better confirming test but can have false +) Use if the patient "looks" Cushingoid or if bilateral adrenal enlargement is present, or high normal width on sonogram, or if iatrogenic Cushing's suspected (Cortisone Tx in past).

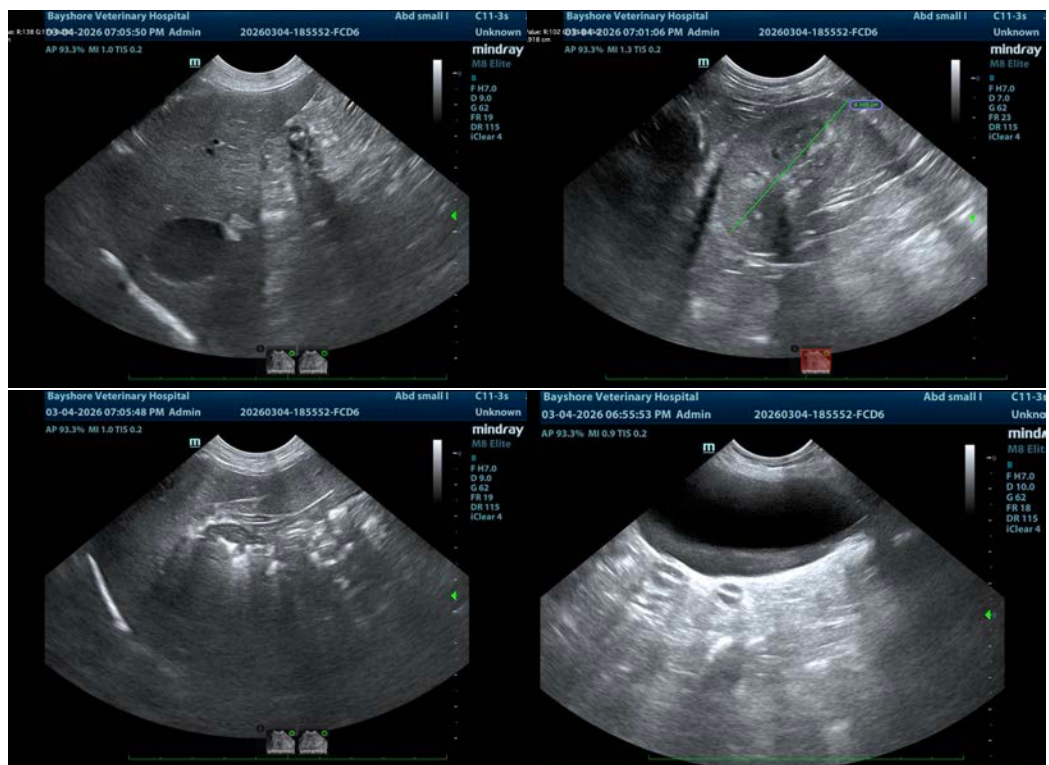
5) If **diabetic** then run both LDDST & ACTH stim.

5) Run a **serial blood pressure** in a BP friendly non "white coat effect" atmosphere. Run at least 3 at different times over a few hours or when eating as the patient tends to be calm when eating or give Torbutrol when entering the facility.

6) **Perform CT** of the pituitary to identify macro adenoma expansion if any lethargy or dullness or other central clinical CNS signs are minimally present.

Suggested reading:

Behrend EN, Kooistra HS, Nelson R, et al. Diagnosis of Spontaneous Canine Hyperadrenocorticism: 2012 ACVIM Consensus Statement (Small Animal). J Vet Intern Med 2013;27:1292-1304.





**PATIENT**

Potat Robertson

**SPECIES**

Canine

**BREED**

Yorkshire Terrier x

**SEX**

Neutered Male

**AGE**

5 Years

**WEIGHT**

18.8 lbs

**INTERPRETED BY**

Eric Lindquist, DMV,  
DABVP (CFM), Cert.  
IVUSS

**IMAGING PERFORMED BY**

Dr. Hurley

**HOSPITAL NAME**

Bayshore Veterinary  
Hospital

**REFERRING VET**

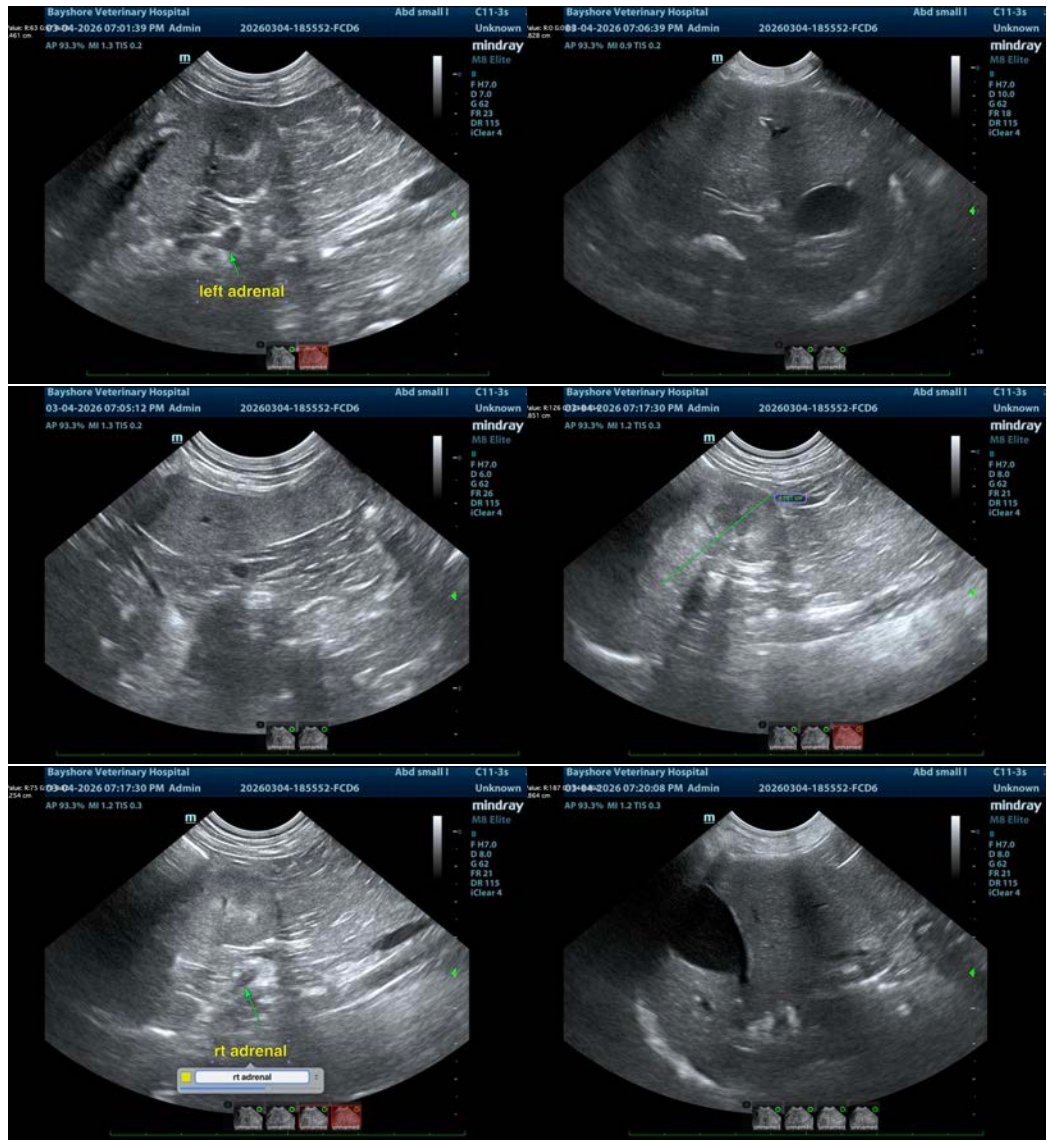
Dr. Hurley

**INVOICE**

73598

**DATE**


3/9/26



The information and recommendations provided are based on the images presented by the referring veterinarian/sonographer. No evaluation can be communicated regarding pathology that was not visible in the image/video clips provided.

Thank you for this referral. If the clinical or image interpretation does not parallel your findings or if I can be of any further assistance please contact me.

**Eric Lindquist**, DMV, DABVP(CFM), Cert. IVUSS,  
CEO, Owner, Founder -- SonoPath.com  
[info@SonoPath.com](mailto:info@SonoPath.com)



## PATIENT

Potat Robertson

## SPECIES

Canine

## BREED

Yorkshire Terrier x

## SEX

Neutered Male

## AGE

5 Years

## WEIGHT

18.8 lbs

## INTERPRETED BY

Eric Lindquist, DMV,  
DABVP (CFM), Cert.  
IVUSS

## IMAGING PERFORMED BY

Dr. Hurley

## HOSPITAL NAME

Bayshore Veterinary  
Hospital

## REFERRING VET

Dr. Hurley

## INVOICE

73598

## DATE

3/9/26

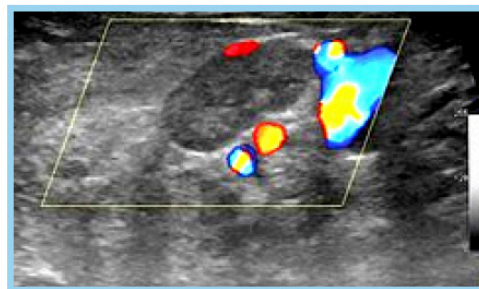
## Section 1: Clinical Syndromes Frequently Associated with the Sonogram



Scan or click  
here for  
supplementary  
resources

## Polyuria & Polydipsia (PU/PD)

PU/PD

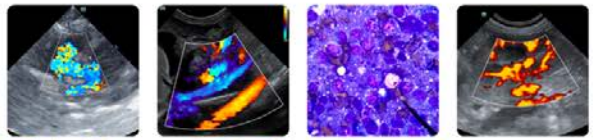


Long axis of the left adrenal gland in a cat with pituitary dependent hyperadrenocorticism and bilateral adrenal hyperplasia. There is mild increase in pericapsular echogenicity and symmetrical enlargement with cranial and caudal pole heights of more than 5 mm. Note the color Doppler signals are consistent with the phrenicoabdominal vessels and the junction of the renal vein and caudal vena cava.

**DESCRIPTION** Polyuria and polydipsia (PU/PD) often occur together and are a common complaint in small animal practice. Given the many differential diagnoses for PU/PD and the diagnostic challenge associated with ruling in or out the various disease processes, one should follow a systematic approach when confronted with PU/PD cases. Causes can be categorized in two ways: 1) using an assessment of specific gravity, i.e., solute diuresis (specific gravity 1.008–1.024) and water diuresis (specific gravity 1.001–1.007), and 2) undertaking a clinical evaluation of diseases caused by primary renal disease or extrarenal causes of PU/PD. The following is a reference list of differential diagnoses one can use to categorize PU/PD according to renal or extrarenal disease:

Renal disease	Extrarenal disease	
Acute renal failure	Hyperadrenocorticism	Hypercalcemia
Chronic renal failure	Hypoadrenocorticism	Hyponatremia
Glomerulonephritis	Diabetes mellitus	Hypokalemia
Primary glucosuria (Fanconi's)	Hyperthyroidism (cats)	Liver failure
Pyelonephritis	Acromegaly	Pheochromocytoma
Non-azotemic renal disease	Pyometra	Polycythemia
Leptospirosis	- Postobstructive diuresis - Salt supplementation - Drugs (e.g., diuretics, prednisone) - Atypical Cushing's - SARDS - Medullary washout	- Paraneoplastic - Pericardial effusion - Hypertension - Central diabetes insipidus - Nephrogenic diabetes insipidus - Psychogenic water intake

10. A final diagnosis of psychogenic PU/PD is very rare and is always a diagnosis of exclusion.



## PATIENT

Potat Robertson

## SPECIES

Canine

## BREED

Yorkshire Terrier x

## SEX

Neutered Male

## AGE

5 Years

## WEIGHT

18.8 lbs

## INTERPRETED BY

Eric Lindquist, DMV,  
DABVP (CFM), Cert.  
IVUSS

## IMAGING PERFORMED BY

Dr. Hurley

## HOSPITAL NAME

Bayshore Veterinary  
Hospital

## REFERRING VET

Dr. Hurley

## INVOICE

73598

## DATE

3/9/26

Clinical Syndromes  
Frequently Associated  
with the Sonogram

PU/PD

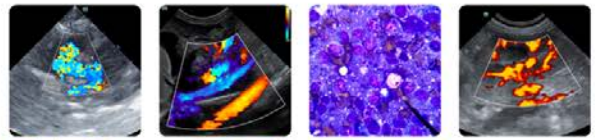
**CLINICAL SIGNS** Clinical signs include excessive thirst and urination. Whereas normal intake ranges from 60–80 mL/kg/day, excessive thirst is classified as drinking upwards of 100 mL/kg/day. Excessive urination is deemed to be a urine output greater than 50 mL/kg/day (normal output ranges from 20–40 mL/kg/day). The signs may manifest as abnormal intake behavior and even water seeking in profoundly polydipsic patients, as well as urinary accidents in the house.

**DIAGNOSTICS** The diagnostic approach to PU/PD can be daunting given the large number of differentials listed above. First, one must evaluate signalment, patient history, and the results of a physical examination to determine clues that point to potential causes of PU/PD. For example, diabetes may be suspected in a middle-to-older-aged dog experiencing weight loss and polyphagia, hyperthyroidism may be suspected in older cats experiencing weight loss and polyphagia, and pyometra may be suspected in intact female dogs and cats.

Prior to proceeding with expensive diagnostic tests, the presence of PU/PD should be confirmed by measuring water intake over a 2–3-day period at home. Urine specific gravity is also an important screening test as a concentrated urine sample rules out the presence of PU/PD.

**BASIC WORKUP** Many disease processes can be ruled out through basic blood work. The minimum database includes a CBC, biochemical profile, and urinalysis (UA). The UA is especially important for evaluating specific gravity, glucose or protein loss, and sediment that may indicate infection. A urine protein:creatinine (UPC) and/or microalbumin test should be performed to assess for protein-losing nephropathy (PLN), especially in cases where the urine sample is not concentrated, and a urine dipstick test may yield a false negative. One should take the systemic blood pressure to evaluate for hypertension. A urine culture should also be done to rule out infection and pyelonephritis, even if there is no evidence of the latter on the ultrasound. One may also consider a trial with antibiotics to see if the PU/PD resolves. It is also necessary to assess the total T4 and/or the free T4 in geriatric cats.

**ABDOMINAL ULTRASOUND** The role of abdominal ultrasound is key in the diagnosis of PU/PD as it permits practitioners to evaluate the different organs for potential disease processes. For example, the kidneys can be evaluated for size, as they may be small in the face of chronic renal failure or normal-to-enlarged in cases of acute renal failure. The renal parenchymal echogenicity may be normal or increased in cases of renal disease, and a loss of corticomedullary distinction may also be present in such cases. Mild pyelectasia can be an indication of active or prior pyelonephritis but may also be seen in patients treated with IV fluid therapy. Mild pelvic dilation can be present in patients with chronic renal disease. Patients with obstructed renal pelvises secondary to ureteroliths or strictures demonstrate significantly more dilation of the



## PATIENT

Potat Robertson

Clinical Syndromes  
Frequently Associated  
with the Sonogram

## SPECIES

Canine

## BREED

Yorkshire Terrier x

## SEX

Neutered Male

## AGE

5 Years

## WEIGHT

18.8 lbs

## INTERPRETED BY

Eric Lindquist, DMV,  
DABVP (CFM), Cert.  
IVUSS

## IMAGING PERFORMED BY

Dr. Hurley

## HOSPITAL NAME

Bayshore Veterinary  
Hospital

## REFERRING VET

Dr. Hurley

## INVOICE

73598

## DATE

3/9/26

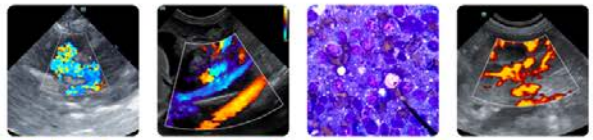
## PU/PD

renal pelvis than those with pyelonephritis or who are undergoing fluid therapy.

The liver should be evaluated for multiple parameters given that liver failure can cause PU/PD or may be indirectly related to diseases that can cause PU/PD. For example, the size will be subnormal in the face of cirrhosis but enlarged in patients with Cushing's and diabetes. Echogenicity, hyperechogenicity, and homogeneity are characteristic of Cushing's disease and diabetes. The liver may be mottled, hypoechoic, or hyperechoic in cases of lymphoma, which can cause hypercalcemia and PU/PD; the notation of hepatic nodules may indicate liver failure or cirrhosis, benign nodular hyperplasia, or malignancy. The adrenal glands can be measured, as they are often, but not always, enlarged in cases of Cushing's disease, whereas they may be small in cases of Addison's. The presence of a mass can indicate an adrenal tumor causing Cushing's disease. The bladder should be assessed for wall thickness, as it may be increased secondary to chronic urinary tract infection (UTI) in cases of diabetes, Cushing's disease, and pyelonephritis. The presence of stones may be secondary to chronic UTI, Cushing's disease, and liver failure (the latter is especially indicated by the presence of ammonium biurate stones). It should be noted that an infection of the lower urinary tract does not cause PU/PD; however, this would predispose the patient to ascending pyelonephritis. The echogenicity of the spleen may be increased or decreased in cases of lymphoma, and the presence of nodules may indicate malignancy or benign nodular hyperplasia.

**ADVANCED BLOOD TESTING** An ACTH stimulation test or low-dose dexamethasone suppression test must be performed prior to assessing for diabetes insipidus or psychogenic polydipsia.

**EVALUATION OF RENAL FUNCTION** Early renal disease can cause PU/PD without resulting in an elevation in BUN or creatinine. In these cases, SDMA and/or cystatin C would be elevated; however, if SDMA and/or cystatin C is normal, then specific renal function can be assessed practically in hospital using an iohexal clearance test (preferable) or, less commonly, an endogenous creatinine clearance test. The disadvantage of the latter is that it requires 24-hour urine collection with a closed urinary catheter collection system. A more advanced and specific way to evaluate renal function involves using nuclear scintigraphy and measuring the glomerular filtration rate (GFR); however, this procedure is usually only available at select tertiary referral centers. The iohexal clearance test is easily administered and the results are calculated from a computerized model of the GFR. The protocol for administering the test is as follows: the patient should not be fed for 12 hours prior but should be well hydrated. Give 300 mg/kg IV (slow push) and mark the time of injection to the nearest minute. Collect blood samples at two, three, and four hours to the nearest minute, and mark times on the samples. The serum samples should then be submitted to the Michigan State University Diagnostic Lab for a GFR study. Adverse effects of the iohexal are



## PATIENT

Potat Robertson

## SPECIES

Canine

## BREED

Yorkshire Terrier x

## SEX

Neutered Male

## AGE

5 Years

## WEIGHT

18.8 lbs

## INTERPRETED BY

Eric Lindquist, DMV,  
DABVP (CFM), Cert.  
IVUS

## IMAGING PERFORMED BY

Dr. Hurley

## HOSPITAL NAME

Bayshore Veterinary  
Hospital

## REFERRING VET

Dr. Hurley

## INVOICE

73598

## DATE

3/9/26

Clinical Syndromes  
Frequently Associated  
with the Sonogram


PU/PD

rare, but include anaphylactic/anaphylactoid reactions, hypotension, arrhythmias, acute renal failure, nausea, and vomiting. Pretreatment with diphenhydramine can reduce the occurrence of anaphylactic/anaphylactoid reactions. The normal values for dogs are a mean of 5.48 mL/kg/min and a range of 2.89–8.07 mL/kg/min, and for cats, a mean of 1.94 mL/kg/min and a range of 1.15–2.73 mL/kg/min.

One performs an endogenous creatinine clearance by placing a urinary catheter with a closed collection system in the patient. All the urine should be collected and saved in a refrigerator for exactly 24 hours. The urine volume should be measured accurately with a graduated cylinder or syringe and recorded. An aliquot of urine (5 mL) is subsequently sent to the laboratory for a creatinine measurement. In addition, a serum sample is collected around the 12-hour point and submitted for creatinine analysis. The creatinine clearance is then estimated using an equation that considers the creatinine levels in both the serum and the urine, the time of urine collection, and the urine volume. Creatinine clearance = {urine creatinine (mg/dL) X urine volume (mL)} / {time (min) X serum creatinine (mg/dL) X body weight (kg)}. Results are expressed in mL/min/kg. Normal values for dogs are 2.4–5 mL/min/kg and 1.9–5 mL/min/kg for cats. A decrease in the GFR by 66% correlates with isosthenuria, and a decrease of 75% correlates with azotemia.

**IN SEARCH OF CUSHING'S DISEASE** If the estimated renal function is normal and urine specific gravity is consistently < 1.020, then urine cortisol:creatinine ratio (UCCR) should be utilized. If UCCR is elevated in these cases, then a low-dose dexamethasone suppression test (LDDST) or an ACTH stimulation test can be performed to assess for Cushing's disease. In cases where the likelihood of Cushing's is low, a urine cortisol:creatinine ratio (UCCR) can be run on a urine sample obtained at home. If the results are negative, Cushing's disease can be ruled out; however, if they are positive, they are not necessarily conclusive, and additional testing for Cushing's will be required. Combined PCR on serum and urine is the best option for ruling out leptospirosis, especially when paired with convalescent titers 2–3 weeks later to avoid vaccine interference and false positive results. Once all causes of PU/PD other than central diabetes insipidus, primary nephrogenic diabetes insipidus, and psychogenic polydipsia (a diagnosis made by exclusion) have been ruled out, then one can either perform a modified water deprivation test or pursue an even more practical approach: trial therapy with vasopressin to assess response to ADH supplementation. The modified water deprivation test (MWDI) is not typically recommended anymore, as it can result in rapid dehydration and acute renal decompensation in PU/PD patients, especially in those with non-azotemic renal disease.

**TRIAL THERAPY WITH DESMOPRESSIN** A trial with desmopressin therapy at home may not yield a definitive diagnosis but can be less expensive and safer than performing a MWDI. The desmopressin can be given as an intraconjunctival drop



## PATIENT

Potat Robertson

## SPECIES

Canine

## BREED

Yorkshire Terrier x

## SEX

Neutered Male

## AGE

5 Years

## WEIGHT

18.8 lbs

## INTERPRETED BY

Eric Lindquist, DMV,  
DABVP (CFM), Cert.  
IVUS

## IMAGING PERFORMED BY

Dr. Hurley

## HOSPITAL NAME

Bayshore Veterinary  
Hospital

## REFERRING VET

Dr. Hurley

## INVOICE

73598

## DATE

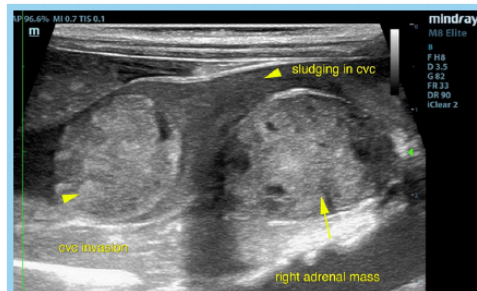
3/9/26

Clinical Syndromes  
Frequently Associated  
with the Sonogram

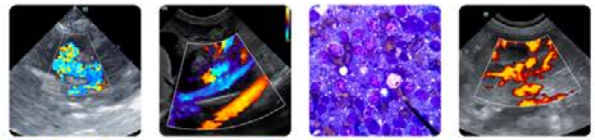
PU/PD

twice daily; the urine specific gravity and water intake should be measured after one week. Alternatively, and likely easier, the desmopressin can be given as an oral tablet. Current dosage recommendations are 0.1 mg tablet/20 kg dog PO TID for seven days or 0.2 mg tablet/40 kg dog PO TID for seven days; urine specific gravity and water consumption should be reevaluated after this time. If the water intake dramatically decreases and the urine specific gravity increases by more than 50%, then this is strongly indicative of chronic kidney disease, provided Cushing's has been ruled out. It is recommended that one attempts to reestablish the medullary concentration gradient before trial therapy. This would entail gradually reducing the patient's water intake to within normal range (60–80 mL/kg/day) over several days prior to initiating the desmopressin therapy. This should only be done once the possibility of non-azotemic renal disease has been excluded using renal function testing.

**TREATMENT** Treatment for secondary causes of PU/PD is based on the primary disease that is diagnosed. For example, specific therapy for cases of Cushing's disease, diabetes mellitus, or pyelonephritis would be implemented first before treating for PU/PD specifically. In other words, the actual resolution of PU/PD depends on the etiology. Therapy for central diabetes insipidus is based on the supplementation of an exogenous form of ADH. Desmopressin intranasal spray (1–4 drops in the conjunctival sac Q12–24hr, titrated to resolve the PU/PD) is most commonly used. Oral desmopressin can also be tried, although an exact dose is unknown and reported dosing strategies vary depending on the source (e.g., the dose range is 1/4–1/2 of a 0.1–0.2 mg tablet PO Q12–24hr or 0.1–0.2 mg PO Q8hr; adjust as needed to control signs). Additional medical therapy for partial central diabetes insipidus consists of enhancing the effects of ADH at the level of the kidney using chlorpropamide or thiazide diuretics and feeding the patient a diet low in sodium. Congenital nephrogenic diabetes insipidus is treated with salt restriction and thiazide diuretics. Psychogenic PU/PD can be managed with slow gradual water restriction. The therapies for partial central diabetes insipidus, primary nephrogenic diabetes insipidus, and psychogenic polyuria are not fully effective.



Right adrenal mass in a dog presented for PU/PD and suspicion for Cushing's syndrome. The right adrenal is imaged in SDEP® Position 14 demonstrating tumor invasion of the caudal vena cava and excessive blood contrast owing to sludging. Given the global clinical sonographic presentation, functional invasive right adrenal carcinoma was suspected.



## PATIENT

Potat Robertson

## SPECIES

Canine

## BREED

Yorkshire Terrier x

## SEX

Neutered Male

## AGE

5 Years

## WEIGHT

18.8 lbs

## INTERPRETED BY

Eric Lindquist, DMV,  
DABVP (CFM), Cert.  
IUUS

## IMAGING PERFORMED BY

Dr. Hurley

## HOSPITAL NAME

Bayshore Veterinary  
Hospital

## REFERRING VET

Dr. Hurley

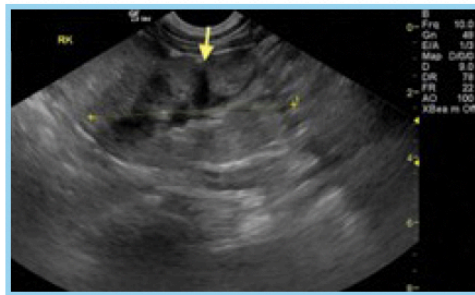
## INVOICE

73598

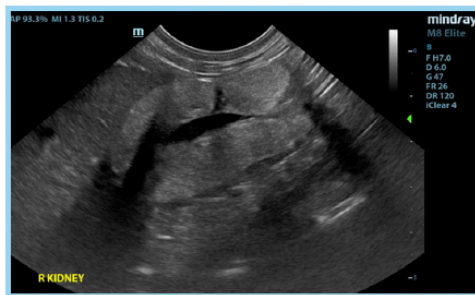
## DATE

3/9/26

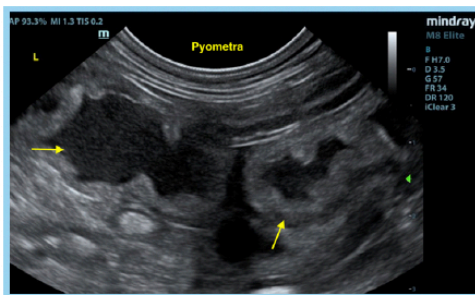
Clinical Syndromes  
Frequently Associated  
with the Sonogram



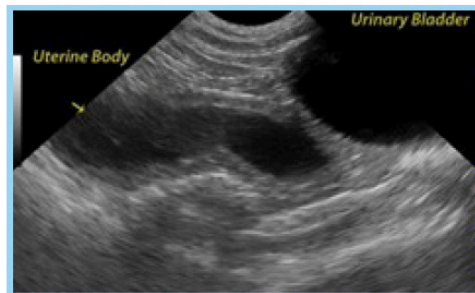Long axis of the right kidney in a one-year-old Boxer dog with congenital renal dysplasia. Note the generalized enlargement, nodular renal cortices, increased cortical echogenicity, abnormal corticomedullary ratio, and disorganized arrangement of the renal pyramids (arrow). Similar changes were noted in the left kidney.



Juvenile large-breed dog presented for PU/PD and azotemia/renal failure. The right kidney is subnormal in size with echogenic nodular cortex and loss of corticomedullary structure and definition. The renal pelvis is dilated without evidence of inflammation. This presentation is strongly consistent with primary renal dysplasia. SDEP® Position 14.

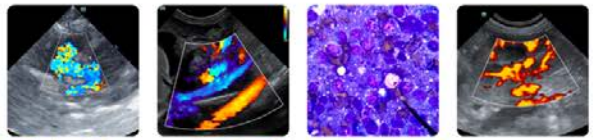


Intact, female Yorkshire Terrier dog approximately three weeks post heat presented for PU/PD. The uterus is dilated with mildly echogenic fluid with undulating mural contour. Diagnosis: Pyometra. Arrows indicate the fluid-filled uterine lumen and thickened echogenic wall respectively. SDEP® Position 17.



Long axis of the caudal abdomen in a dog with a pyometra. The uterine body (arrow) is moderately dilated and filled with hypoechoic content. Note the minor cystic changes within the thickened uterine wall. The vertex of the urinary bladder is seen in the near field on the image right.

PU/PD



## PATIENT

Potat Robertson

## SPECIES

Canine

## BREED

Yorkshire Terrier x

## SEX

Neutered Male

## AGE

5 Years

## WEIGHT

18.8 lbs

Clinical Syndromes  
Frequently Associated  
with the Sonogram

PU/PD

## REFERENCES

1. Bexfield NH, Heiene R, Gerritsen RJ, et al. Glomerular filtration rate estimated by 3 sample plasma clearance of Iohexal in 118 healthy dogs. *J Vet Intern Med* 2008; 22: 66-73.
2. Bruyette D: Approach to the Patient with Polyuria and Polydipsia. World Small Animal Veterinary Association World Congress Proceedings 2015.
3. Feldman EC and Nelson RW. Water metabolism and diabetes insipidus. In: Feldman EC and Nelson RW, eds. *Canine and Feline Endocrinology and Reproduction, 2nd ed.* Philadelphia, PA: WB Saunders; 1996: 2-37.
4. Shiel RC. Polyuria and polydipsia. In: Ettinger SJ, Feldman EC, Cote E, eds. *Textbook of Small Animal Internal Medicine, 8th ed.* Saint Louis, MO: Elsevier; 2017: 181-85.
5. Galgut B: Understanding the Polyuric/Polydipsic Animal. Western Veterinary Conference Proceedings 2013.
6. Shiel RE. Diabetes insipidus. In: Ettinger SJ, Feldman EC, Cote E, eds. *Textbook of Small Animal Internal Medicine, 7th ed.* Saint Louis, MO: Elsevier; 2017: 1710-14.

## INTERPRETED BY

Eric Lindquist, DMV,  
DABVP (CFM), Cert.  
IVUSS

## IMAGING PERFORMED BY

Dr. Hurley

## HOSPITAL NAME

Bayshore Veterinary  
Hospital

## REFERRING VET

Dr. Hurley

## INVOICE

73598

## DATE

3/9/26