



## PATIENT

Morgan Crane

## SPECIES

Canine

## BREED

Cockapoo

## SEX

Spayed Female

## AGE

14

## WEIGHT

22.2

## INTERPRETED BY

Eric Lindquist, DMV,  
DABVP(CFM), Cert.  
IVUSS

## IMAGING PERFORMED BY

Jenn

## HOSPITAL NAME

Rockaway Animal  
Hospital

## REFERRING VET

Dr. Maniar

## INVOICE

14149

## DATE

03/09/26

## PRESENTING CLINICAL SIGNS

- V/D

Abnormal PE/Chem/CBC/UA Results: TP 8.7 ALB 4.0 Glob 4.7 ALP 236 Lipase 316

## ULTRASONOGRAPHIC EXAMINATION OF THE ABDOMEN

### Urinary System

The **urinary bladder**, trigone, and pelvic urethra to a depth of 1.0 cm presented normal thicknesses and normal tone. The ureters were not visible which is normal. No uroliths or sediment were visualized, and anechoic urine was present. No evidence of inflammatory or neoplastic changes were noted. Ureteral papillae were normal.

The **kidneys** revealed largely normal size and structure, corticomedullary definition and ratio (cortex 1/3 of medulla) were essentially maintained with some mild age-related loss of curvilinear patterns regarding the capsule and C/M junction. The cortices presented largely uniform texture with some increased echogenicity expected for his age patient. Medullary structure differed distinctly from that of the cortex and no evidence of pelvic dilation was present. The left kidney measured 3.9 cm in length. The right kidney measured 4.5 cm in length.

### Adrenal Glands

Both **adrenal glands** were visualized and recognized as having normal shape, size, position and echogenicity for this breed. The phrenic vasculature, glandular echogenicity and detail were unremarkable. Capsule, cortex, and medullary definition were normal for this age patient. The left adrenal gland measured 1.05 cm x 0.42 cm width at the caudal pole and 0.46 cm width at the cranial pole. The right adrenal gland measured 0.50 cm width.

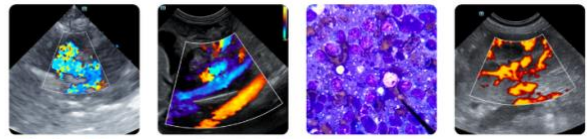
### Spleen

The **spleen** presented a smooth homogeneous parenchyma hyperechoic to liver and renal cortical parenchyma. The capsule was smooth without noticeable expansion or deviation from within the spleen or adjacent pathology. The splenic vasculature demonstrated normal volume without signs of congestion or thrombosis. No sonographic evidence of acute or chronic inflammatory, neoplastic, or infarctual changes were noted.

### Liver

The **liver** images from right and left intercostal as well as subcostal views revealed subjectively normal liver size, contour, and structure. Some age-related parenchymal remodeling was noted but likely not clinically significant at this time. Vascular and biliary tracts were of normal volume, and no evidence of congestion was noted. The gallbladder presented some dependent debris with essentially normal contour. The cystic and common bile ducts were normal. No overt evidence of active inflammatory, infiltrative or regenerative pathology was noted but should be paired with current or past LE elevations regarding any clinical significance to this presentation. The hepatic lymph nodes were unremarkable.

### Gastrointestinal



**PATIENT**

Morgan Crane

**SPECIES**

Canine

**BREED**

Cockapoo

**SEX**

Spayed Female

**AGE**

14

**WEIGHT**

22.2

**INTERPRETED BY**

Eric Lindquist, DMV,  
DABVP(CFM), Cert.  
IVUSS

**IMAGING PERFORMED BY**

Jenn

**HOSPITAL NAME**

Rockaway Animal  
Hospital

**REFERRING VET**

Dr. Maniar

**INVOICE**

14149

**DATE**

03/09/26

Examination of the **gastrointestinal tract** revealed a stomach and intestine free of stasis, of normal wall thickness, acceptable curvilinear mural detail, and peristaltic activity. Small and large intestine demonstrated normal luminal chyme and stool consistency respectively. No obstructive or overt infiltrative disease was noted. No associated abnormal lymphatic activity was noted.

**Pancreas**

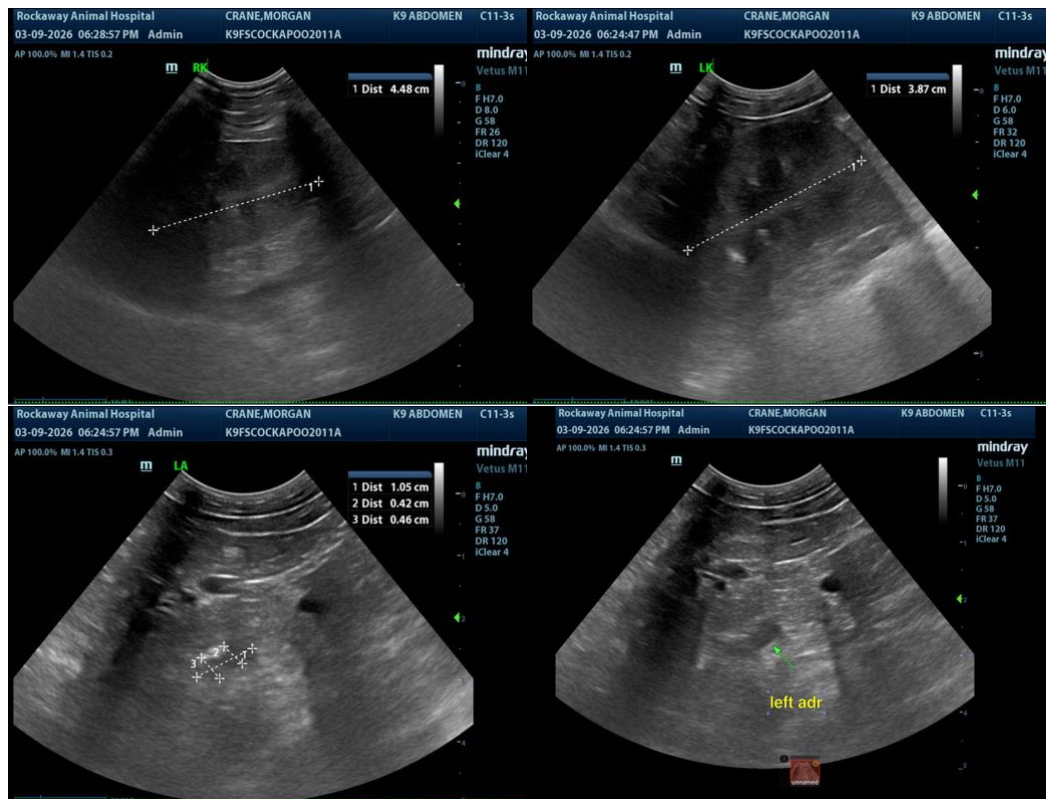
The base and limbs of the **pancreas** were observed to be largely isoechoic to surrounding omental fat. Pancreatic duct and capsular contour were acceptably normal and parenchyma respected normal curvilinear patterns. No overt evidence of active inflammatory or neoplastic disease was noted.

**ULTRASONOGRAPHIC FINDINGS**

- Benign abdomen.
- Minor excessive gallbladder debris.

**INTERPRETATION OF THE FINDINGS & FURTHER RECOMMENDATIONS**

No evidence of pathology. Supportive care should prove effective. Dietary indiscretion, food intolerance, structurally insignificant inflammatory bowel or occult parasitism and occult Addison's are all potentials.





## PATIENT

Morgan Crane

## SPECIES

Canine

## BREED

Cockapoo

## SEX

Spayed Female

## AGE

14

## WEIGHT

22.2

## INTERPRETED BY

Eric Lindquist, DMV,  
DABVP(CFM), Cert.  
IVUSS

## IMAGING PERFORMED BY

Jenn

## HOSPITAL NAME

Rockaway Animal  
Hospital

## REFERRING VET

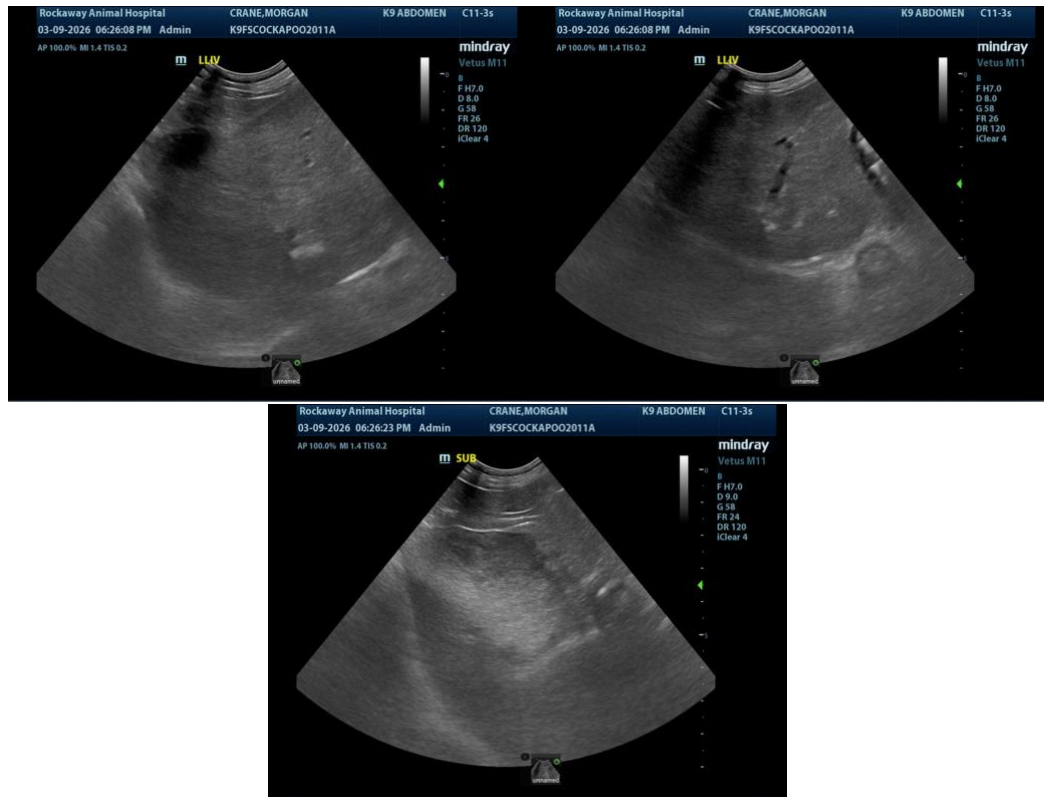
Dr. Maniar

## INVOICE

14149

## DATE

03/09/26



The information and recommendations provided are based on the images presented by the referring veterinarian/sonographer. No evaluation can be communicated regarding pathology that was not visible in the image/video clips provided.

Thank you for this referral. If the clinical or image interpretation does not parallel your findings or if I can be of any further assistance, please contact me.

**Eric Lindquist, DMV, DABVP(CFM), Cert. IVUSS,**

CEO, Owner, Founder -- SonoPath.com

[info@SonoPath.com](mailto:info@SonoPath.com)