



PATIENT

Freckles Jacobs

SPECIES

Canine

BREED

Freyhound

SEX

Spayed Female

AGE

11 Years 1 Month

WEIGHT

59 Pounds

INTERPRETED BY

Eric Lindquist, DMV,
DABVP (Canine & Feline), Cert. IVUSS

IMAGING PERFORMED BY

Vincent Ravancho,
CVT

HOSPITAL NAME

Legacy AH

REFERRING VET

Dr. Potenzone

INVOICE

36152

DATE

3/9/26

PRESENTING CLINICAL SIGNS

- Pre-Sx workup
- Getting hemangioma or hemangiosarcoma removal (SubQ)
- Current medications – Gabapentin
- Abnormal PE/Chem/CBC/UA Results: Creat 2.5 BUN 35 BNP 3943

ULTRASONOGRAPHIC EXAMINATION OF THE HEART

CANINE CARDIAC PARAMETERS	MR VMAX (m/s)	TR VMAX (m/s)	LA/AO (M-Mode)	LA/AO (Heart Base; Swe)	FS (%)	EF (%)	EPSS (cm)
NORMAL PARAMETER	4.5-5.5	<2.7	1.3	Up to 1.6	28-40	40-100	<0.6
PATIENT	5.02	--	1.2	1.1	40	60	0.2
CANINE CARDIAC PARAMETERS	HR (BPM)	AV VMAX (m/s)	PV MAX (m/s)	BODY WEIGHT (lbs)	LAD LA MAX 4 Chamber	LVIDd Avg; 2D and m-mode short axis (cm)	LVIDs Avg; 2D and m-mode short axis (cm)
NORMAL PARAMETER	50-100	0.7-1.7	0.7-1.6				
PATIENT	--	2.10	.77	59 lbs	4.02	4.1	--

Cardiac Presentation

The echocardiogram in this patient demonstrated normal **left atrial** size based on 3 different LA measurement methods. Chamber volumes and echogenicity were normal. The cranial and caudal **mitral** valve leaflets presented vegetative thickening consistent with endocardiosis. Doppler indicated minor insufficiency. The **left ventricle** presented thicknesses with linear contour and was not dilated nor restricted. The **myocardium** presented normal echogenicity without subjective evidence of significant fibrotic or ischemic disease. **Contractility** of the ventricular walls was adequate and in normal range for this patient evidenced by the fractional shortening measurement and subjective evaluation of the different regions of the myocardium. Aortic insufficiency was noted (aortic insufficiency velocity 6.0 m/s). The **right atrium** and auricle revealed normal size, structure and content. No evidence of masses was noted or chamber overload. **Tricuspid** valvular assessment demonstrated adequate linear morphology. The **right ventricle** was of normal size (1/3 diameter of LV), chordae structure, myocardial echogenicity and thickness. **Pulmonic** tract assessment revealed normal valve structure, laminar flow, and diameter (approx.1:1 pa/ao ratio). No visible **pericardial** or free pleura fluid was noted. No echographically detectable evidence of infiltrative disease was visible. The cranial **mediastinum and pericardial regions** were free of masses in the visible window.



PATIENT

Freckles Jacobs

SPECIES

Canine

BREED

Freyhound

SEX

Spayed Female

AGE

11 Years 1 Month

WEIGHT

59 Pounds

INTERPRETED BY

Eric Lindquist, DMV,
 DABVP (Canine & Feline), Cert. IVUSS

IMAGING PERFORMED BY

Vincent Ravancho, CVT

HOSPITAL NAME

Legacy AH

REFERRING VET

Dr. Potenzone

INVOICE

36152

DATE

3/9/26

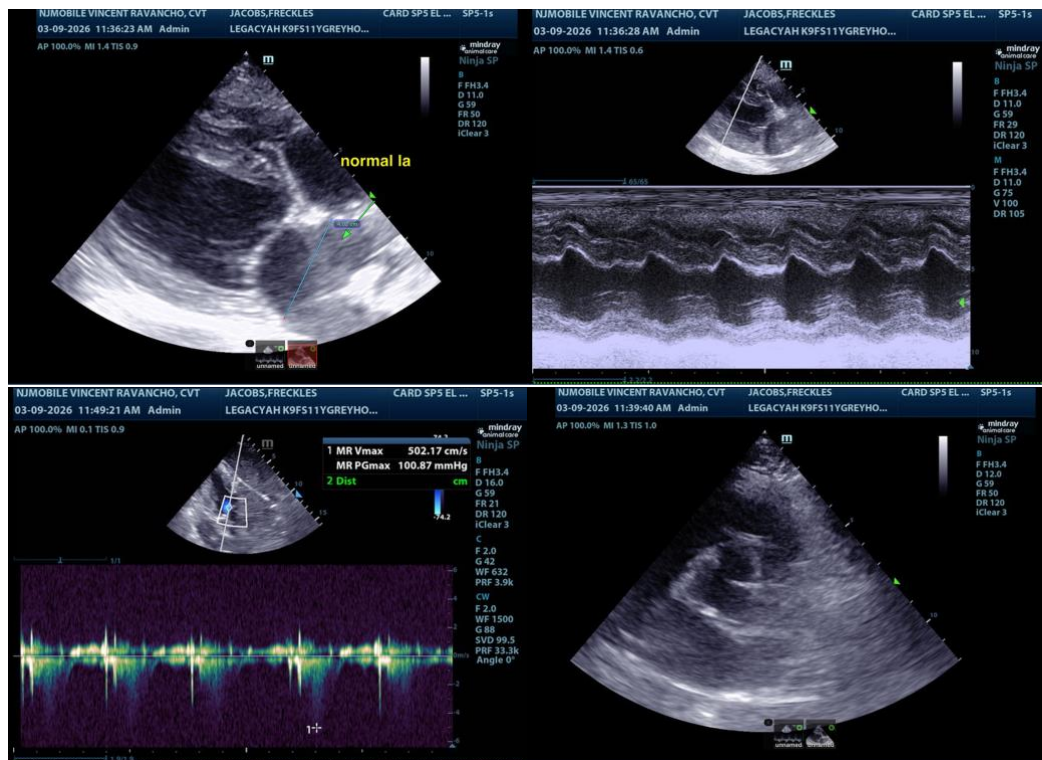
ULTRASONOGRAPHIC FINDINGS

- Stage B-1 valvular disease, minor
- Aortic insufficiency

INTERPRETATION OF THE FINDINGS & FURTHER RECOMMENDATIONS

Aortic insufficiency velocities would suggest a hypertension. Serial blood pressures are essential in this patient.

The heart is stable without clinical disease. No overt contraindication for anesthesia of brief to moderate duration. I suggest Torbutrol premed, Propofol induction, Isoflor maintenance or similar protocol if anesthesia is desired. Blood pressure recommended if not already performed and target white coat negative systolic pressure of < 160 mmHg. If higher than this ACE-inhibitor is suggested to reach this level. Recheck echocardiogram is recommended in 6 months, earlier if murmur grade increases or clinical signs initiate.





PATIENT

Freckles Jacobs

SPECIES

Canine

BREED

Freyhound

SEX

Spayed Female

AGE

11 Years 1 Month

WEIGHT

59 Pounds

INTERPRETED BY

Eric Lindquist, DMV,
 DABVP (Canine &
 Feline), Cert. IVUSS

IMAGING PERFORMED BY

Vincent Ravancho,
 CVT

HOSPITAL NAME

Legacy AH

REFERRING VET

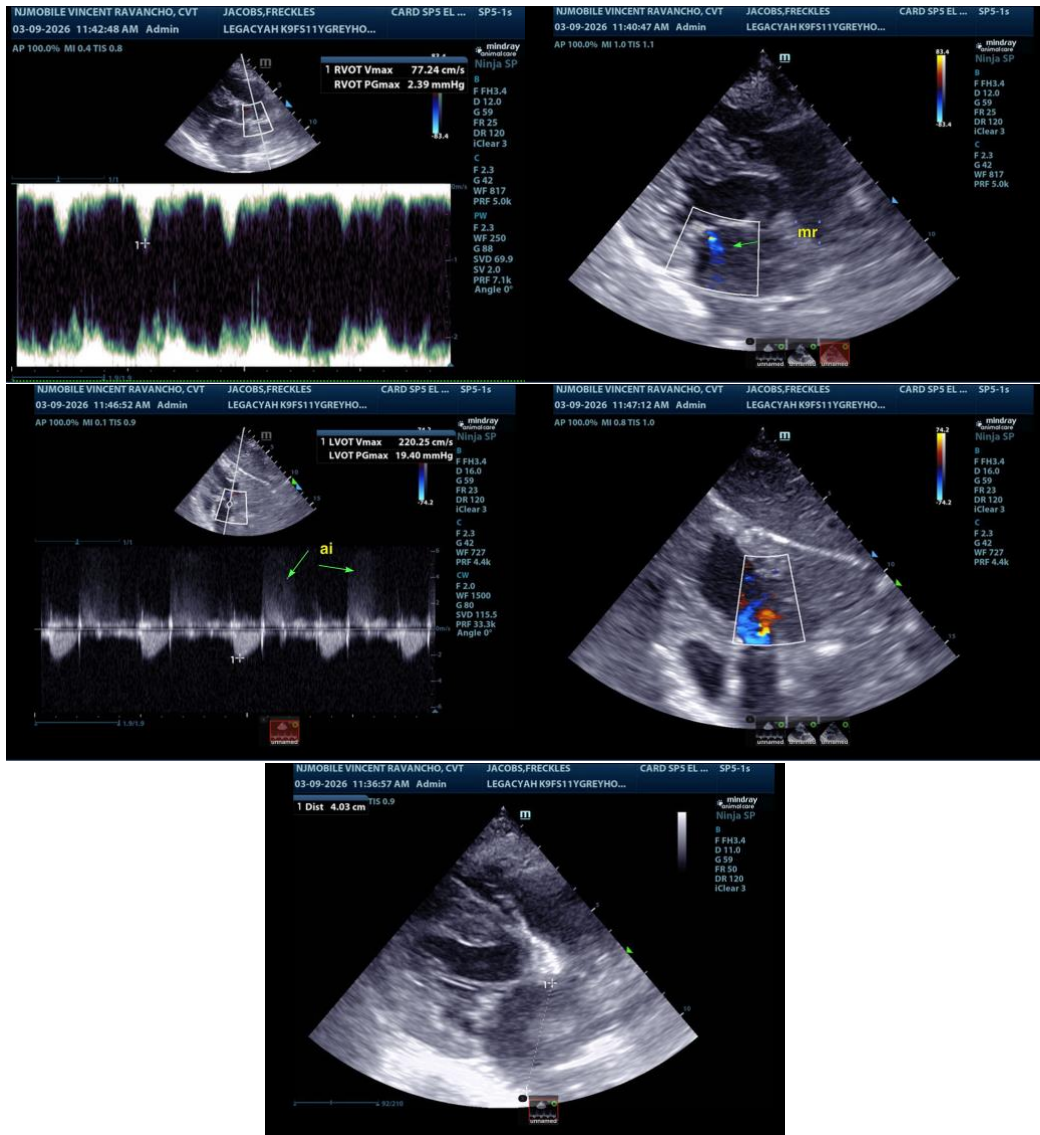
Dr. Potenzone

INVOICE

36152

DATE

3/9/26



The information and recommendations provided are based on the images presented by the referring veterinarian/sonographer. No evaluation can be communicated regarding pathology that was not visible in the image/video clips provided.

Thank you for this referral. If the clinical or image interpretation does not parallel your findings or if I can be of any further assistance please contact me.

Eric Lindquist, DMV, DABVP(CFM), Cert. IVUSS,
 CEO, Owner, Founder -- SonoPath.com
info@SonoPath.com