



**PATIENT**

Zoey Negrin

**SPECIES**

Feline

**BREED**

DSH

**SEX**

Spayed Female

**AGE**

12 Years

**WEIGHT**

8.2 Pounds

**INTERPRETED BY**

Eric Lindquist, DMV  
DABVP, Cert. IVUSS

**IMAGING PERFORMED BY**

Dr. Barnea

**HOSPITAL NAME**

Tenafly VC

**REFERRING VET**

Dr. Barnea

**INVOICE**

21605

**DATE**

3/9/23

**PRESENTING CLINICAL SIGNS**

History: f/u gi only us has normal us 12/22 and full gi/bw work up --all normal r/o ibd great response to depo inj --nmo vomiting and gained weight on EN diet ,no w that stated vomiting may try ha or zd for few month and switch to oral pred to be used at home

\*\*9 Still images and 2 videos submitted.

**LIMITED ULTRASONOGRAPHIC EXAMINATION**

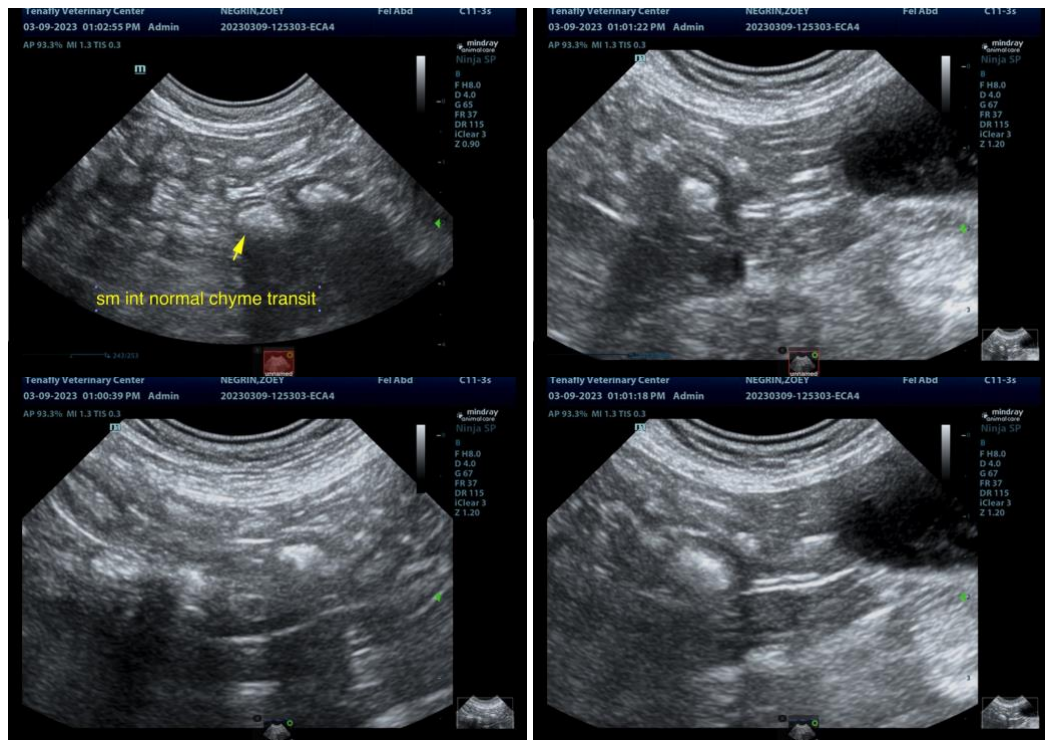
Curvilinear patterns were maintained throughout the GI tract. Hyperperistalsis was present. No evidence of lymphadenopathy or obstructive disease.

**ULTRASONOGRAPHIC FINDINGS**

- Hyperperistaltic small intestine without structural change or obstruction

**INTERPRETATION OF THE FINDINGS & FURTHER RECOMMENDATIONS**

No evidence of significant pathology.



The information and recommendations provided are based on the images presented by the referring veterinarian. No evaluation can be communicated regarding pathology that was not visible in the image/video clips provided.

Thank you for this referral. If the clinical or image interpretation does not parallel your findings or if I can be of any further assistance please contact me.



**PATIENT**

**Eric Lindquist**, DMV, DABVP, Cert. IVUSS, CEO of SonoPath.com  
info@SonoPath.com

Zoey Negrin

**SPECIES**

Feline

**BREED**

DSH

**SEX**

Spayed Female

**AGE**

12 Years

**WEIGHT**

8.2 Pounds

**INTERPRETED BY**

Eric Lindquist, DMV  
DABVP, Cert. IVUSS

**IMAGING  
PERFORMED BY**

Dr. Barnea

**HOSPITAL NAME**

Tenaflly VC

**REFERRING VET**

Dr. Barnea

**INVOICE**

21605

**DATE**

3/9/23