



PATIENT PRESENTING CLINICAL SIGNS

Oaklan Stanley

History: History of intermittent dribbling urine and trouble housebreaking. Gave SQ fluids to increase bladder size, but urinated in cage.

SPECIES

Abnormal PE/Chem/CBC/UA Results: PE: dry around vulva, small/"rumpy" tail. RADS: NSF BW: WNL USG 1.041, rest WNL.

Canine

BREED

ULTRASONOGRAPHIC EXAMINATION OF THE ABDOMEN

Urinary System

French Bulldog

The **urinary bladder** presented a minimal amount of urine, yet there was no overt ectopic ureters at the time of the sonogram. The iliac trifurcation was unremarkable.

SEX

The uterus was thickened and measured 1.0 cm. Active heat cycle is suspected.

Intact Female

The **kidneys** revealed normal size and structure, corticomedullary definition and ratio for this age. The cortices presented largely uniform texture with normal echogenic relationship to liver and spleen. Medullary structure differed distinctly from the cortex and no evidence of pelvic dilation was present. The capsules were acceptably uniform without significant irregularities. The right kidney measured 3.73 cm. The left kidney measured 4.07 cm.

AGE

7 months

WEIGHT

12 lbs

Adrenal Glands

Both **adrenal glands** were visualized and recognized as having normal shape, size, position and echogenicity for this breed. The phrenic vasculature, glandular echogenicity and detail were unremarkable. Capsule, cortex, and medullary definition were normal for this age patient. The left adrenal gland measured 0.42 cm at the caudal pole and 0.49 cm at the cranial pole. The right adrenal gland measured 2.1 x 1.22 cm at the cranial pole and 0.72 cm at the caudal pole.

INTERPRETED BY

Eric Lindquist, DMV
DABVP, Cert. IVUSS

IMAGING PERFORMED BY

Dr. Ebersole

Spleen

The **spleen** presented a smooth homogeneous parenchyma hyperechoic to liver and renal cortical parenchyma. The capsule was smooth without noticeable expansion or deviation from within the spleen or adjacent pathology. The splenic vasculature demonstrated normal volume without signs of congestion or thrombosis. No sonographic evidence of acute or chronic inflammatory, neoplastic, or infarctual changes was noted.

HOSPITAL NAME

Scanvet

REFERRING VET

Dr. Barengo

Liver

The **liver** images submitted revealed subjectively normal liver size, contour, and structure. Parenchymal echogenicity was naturally coarse and hypoechoic to the spleen. Vascular and biliary tracts were of normal volume with no evidence of congestion. The gallbladder presented acceptably thin walls with primarily anechoic content. The cystic and common bile ducts were normal. No pathological hepatic lymphadenopathy was evident. No overt structural evidence of inflammatory, infiltrative or regenerative pathology was evident.

INVOICE

43226

DATE

3/9/23



PATIENT

Gastrointestinal

Oaklan Stanley

Examination of the **gastrointestinal tract** revealed a stomach and intestine free of stasis, of normal wall thickness, acceptable curvilinear mural detail, and peristaltic activity. Small and large intestine demonstrated normal luminal chyme and stool consistency respectively. No obstructive or overt infiltrative disease was noted. No associated abnormal lymphatic activity was noted.

SPECIES

Canine

Pancreas

BREED

French Bulldog

The base and limbs of the **pancreas** were observed to be largely isoechoic to surrounding omental fat. Pancreatic duct and capsular contour were acceptably normal and parenchyma respected normal curvilinear patterns. No overt evidence of active inflammatory or neoplastic disease was noted.

SEX

Intact Female

ULTRASONOGRAPHIC FINDINGS

Thickened uterus.

AGE

7 months

Unremarkable bladder with a minimal amount of urine present.

WEIGHT

12 lbs

INTERPRETATION OF THE FINDINGS & FURTHER RECOMMENDATIONS

No overt ectopic ureters were noted, yet cannot be completely ruled out. If ectopic ureters are suspected and this is not heat related urinary signs then CT with contrast is indicated or recheck sonogram at full bladder may prove effective.

INTERPRETED BY

Eric Lindquist, DMV
DABVP, Cert. IVUSS

IMAGING PERFORMED BY

Dr. Ebersole

HOSPITAL NAME

Scanvet

REFERRING VET

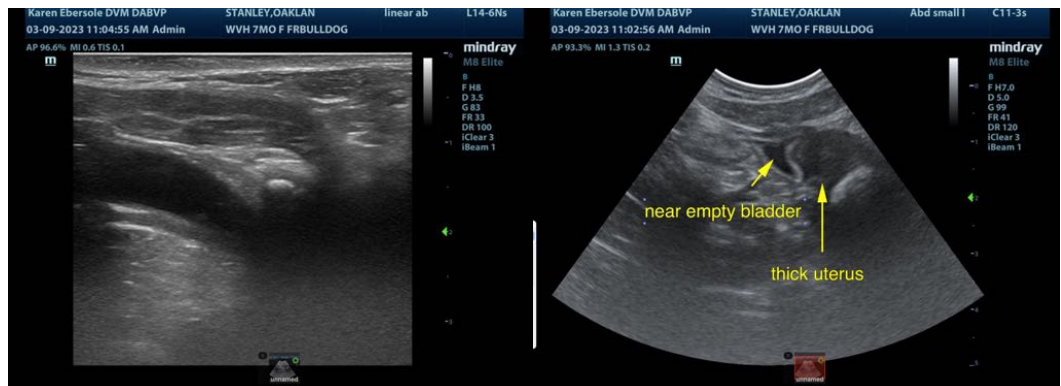Dr. Barengo

INVOICE

43226

DATE

3/9/23





PATIENT

Oaklan Stanley

SPECIES

Canine

BREED

French Bulldog

SEX

Intact Female

AGE

7 months

WEIGHT

12 lbs

INTERPRETED BY

Eric Lindquist, DMV
DABVP, Cert. IVUSS

IMAGING PERFORMED BY

Dr. Ebersole

HOSPITAL NAME

Scanvet

REFERRING VET

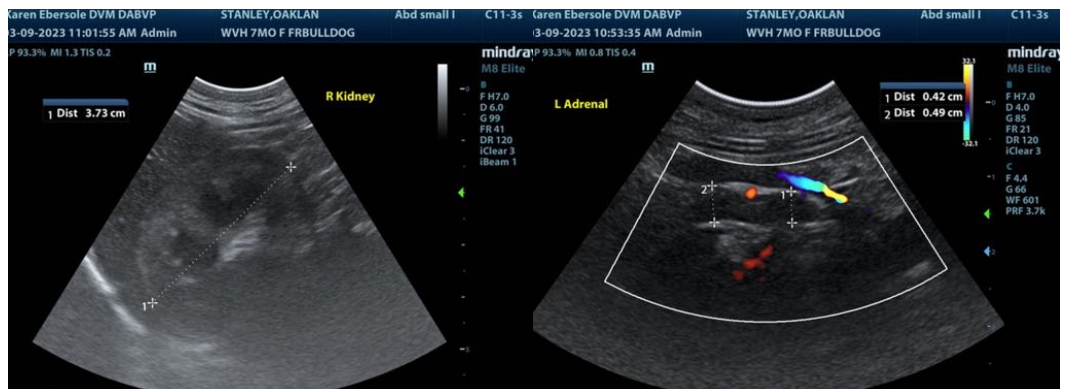
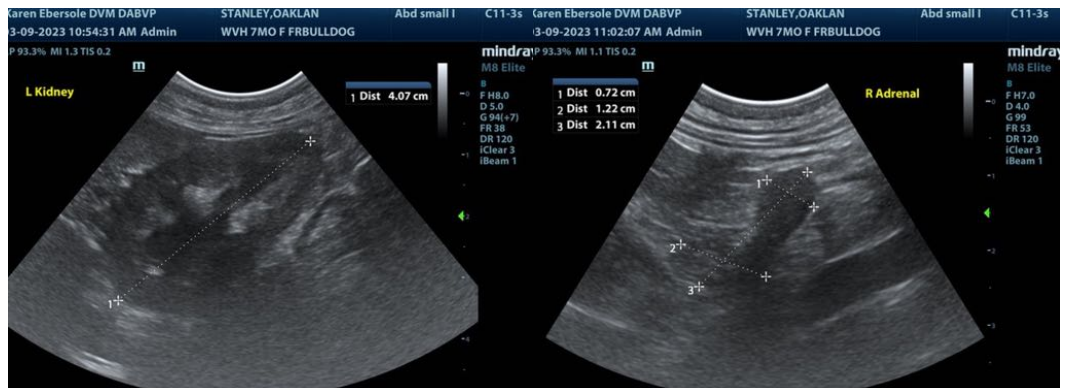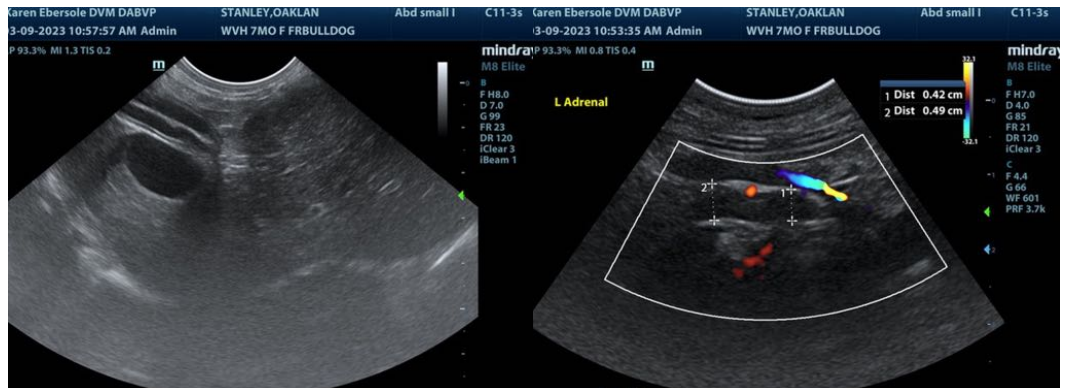
Dr. Barengo

INVOICE

43226

DATE

3/9/23



The information and recommendations provided are based on the images presented by the referring veterinarian/sonographer. No evaluation can be communicated regarding pathology that was not visible in the image/video clips provided.

Thank you for this referral. If the clinical or image interpretation does not parallel your findings or if I can be of any further assistance please contact me.

Eric Lindquist, DMV, DABVP, Cert. IVUSS, CEO of SonoPath.com
info@SonoPath.com