



PATIENT PRESENTING CLINICAL SIGNS

Bacon Sloan History: Classified as stage B2 on 8/25/2021 Tx with Pimobendan since then Hx of elevated liver enzymes
SPECIES Abnormal PE/Chem/CBC/UA Results: PE: Grade 4/6 systolic murmur CBC: NAF Chem: ALT 170

Canine

ULTRASONOGRAPHIC EXAMINATION OF THE HEART

BREED

Poodle

SEX

Neutered male

AGE

9 years

WEIGHT

7.3 lbs

The echocardiogram in this patient demonstrated normal **left atrial** size based on 3 different LA measurement methods. Chamber volumes and echogenicity were normal. The cranial and caudal **mitral** valve leaflets presented vegetative thickening consistent with endocardiosis. Doppler indicated measurable insufficiency. The **left ventricle** presented thicknesses with linear contour and was not dilated nor restricted. The **myocardium** presented normal echogenicity without subjective evidence of significant fibrotic or ischemic disease. **Contractility** of the ventricular walls was adequate and in normal range for this patient evidenced by the fractional shortening measurement and subjective evaluation of the different regions of the myocardium. The **left ventricular outflow** tract demonstrated normal laminar flow and subjective structural integrity. The **right atrium** and auricle revealed normal size, structure and content. No evidence of masses was noted or chamber overload. **Tricuspid** valvular assessment demonstrated adequate linear morphology. The **right ventricle** was of normal size (1/3 diameter of LV), chordae structure, myocardial echogenicity and thickness. **Pulmonic** tract assessment revealed normal valve structure, laminar flow, and diameter (approx.1:1 pa/ao ratio). No visible **pericardial** or free pleura fluid was noted. No echographically detectable evidence of infiltrative disease was visible. The cranial **mediastinum and pericardial regions** were free of masses in the visible window.

INTERPRETED BY

Eric Lindquist, DMV
DABVP, Cert. IVUSS

IMAGING PERFORMED BY

Mayra Sanchez

HOSPITAL NAME

Sunset AH

REFERRING VET

Dr. Polit

INVOICE

43229

DATE

3/9/23

CANINE CARDIAC PARAMETERS	MR VMAX (m/s)	TR VMAX (m/s)	LA/AO (Boon method)	LA/AO (Heart Base)	FS (%)	EF (%)	EPSS (cm)
NORMAL PARAMETER	4.5-5.5	<2.7	1.3	<1.6	28-40	40-100	<0.6
PATIENT			1.0	1.3	50		NM
CANINE CARDIAC PARAMETERS	HR (BPM)	AV VMAX (m/s)	PV MAX (m/s)	BODY WEIGHT	LA 2D short axis Base view (cm)	LVIDd Avg; 2D and m- mode short axis (cm)	LVIDs Avg; 2D and m- mode short axis (cm)
NORMAL PARAMETER	50-100	0.7-1.7	0.7-1.6	BELOW	BELOW	BELOW	BELOW
PATIENT				7.3 lbs		1.74	



PATIENT

Bacon Sloan

SPECIES

Canine

BREED

Poodle

SEX

Neutered male

AGE

9 years

WEIGHT

7.3 lbs

INTERPRETED BY

Eric Lindquist, DMV
DABVP, Cert. IVUSS

IMAGING PERFORMED BY

Mayra Sanchez

HOSPITAL NAME

Sunset AH

REFERRING VET

Dr. Polit

INVOICE

43229

DATE

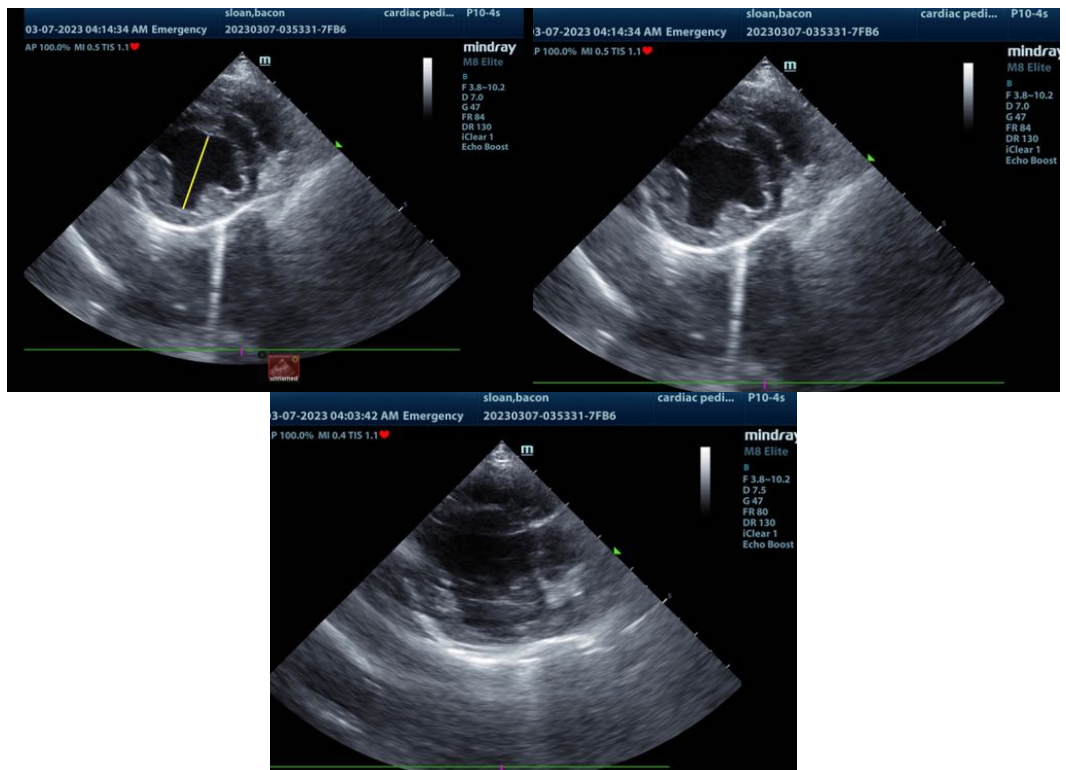
3/9/23

ULTRASONOGRAPHIC FINDINGS

Stage B1 valvular disease.

INTERPRETATION OF THE FINDINGS & FURTHER RECOMMENDATIONS

The patient is stable on the current protocol.



The information and recommendations provided are based on the images presented by the referring veterinarian/sonographer. No evaluation can be communicated regarding pathology that was not visible in the image/video clips provided.

Thank you for this referral. If the clinical or image interpretation does not parallel your findings or if I can be of any further assistance please contact me.

Eric Lindquist, DMV, DABVP, Cert. IVUSS, CEO of SonoPath.com
info@SonoPath.com