

**DATE**

3/9/22

PRESENTING CLINICAL SIGNS

Seen 3/2 for dental consult and pre-op labwork drawn, other than moderate pddz PE WNL. Labwork showed ALT of 934, came down to 510 on ¾. Performed in house ultrasound and found large gallbladder and small liver.

PATIENT

Peaches King

Current Medications: Started Denamarin 3/4.

Lab Results: See attached.

Date of Previous IntraPet Ultrasound: No previous.

Sedation: Not required to complete full diagnostic ultrasound.

Stat Report: Not requested.

Imaging Performed By: Rachel Brilhart, RDMS.

SPECIES

Canine

BREED

Poodle Mix

SEX

Spayed Female

AGE

12/17/11

WEIGHT

19.2 lbs

INTERPRETED BY

Eric Lindquist, DMV
DABVP, Cert. IVUSS

HOSPITAL NAME

Airpark AH

REFERRING VET

Dr. Herrick

INVOICE

96724

ULTRASONOGRAPHIC EXAMINATION OF THE ABDOMEN**Urinary System**

The **urinary bladder**, trigone, and pelvic urethra presented normal thicknesses and normal tone. The ureters were not visible which is normal. No uroliths or sediment were visualized and anechoic urine was present. No evidence of inflammatory or neoplastic changes was noted. Ureteral papillae were normal.

The **kidneys** revealed normal size and structure, corticomedullary definition and ratio for this age. The cortices presented largely uniform texture with normal echogenic relationship to liver and spleen. Medullary structure differed distinctly from the cortex and no evidence of pelvic dilation was present. The capsules were acceptably uniform without significant irregularities. The right kidney measured 4.62 cm. The left kidney measured 4.72 cm.

Adrenal Glands

Both **adrenal glands** were visualized and recognized as having normal shape, size, position and echogenicity for this breed. The phrenic vasculature, glandular echogenicity and detail were unremarkable. Capsule, cortex, and medullary definition were normal for this age patient. The right adrenal gland measured 1.8 x 0.5 cm at the caudal pole and 0.71 cm at the cranial pole. The left adrenal gland measured 1.82 x 0.65 cm at the caudal pole and 0.62 cm at the cranial pole.

Spleen

The **spleen** presented a smooth homogeneous parenchyma hyperechoic to liver and renal cortical parenchyma. The capsule was smooth without noticeable expansion or deviation from within the spleen or adjacent pathology. The splenic vasculature demonstrated normal volume without signs of congestion or thrombosis. No sonographic evidence of acute or chronic inflammatory, neoplastic, or infarctual changes was noted.

Liver

The **liver** images submitted revealed subjectively normal liver size, contour, and structure. Parenchymal echogenicity was naturally coarse and hypoechoic to the spleen. Vascular and biliary tracts were of normal volume with no evidence of congestion. The gallbladder presented acceptably thin walls with primarily anechoic content. The cystic and common bile ducts were normal. No pathological hepatic lymphadenopathy was evident. No overt structural evidence of inflammatory, infiltrative or regenerative pathology was evident.

Gastrointestinal

Examination of the **gastrointestinal tract** revealed a stomach and intestine free of stasis, of normal wall thickness, acceptable curvilinear mural detail, and peristaltic activity. Minor excessive GI gas was present.

Small and large intestine demonstrated normal luminal chyme and stool consistency respectively. No obstructive or overt infiltrative disease was noted. No associated abnormal lymphatic activity was noted.

Pancreas

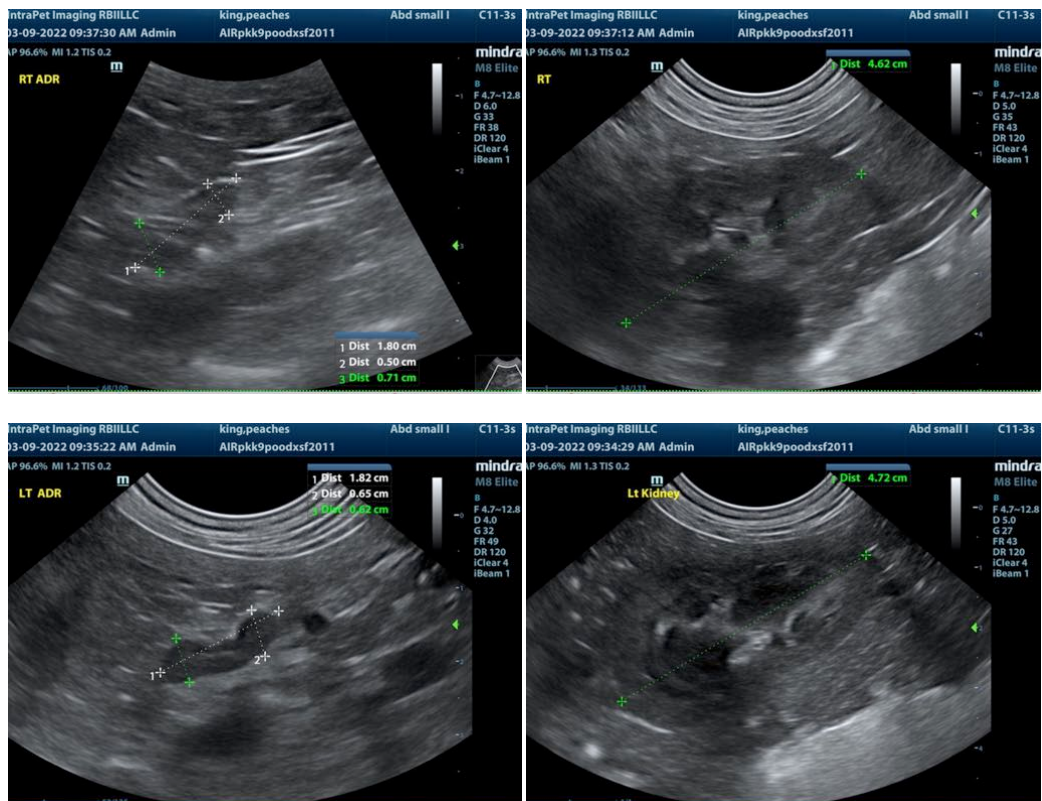
The **pancreas** was prominent, hypoechoic and irregular with enhanced surrounding mesentery. Nodular changes were noted throughout the right and left limbs with hyperechoic areas of remodeling.

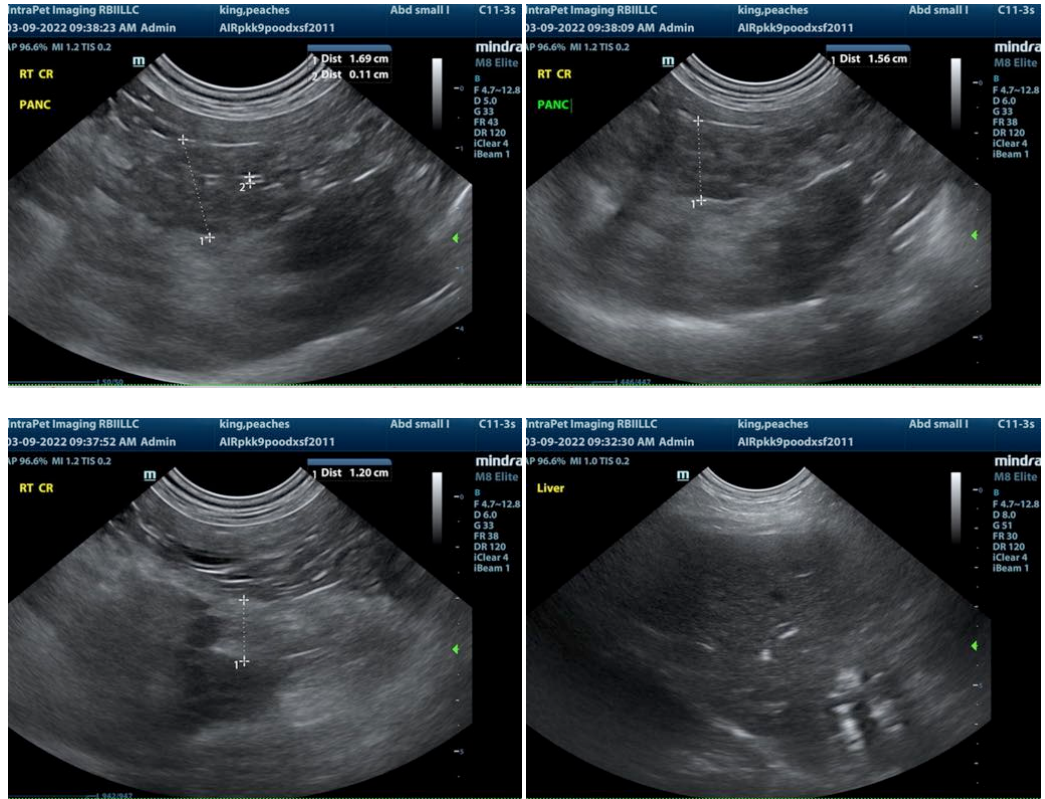
ULTRASONOGRAPHIC FINDINGS

Chronic active pancreatitis presentation and nodular hyperplasia pattern. Otherwise, age related abdominal changes.

INTERPRETATION OF THE FINDINGS & FURTHER RECOMMENDATIONS

FNA of the pancreas would be ideal for further definition of inflammatory cell type and rule out neoplasia even though I do not suspect underlying neoplasia in this particular case. Outpatient treatment for pancreatitis is warranted as well as a hydrolyzed geriatric diet and 7-10 days of Enrofloxacin and Metronidazole combination +/- pain management if pain is solicited upon subxiphoid palpation. A recheck sonogram is recommended in 3-4 weeks to ensure adequate resolution.





The information and recommendations provided are based on the images presented by the referring veterinarian. No evaluation can be communicated regarding pathology that was not visible in the image/video clips provided.

Thank you for this referral. If the clinical or image interpretation does not parallel your findings or if I can be of any further assistance please contact me.

Eric Lindquist, DMV, DABVP, Cert. IVUSS, CEO of SonoPath.com
Eric.Lindquist@SonoPath.com