SonoPath
Clinical Sonography & Telecytology

EDUCATIONAL TELECONSULTATION SERVICES™

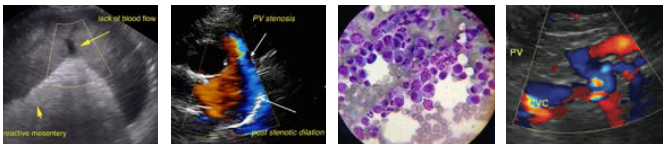

SonoPath.com™
1-800-838-4268 info@sonopath.com

PATIENT
Oreo Ng

SPECIES
Canine

BREED
Shih Tzu

SEX
Spayed Female

AGE
14 years

WEIGHT
13 lbs

INTERPRETED BY
Eric Lindquist, DMV DABVP, Cert. IVUSS

IMAGING PERFORMED BY
Kelly Vazquez , CVT

HOSPITAL NAME
Animal General on Hudson

REFERRING VET
Dr. Ng

INVOICE
96705

DATE
3/9/22

PRESENTING CLINICAL SIGNS

History: CRD, elevated liver enzymes, decreased appetite. Current meds: Denamarin, aluminum hydroxide.
Abnormal PE/Chem/CBC/UA Results: ALT 235, ALP 639, GGTP 18, BUN 124, creat. 4.2, phos 8.6, Ca 12.3, Mg 2.8, K 5.6, RBC 4.2, HCT 32, neutrophils 11616. UPC 1.5, urine culture neg.

ULTRASONOGRAPHIC EXAMINATION OF THE ABDOMEN

Urinary System

The **urinary bladder**, trigone, and pelvic urethra presented normal thicknesses and normal tone. The ureters were not visible which is normal. No uroliths or sediment were visualized and anechoic urine was present. No evidence of inflammatory or neoplastic changes was noted. Ureteral papillae were normal.

The **kidneys** were non-specific with mild to moderate, echogenic cortical remodeling. The right kidney measured 4.0 cm with an anechoic cyst at the dorsal cortex measuring 0.5 cm. The left kidney measured 3.5 cm. Vascularity to the kidneys appeared to be adequate.

Adrenal Glands

The **adrenal glands** appeared slightly enlarged and swollen. No evidence of focal capsular expansion or invasion into the phrenic veins was noted. No overt suspicion of neoplasia was noted. This is considered likely a hyperplastic change associated with stress or adrenal endocrinopathy (PDH). If isosthenuria is persistently present and the patient morphologically suggests Cushing's disease then ACTH testing would be indicated. The right adrenal gland measured 1.73 x 0.98 cm at the cranial pole and 0.62 cm at the caudal pole. The left adrenal gland measured 2.44 x 0.99 cm at the caudal pole and 1.02 cm at the cranial pole.

Spleen

The **spleen** presented a smooth homogeneous parenchyma hyperechoic to liver and renal cortical parenchyma. The capsule was smooth without noticeable expansion or deviation from within the spleen or adjacent pathology. The splenic vasculature demonstrated normal volume without signs of congestion or thrombosis. No sonographic evidence of acute or chronic inflammatory, neoplastic, or infarctual changes was noted.

Liver

The **liver** presented heterogenous parenchyma with increased portal markings and coarse architecture. Slight undulating capsular contour was noted. The gallbladder and common bile duct were unremarkable. This is consistent with chronic inflammatory hepatopathy. The gallbladder was mildly over distended with suspended and dependent debris, yet not to the level of emerging mucocele. However, the sludge appears to be mildly excessive. No adjunctive inflammation was noted.

SonoPath
Clinical Sonography & Telecytology

EDUCATIONAL TELECONSULTATION SERVICES™

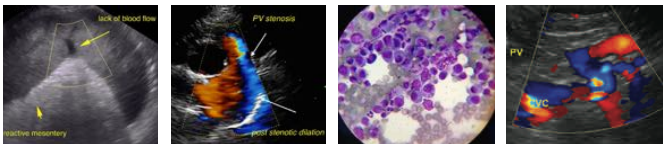

SonoPath.com™
1-800-838-4268 info@sonopath.com

PATIENT

Oreo Ng

SPECIES

Canine

BREED

Shih Tzu

SEX

Spayed Female

AGE

14 years

WEIGHT

13 lbs

INTERPRETED BY

Eric Lindquist, DMV
DABVP, Cert. IVUSS

IMAGING PERFORMED BY

Kelly Vazquez , CVT

HOSPITAL NAME

Animal General on Hudson

REFERRING VET

Dr. Ng

INVOICE

96705

DATE

3/9/22

Gastrointestinal

The **stomach** was edematous with a mild amount of fluid accumulation. There was some retention of ingesta noted. The gastric wall measured 0.4 x 0.5 cm. There was no evidence of foreign bodies. There was no obvious ulcerative disease. However, microulcerative changes cannot be entirely ruled out. This is most consistent with gastritis. The intestines were intestine free of stasis with normal wall thickness, acceptable curvilinear mural detail, and peristaltic activity. Small and large intestine demonstrated normal luminal chyme and stool consistency respectively. No associated abnormal lymphatic activity was noted.

Pancreas

The base and limbs of the **pancreas** were observed to be largely isoechoic to surrounding omental fat. Pancreatic duct and capsular contour were acceptably normal and parenchyma respected normal curvilinear patterns. No overt evidence of active inflammatory or neoplastic disease was noted.

ULTRASONOGRAPHIC FINDINGS

Bilateral adrenal hypertrophy. Potential underlying Cushing's. This is not the immediate issue.

Acute on mild chronic renal failure assuming isosthenuria is present.

Concurrent gastritis, likely uremia induced.

Non-specific chronic inflammatory hepatopathy. Gallbladder debris.

INTERPRETATION OF THE FINDINGS & FURTHER RECOMMENDATIONS

Leptospirosis titers are warranted as an underlying potential issue. 72 hour IV fluid protocol, IV Ampicillin, blood pressure measurements and GI protectants are all indicated with reassessment of the renal values. FNA of the liver can be considered for further definition. Ursodiol is warranted for long term management over the next 6-8 weeks assuming the immediate azotemia crisis can be resolved

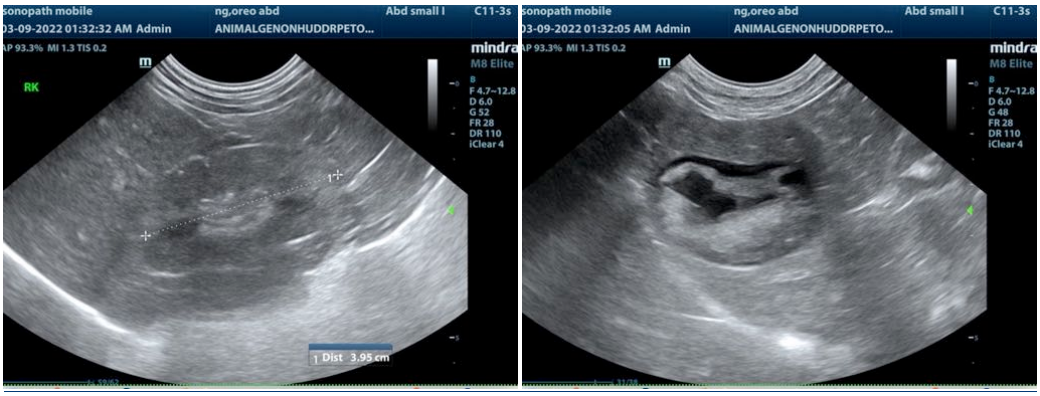

SonoPath

Clinical Sonography & Telecytology

EDUCATIONAL TELECONSULTATION SERVICES™

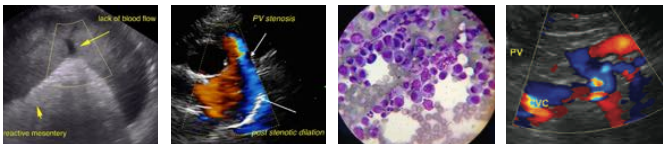

SonoPath.com™

1-800-838-4268 info@sonopath.com

PATIENT

Oreo Ng

SPECIES

Canine

BREED

Shih Tzu

SEX

Spayed Female

AGE

14 years

WEIGHT

13 lbs

INTERPRETED BY

Eric Lindquist, DMV
DABVP, Cert. IVUSS

IMAGING PERFORMED BY

Kelly Vazquez , CVT

HOSPITAL NAME

Animal General on Hudson

REFERRING VET

Dr. Ng

INVOICE

96705

DATE

3/9/22

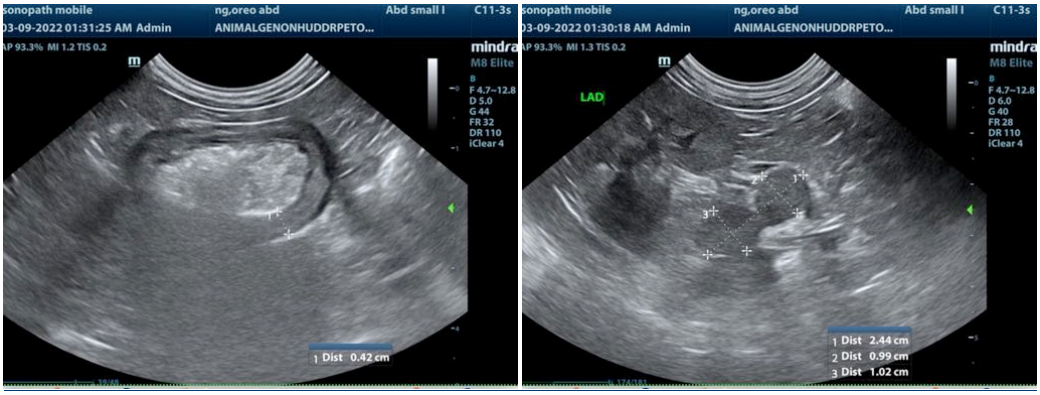

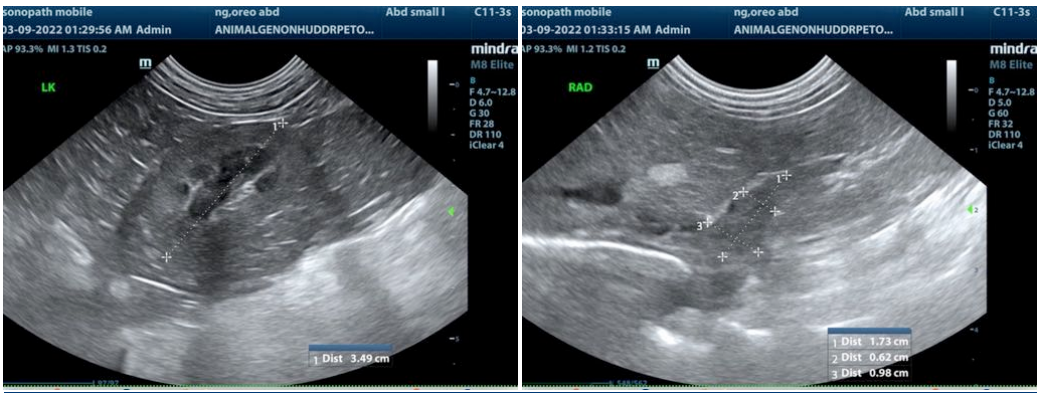

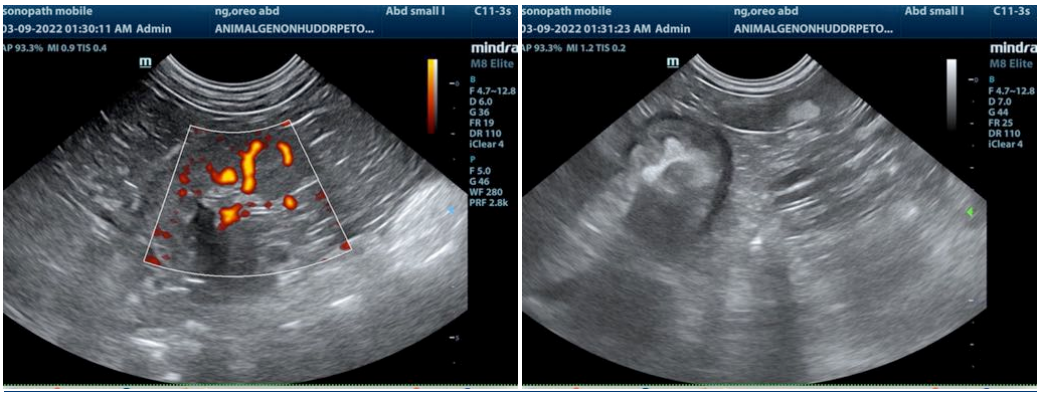

The information and recommendations provided are based on the images presented by the referring veterinarian/sonographer. No evaluation can be communicated regarding pathology that was not visible in the image/video clips provided.

Thank you for this referral. If the clinical or image interpretation does not parallel your findings or if I can be of any further assistance please contact me.

Eric Lindquist, DMV, DABVP, Cert. IVUSS, CEO of SonoPath.com

SonoPath
Clinical Sonography & Telecytology

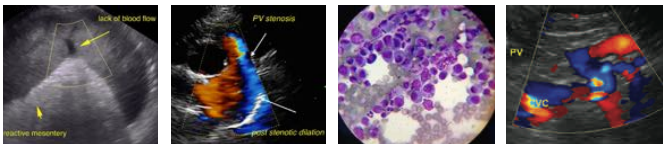

EDUCATIONAL TELECONSULTATION SERVICES™

SonoPath.com
1-800-838-4268 info@sonopath.com

PATIENT

Oreo Ng

info@SonoPath.com

SPECIES

Canine

BREED

Shih Tzu

SEX

Spayed Female

AGE

14 years

WEIGHT

13 lbs

INTERPRETED BY

Eric Lindquist, DMV
DABVP, Cert. IVUSS

IMAGING PERFORMED BY

Kelly Vazquez , CVT

HOSPITAL NAME

Animal General on Hudson

REFERRING VET

Dr. Ng

INVOICE

96705

DATE

3/9/22